

Injuries to the Genitourinary Tract

*About 10% of all injuries seen in the emergency room involve the genitourinary system to some extent.

*Initial assessment should include control of hemorrhage and shock along with resuscitation as required.

*Resuscitation may require intravenous lines and a urethral catheter in seriously injured patients.

- In men, before the catheter is inserted, the urethral meatus should be examined carefully for the presence of blood.
- The abdomen and genitalia should be examined for evidence of contusions or subcutaneous hematomas.
- Fractures of the lower ribs are often associated with renal injuries, and pelvic fractures often accompany bladder and urethral injuries.

INJURIES TO THE KIDNEY

- Renal injuries are the most common injuries of the urinary system.
- The kidney is well protected by heavy lumbar muscles, vertebral bodies, ribs, and the viscera anteriorly.
- Most injuries occur from automobile accidents or sporting mishaps, chiefly in men and boys.

Etiology

- Blunt trauma directly to the abdomen, flank, or back is the most common mechanism, accounting for 80–85% of all renal injuries.
- Gunshot and knife wounds cause most penetrating injuries to the kidney; any such wound in the flank area should be regarded as a cause of renal injury until proved otherwise.
- Associated abdominal visceral injuries are present in 80% of renal penetrating wounds.

Pathology & Classification

- **A.EARLY PATHOLOGIC FINDINGS:**

Lacerations from blunt trauma usually occur in the transverse plane of the kidney. The mechanism of injury is thought to be force transmitted from the center of the impact to the renal parenchyma.

- In injuries from rapid deceleration, the kidney moves upward or downward, causing sudden stretch on the renal pedicle and sometimes complete or partial avulsion.

- Pathologic classification of renal injuries is as follows:

Grade I—microscopic or gross hematuria; normal findings on radiographic studies; contusion or contained subcapsular hematoma without parenchymal laceration.

Grade II—nonexpanding, confined perirenal hematoma or cortical laceration less than 1 cm deep without urinary extravasation.

Grade III—parenchymal laceration extending more than 1 cm into the cortex without urinary extravasation.

- Grade IV**—parenchymal laceration extending through the corticomedullary junction and into the collecting system. Main renal artery or vein injury with contained hemorrhage.
- **Grade V**—completely shattered kidney or avulsion of renal hilum and devascularizing the kidney.

- **B. LATE PATHOLOGIC FINDINGS:**

- 1. Urinoma.**
- 2. Hydronephrosis.**
- 3. Arteriovenous fistula.**
- 4. Renal vascular hypertension.**

Clinical Findings & Indications for Studies

- Microscopic or gross hematuria following trauma to the abdomen indicates injury to the urinary tract.
- The degree of renal injury does not correspond to the degree of hematuria, since gross hematuria may occur in minor renal trauma and only mild hematuria in major trauma.
- However, not all adult patients sustaining blunt trauma require full imaging evaluation of the kidney.

INDICATIONS FOR RENAL IMAGING

- 1-All blunt trauma patients with gross hematuria.
- 2-Microscopic hematuria with shock(systolic BP less than 90mmhg any time during evaluation & resuscitation).
- 3-Penetrating injuries with any degree of hematuria.
- 4-Hematuria in pediatric patients(younger than 18) due to sustaining blunt renal trauma.

- **Symptoms:** Pain may be localized to one flank area or over the abdomen.
- Retroperitoneal bleeding may cause abdominal distention, ileus, nausea and vomiting.
- **Sings:** Initially, shock or signs of a large loss of blood from heavy retroperitoneal bleeding may be noted.
- Ecchymosis in the flank or upper quadrants of the abdomen.

- Diffuse abdominal tenderness may be found on palpation; an “acute abdomen” usually indicates free blood in the peritoneal cavity.
- A palpable mass may represent a large retroperitoneal hematoma or perhaps urinary extravasation.
- The abdomen may be distended and bowel sounds absent.

- **LABORATORY FINDINGS:**
- Microscopic or gross hematuria is usually present.
- The hematocrit may be normal initially, but a drop may be found when serial studies are done.
- This finding represents persistent retroperitoneal bleeding and development of a large retroperitoneal hematoma.

STAGING AND X-RAY FINDINGS

- Staging begins with an abdominal CT scan, the most direct and effective means of staging renal injuries.
- This noninvasive technique clearly defines parenchymal lacerations and urinary extravasation, shows the extent of the retroperitoneal hematoma, identifies nonviable tissue, and outlines injuries to surrounding organs such as the pancreas, spleen, liver, and bowel.

- If CT is not available, an intravenous pyelogram can be obtained.
- Arteriography defines major arterial and parenchymal injuries when previous studies have not fully done.
- Arterial thrombosis and avulsion of the renal pedicle are best diagnosed by arteriography and are likely when the kidney is not visualized on imaging studies.

- The major causes of nonvisualization on an excretory urogram are total pedicle avulsion, arterial thrombosis, severe contusion causing vascular spasm, and absence of the kidney (either congenital or from operation).
- Radionuclide renal scans have been used in staging renal trauma. However, in emergency management, this technique is less sensitive than arteriography or CT.

LATE COMPLICATIONS

- 1-Hypertension.
- 2-hydronephrosis.
- 3-arteriovenous fistula.
- 4-calculus formation.
- 5-pyelonephritis.
- Careful monitoring of blood pressure for several months is necessary to watch for hypertension.

- At 3–6 months, a follow-up excretory urogram or CT scan should be obtained to be certain that perinephric scarring has not caused hydronephrosis or vascular compromise; renal atrophy may occur from vascular compromise and is detected by follow-up urography.
- Heavy late bleeding may occur 1–4 weeks after injury.

TREATMENT

A. EMERGENCY MEASURES:

- Treatment of shock and hemorrhage, complete resuscitation, and evaluation of associated injuries.

B. SURGICAL MEASURES:

- **1. Blunt injuries:injuries—Minor renal injuries from blunt** trauma account for 85% of cases and do not usually require operation.

- Bleeding stops spontaneously with bed rest and hydration.
- Grade IV&V injuries more often require surgical exploration, but even these high grade injuries can be managed without renal operation if carefully staged & selected.
- Aggressive preoperative staging allows complete definition of injury before operation.

OPERATIVE MANAGEMENT

- Absolute indications for renal exploration include:
 - 1-Evidence of persistent renal bleeding.
 - 2-Expanding perirenal hematoma.
 - 3-Pulsatile perirenal hematoma.
- Relative indications include:
 - 1-Urinary extravasation.
 - 2-Nonviable tissue.
 - 3-Delayed diagnosis of arterial injury or segmental arterial injury.
 - 4-Incomplete staging.

- **2. Penetrating injuries:** Penetrating injuries **should be** surgically explored. A rare exception to this rule is when staging has been complete and only minor parenchymal injury, with no urinary extravasation, is noted.
- In 80% of cases of penetrating injury, associated organ injury requires operation; thus, renal exploration is only an extension of this procedure.

C. TREATMENT OF COMPLICATIONS

- Retroperitoneal urinoma or perinephric abscess demand prompt surgical drainage. Malignant hypertension requires vascular repair or nephrectomy.
- Hydronephrosis may require surgical correction or nephrectomy.
- **Prognosis:** With careful follow-up, most renal injuries have an excellent prognosis, with spontaneous healing and return of renal function.

INJURIES TO THE URETER

- **Etiology:**

- 1-Large pelvic masses (benign or malignant) may displace the ureter laterally and engulf it in reactive fibrosis.
- 2-Inflammatory pelvic disorders may involve the ureter in a similar way.
- 3-Extensive carcinoma of the colon may invade areas outside the colon wall and directly involve the ureter.

- 4-Devascularization may occur with extensive pelvic lymph node dissections or after radiation therapy to the pelvis for pelvic cancer.
- 5-Endoscopic manipulation of a ureteral calculus with a stone basket or ureteroscope may result in ureteral perforation or avulsion.
- 6-Surgical injury:hysterectomy was responsible for majority of surgical ureteric injuries(54%).

- **Pathogenesis & Pathology:**

The ureter may be inadvertently ligated and cut during difficult pelvic surgery. In such cases, sepsis and severe renal damage usually occur postoperatively.

- If a partially divided ureter is unrecognized at operation, urinary subsequent buildup of a large urinoma will ensue, which usually leads to ureterovaginal or ureterocutaneous fistula formation.

- Intraperitoneal extravasation of urine can also occur, causing ileus and peritonitis.
- After partial transection of the ureter, some degree of stenosis and reactive fibrosis develops, with concomitant mild to moderate hydronephrosis.

GRADING OF URETERIC INJURY

- Grade I-contusion or hematoma without devascularization.
- Grade II-laceration(less than 50% transection).
- Grade III-laceration(more than 50% transection).
- Grade IV-laceration(complete transection with less than 2cm devascularization).
- Grade V-laceration(avulsion with more than 2cm devascularization).

Clinical Findings

- **A. SYMPTOMS:** If the ureter has been completely or partially ligated during operation, the postoperative course is usually marked by fever of 38.3°C–38.8°C (101°F–102°F) as well as flank and lower quadrant pain.
- Such patients often experience paralytic ileus with nausea and vomiting.
- Ureterovaginal or cutaneous fistula develops, it usually does so within the first 10 postoperative days.

- **B. SIGNS:**severe flank pain and abdominal pain with nausea and vomiting early in the postoperative course and with associated ileus.
- Signs and symptoms of acute peritonitis may be present if there is urinary extravasation into the peritoneal cavity.
- Watery discharge from the wound or vagina may be identified as urine by determining the creatinine concentration of a small sample.or by injection of indigo carmine I.V.

C. LABORATORY FINDINGS: Ureteral injury from external violence is manifested by microscopic hematuria in 90% of cases.

- **D. IMAGING FINDINGS:** Diagnosis is by excretory urography or delayed abdominal spiral CT scan. A plain film of the abdomen may demonstrate a large area of increased density in the pelvis or in an area of retroperitoneum where injury is suspected.

- In acute injury from external violence, the excretory urogram usually appears normal.
- Retrograde ureterography demonstrates the exact site of obstruction or extravasation.

E. ULTRASONOGRAPHY: Ultrasonography outlines hydroureter or urinary extravasation as it develops into a urinoma and is perhaps the best means of ruling out ureteral injury in the early postoperative period.

Differential Diagnosis:

- * Postoperative bowel obstruction and peritonitis.
- * Deep wound infection must be considered postoperatively in patients with fever, ileus, and localized tenderness.
- * Acute pyelonephritis in the early postoperative period may also result in findings similar to those of ureteral injury.

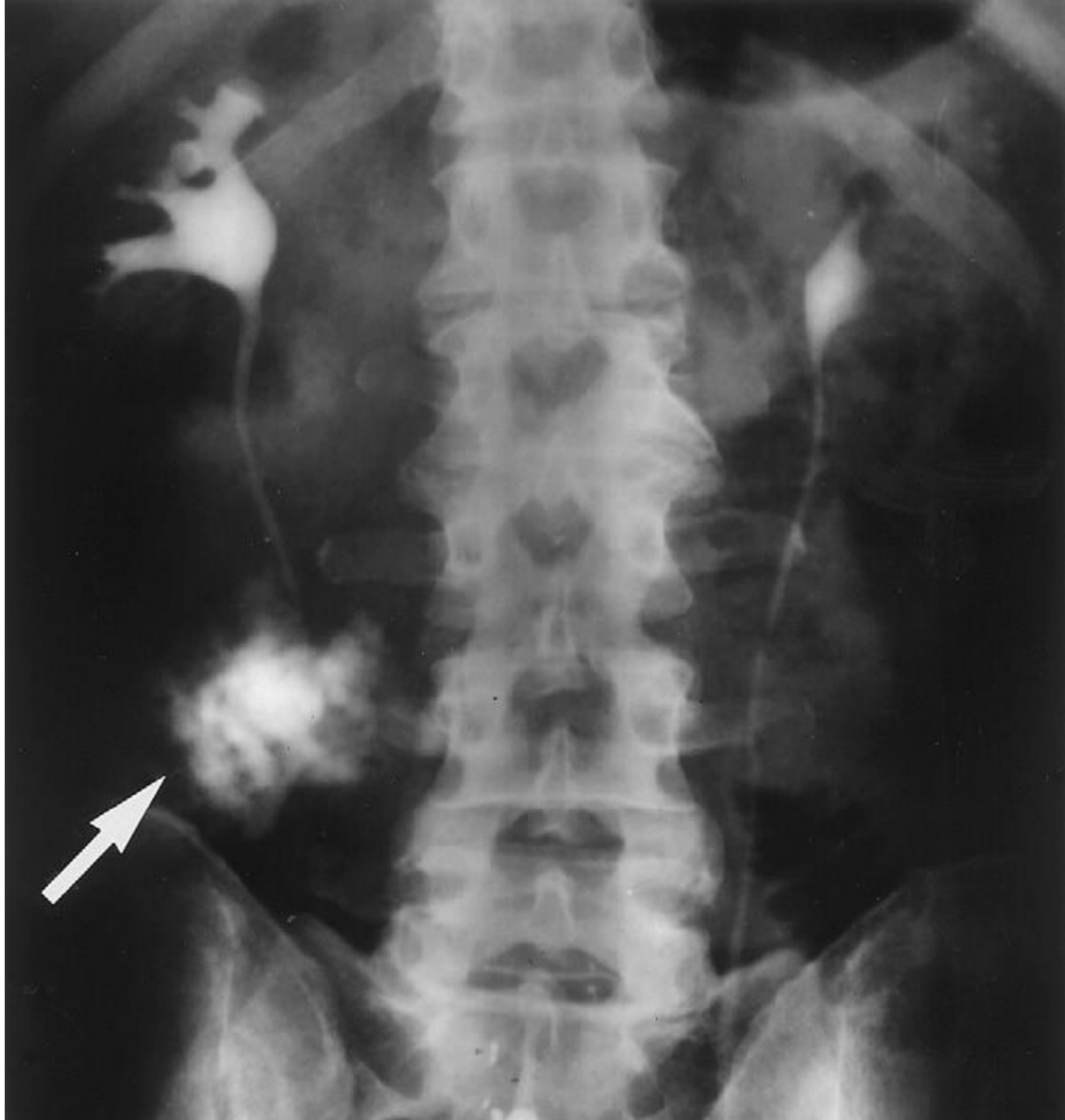
TREATMENT


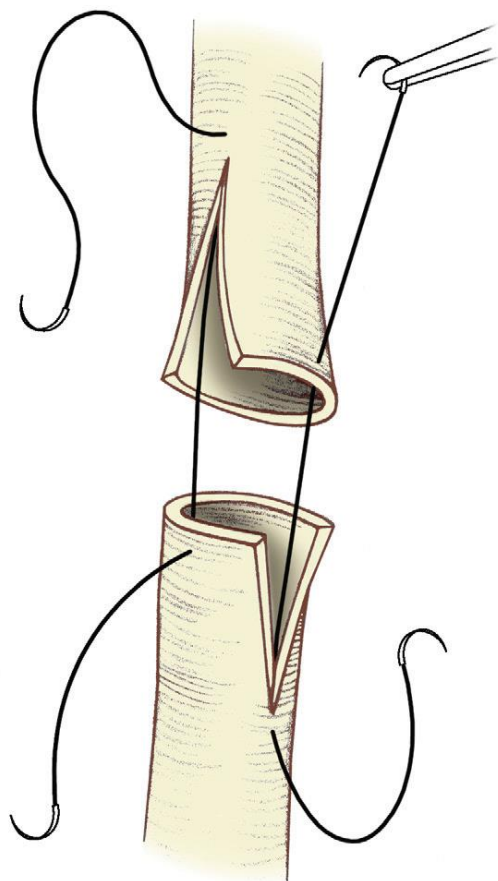
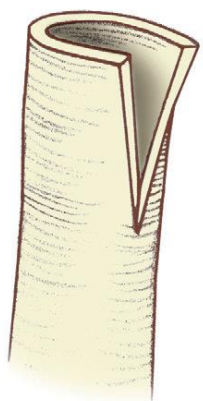

- The best opportunity for successful repair is in the operating room.
- If the injury is not recognized until 7–10 days after the event and no infection, abscess, or other complications exist, immediate reexploration and repair are indicated.
- Proximal urinary drainage by percutaneous nephrostomy or formal nephrostomy should be considered if the injury is recognized late or if the patient has significant complications that make immediate reconstruction unsatisfactory.

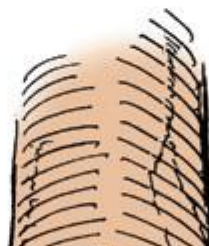
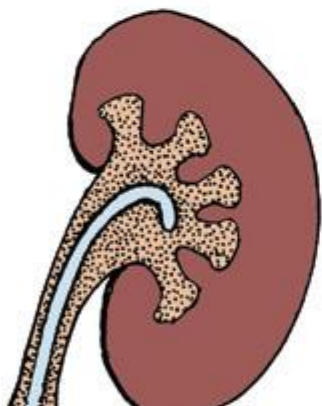
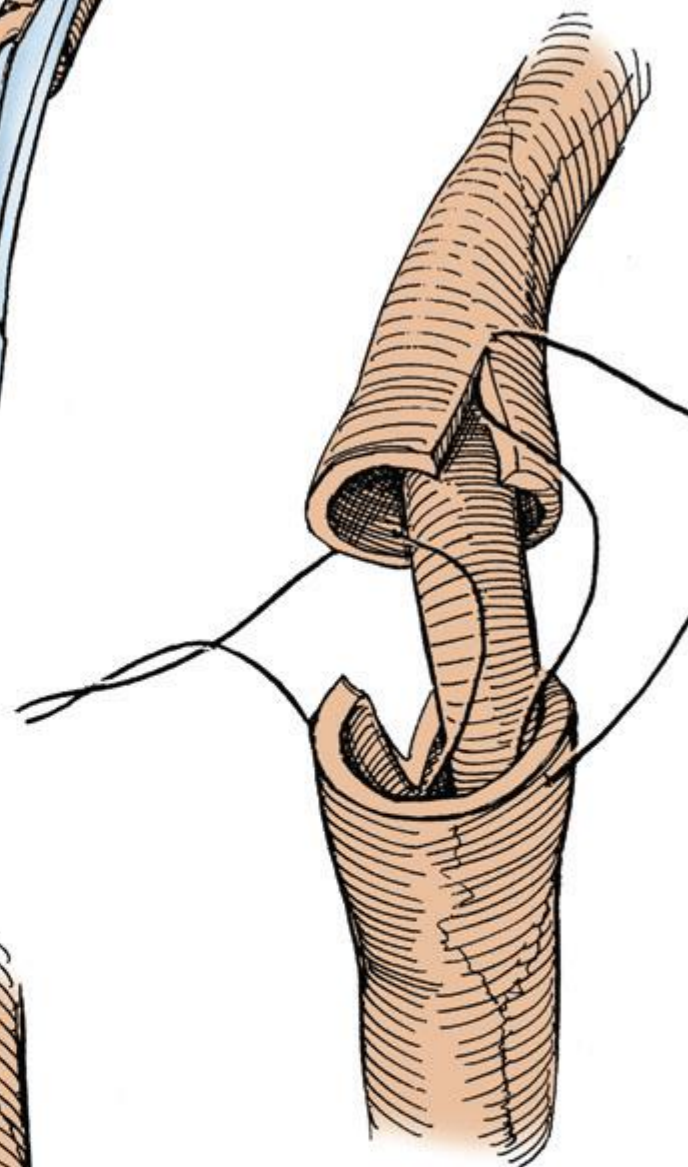
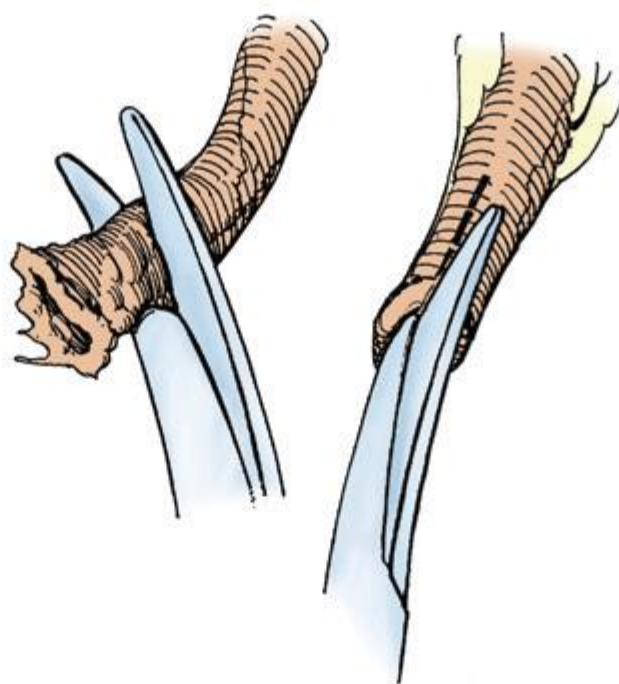
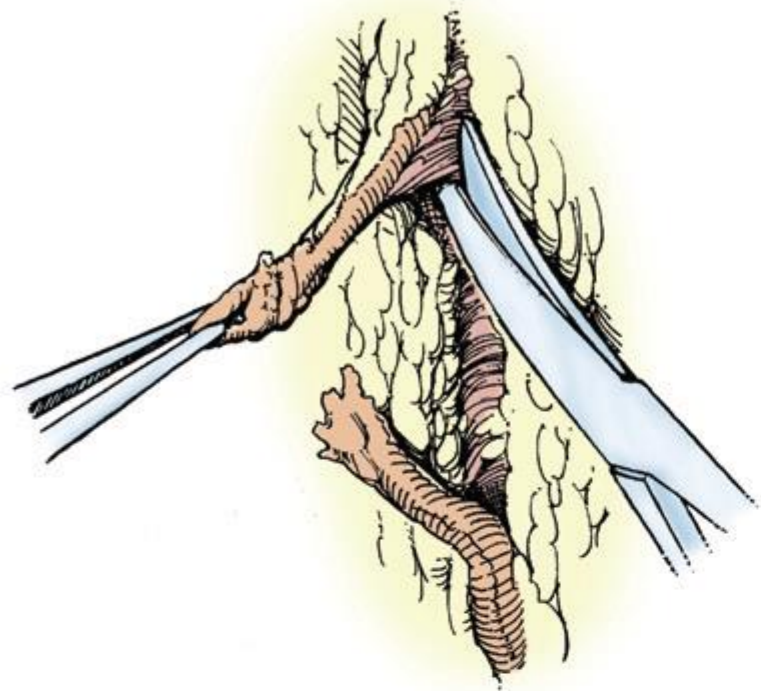
- The goals of ureteral repair are:
 - 1-Achieve complete debridement.
 - 2- Tension-free.
 - 3- Spatulated anastomosis, watertight closure, ureteral stenting (in selected cases).
 - 4- retroperitoneal drainage.
- *Ureteral contusion due to external trauma is treated by either internal stenting or ureteroureterostomy.

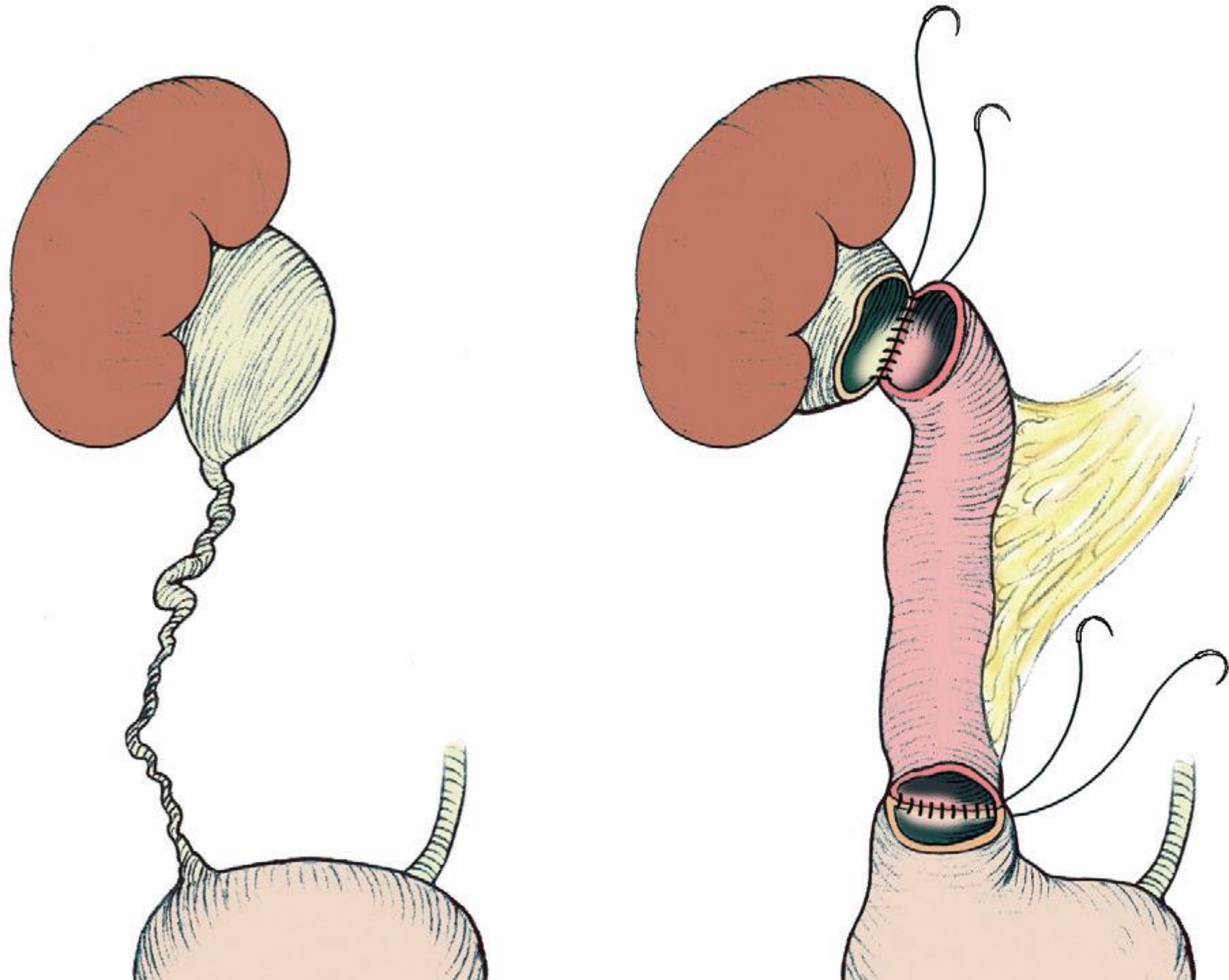
- UPPER URETERAL INJURIES:
 - 1-ureteroureterostomy.
 - 2-bowel replacement of the ureter.
 - 3-autotransplantation of the kidney.
- MIDURETERAL INJURIES:
 - 1-ureteroureterostomy.
 - 2-transureteroureterostomy.

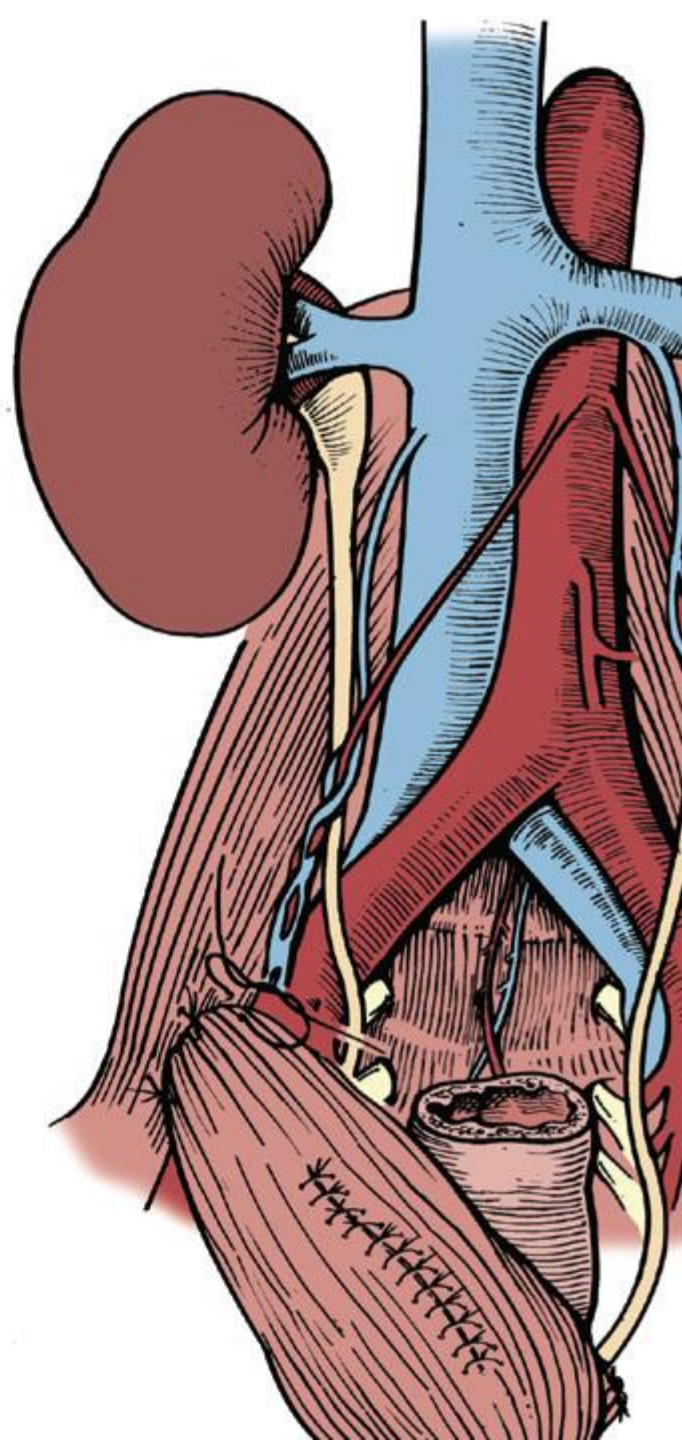
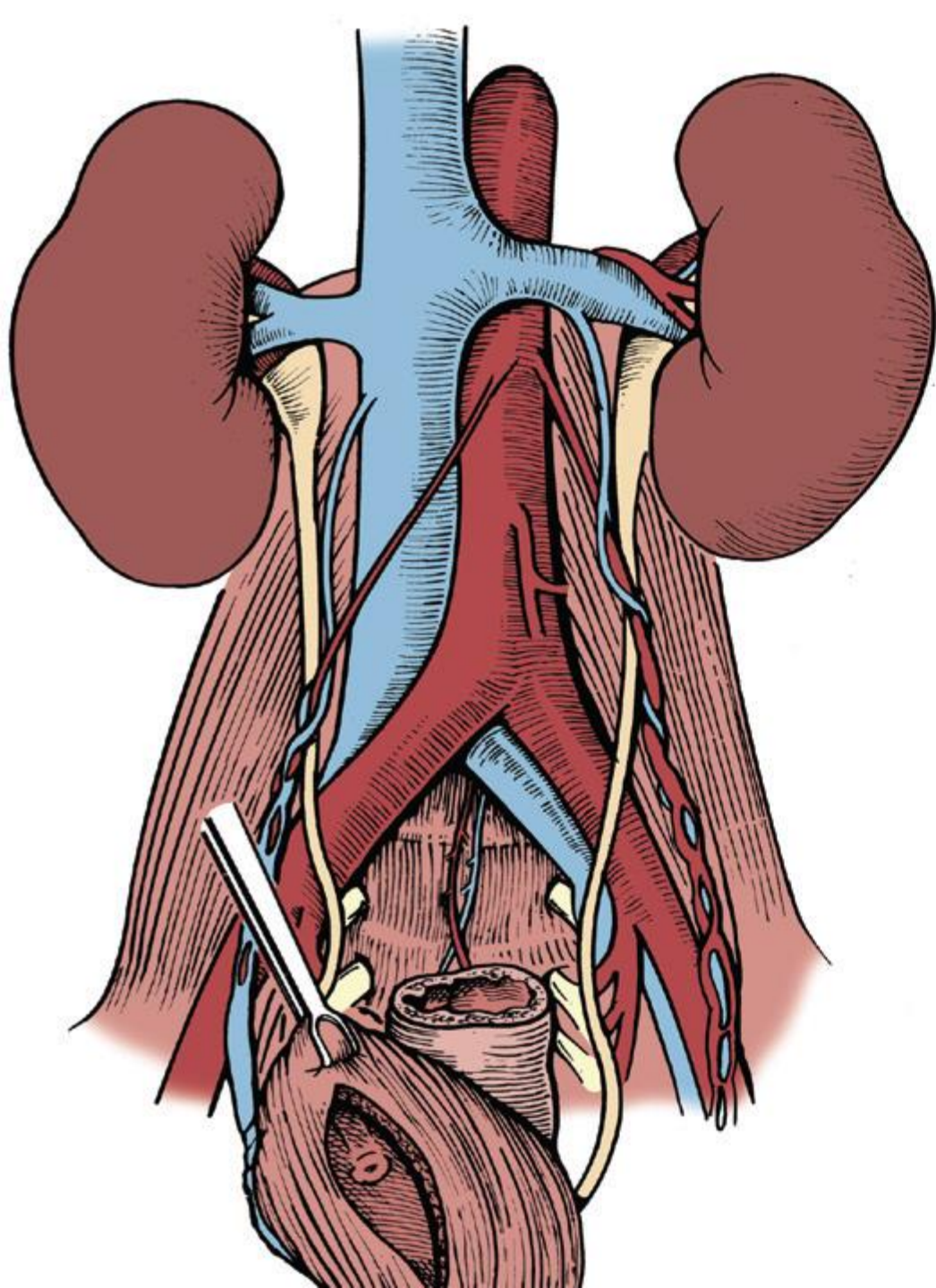
- LOWER URETERAL INJURIES:
- 1-Ureteroneocystostomy reimplantation into the bladder.
- 2. psoas bladder hitch or boari flap.
- 3-Transureteroureterostomy.
- The prognosis for ureteral injury is excellent if the diagnosis is made early and prompt corrective surgery is done.

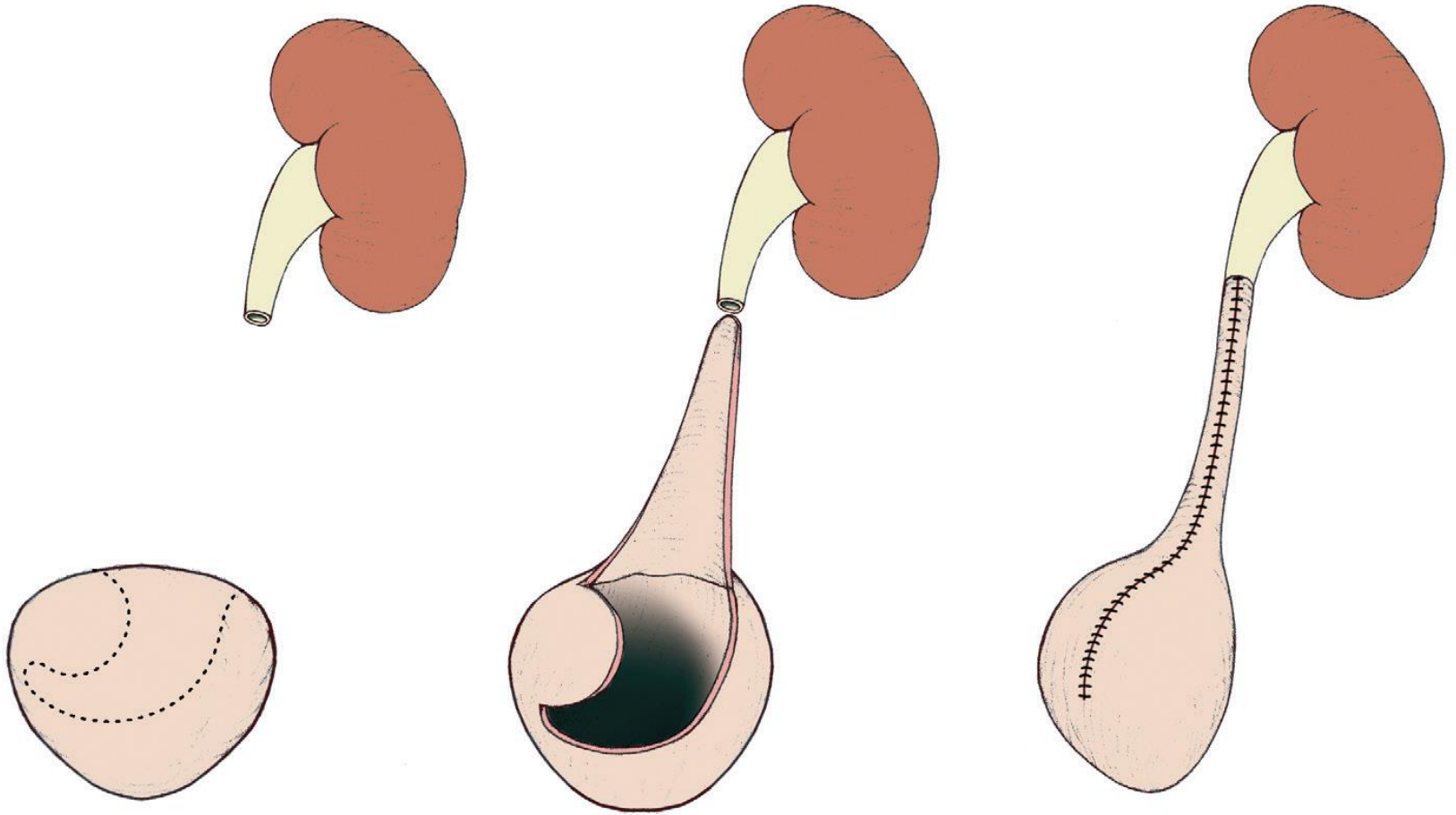


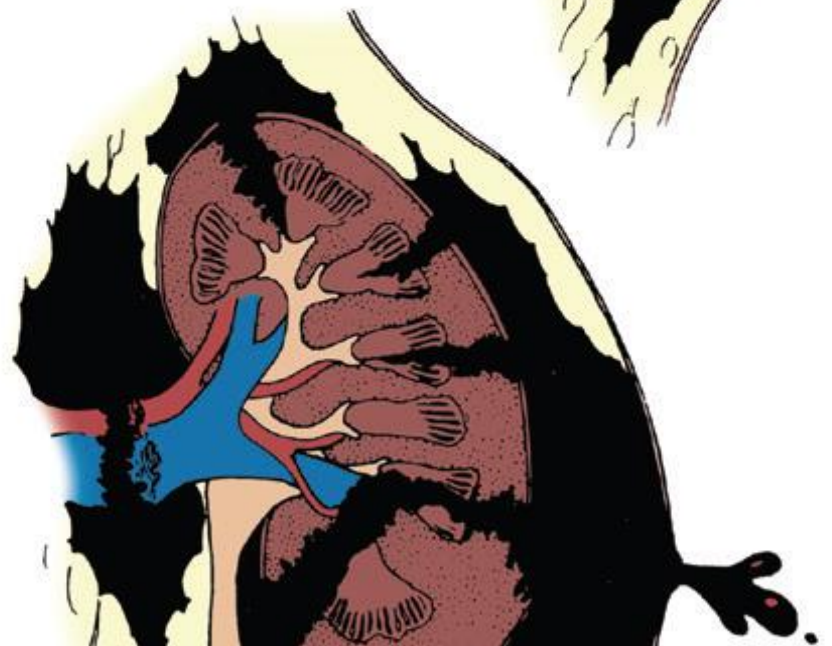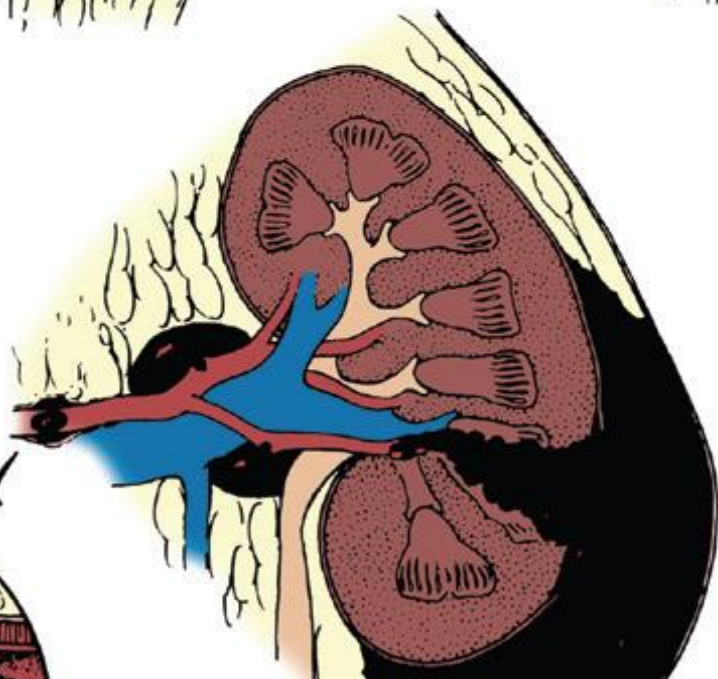
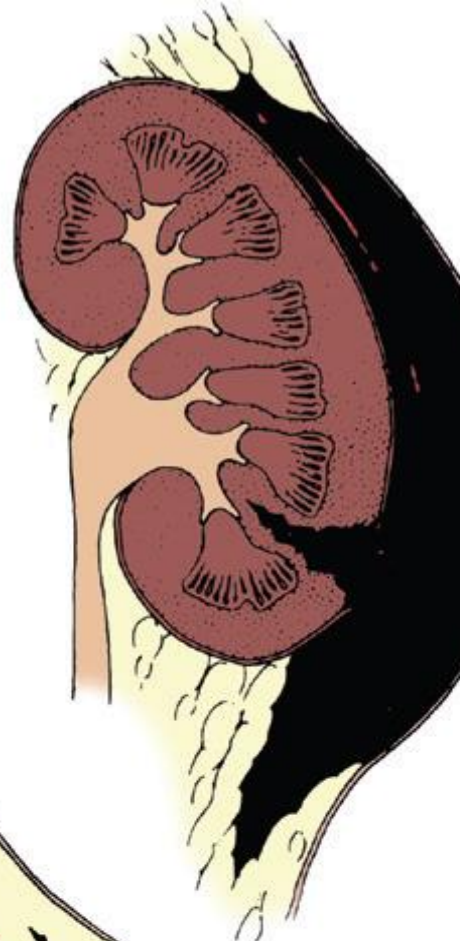
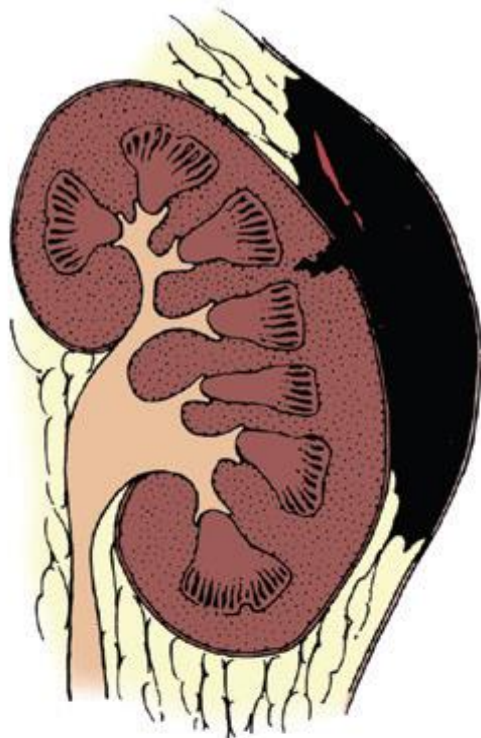
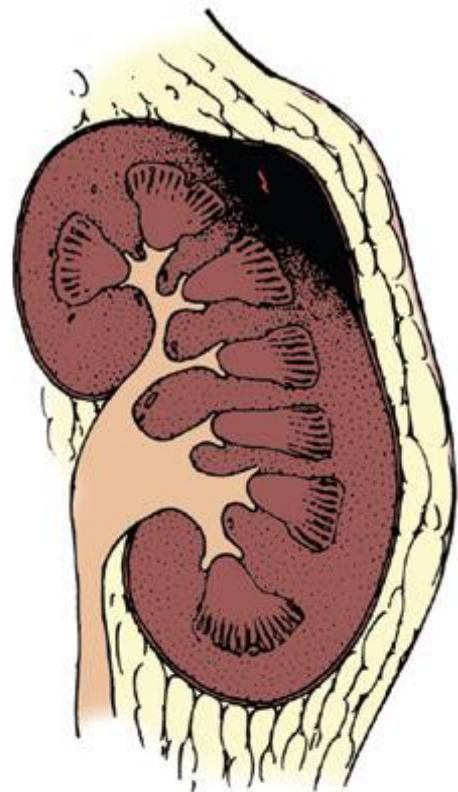








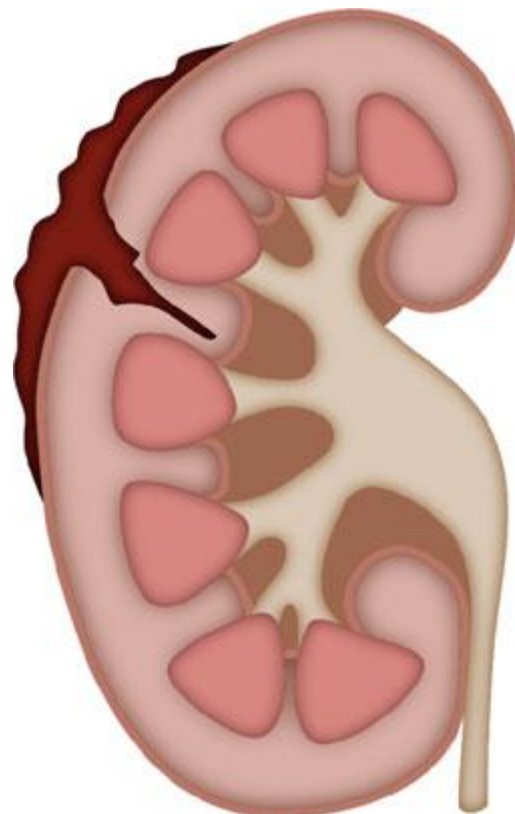
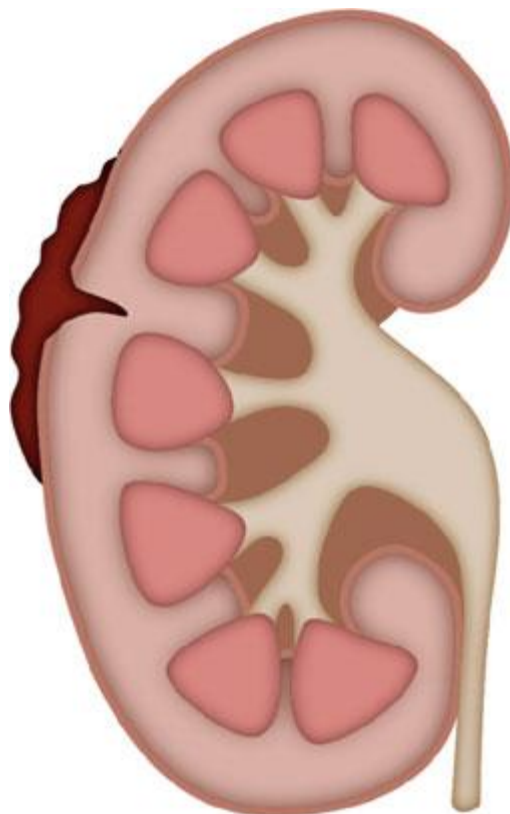
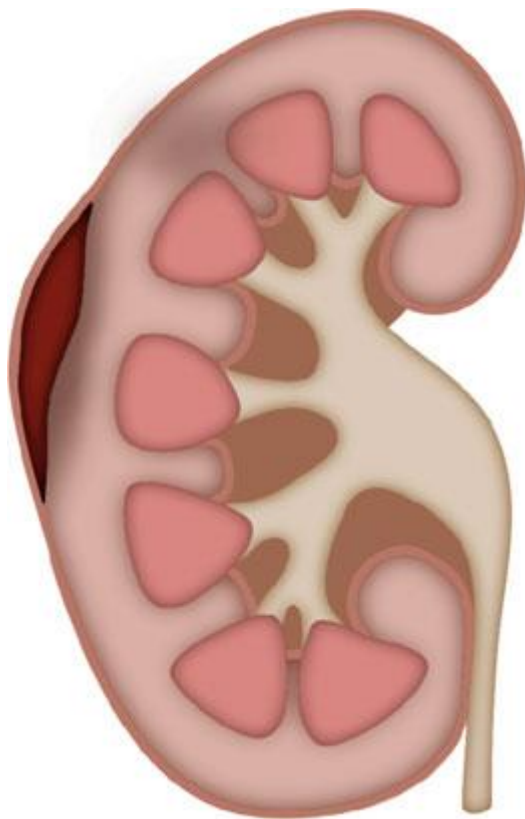




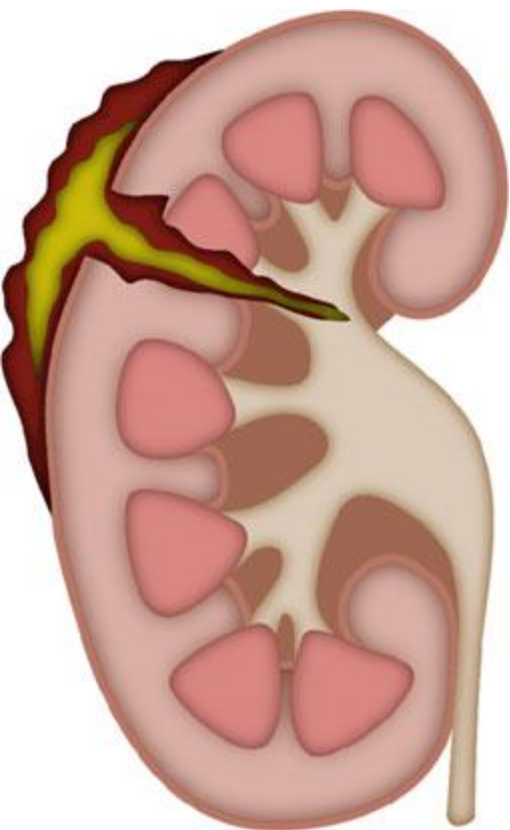
A

B

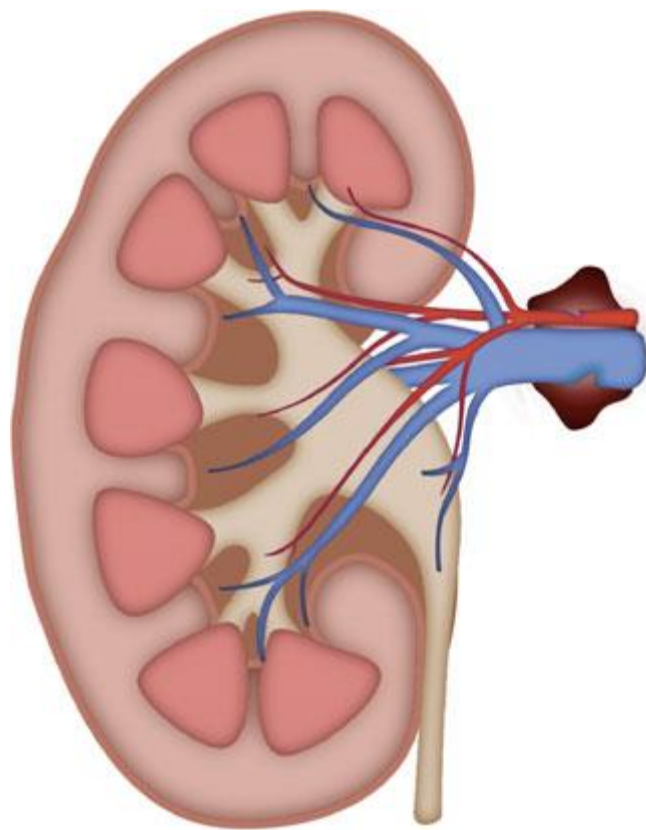
C



D



E



F

