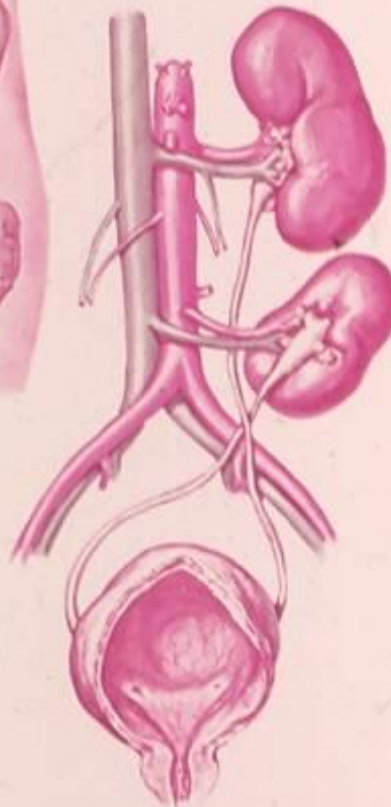

ECTOPIA OF THE KIDNEY

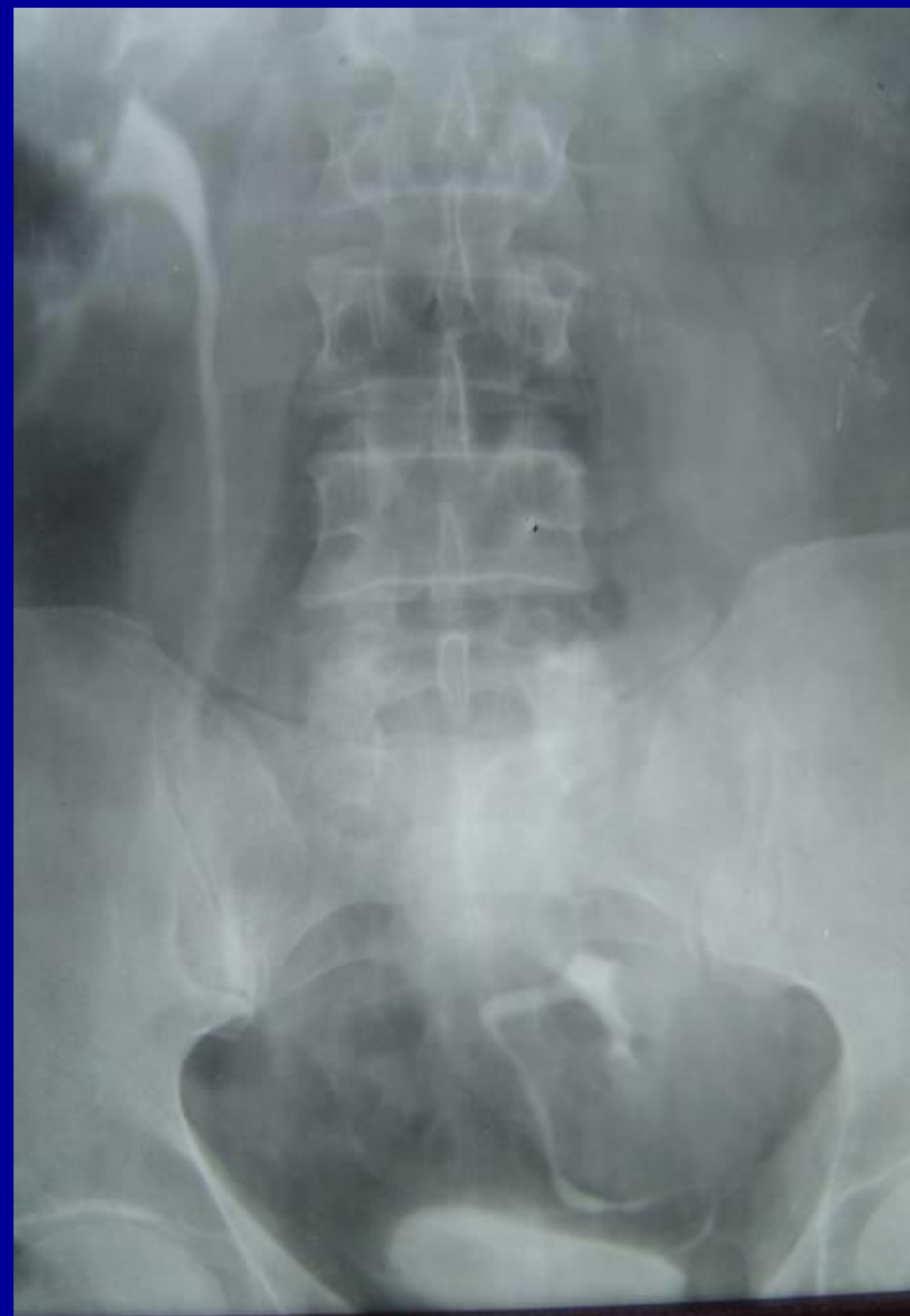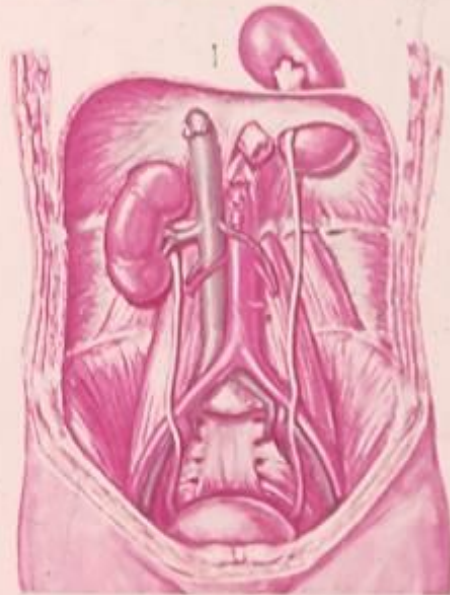
RIGHT PELVIC KIDNEY

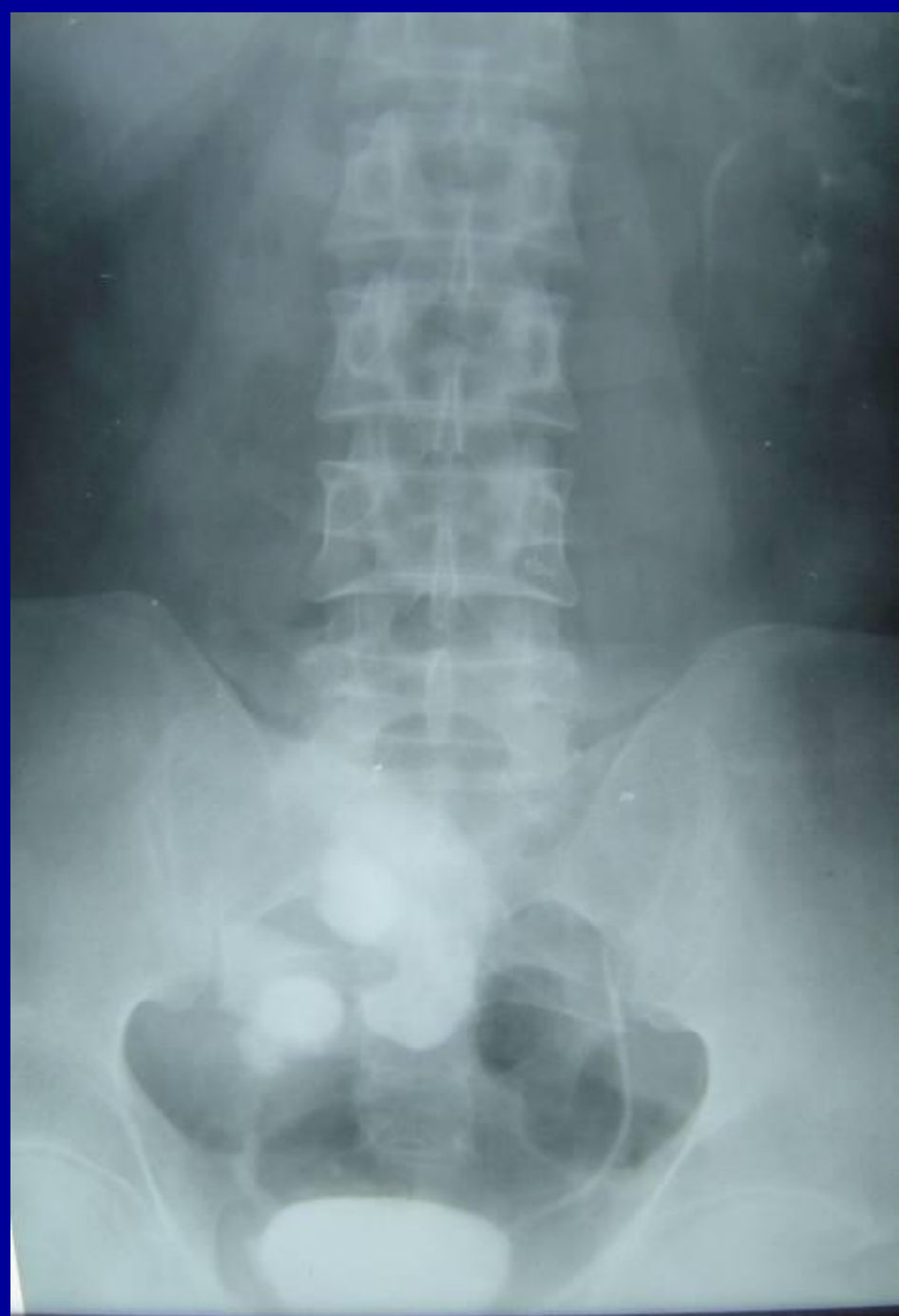
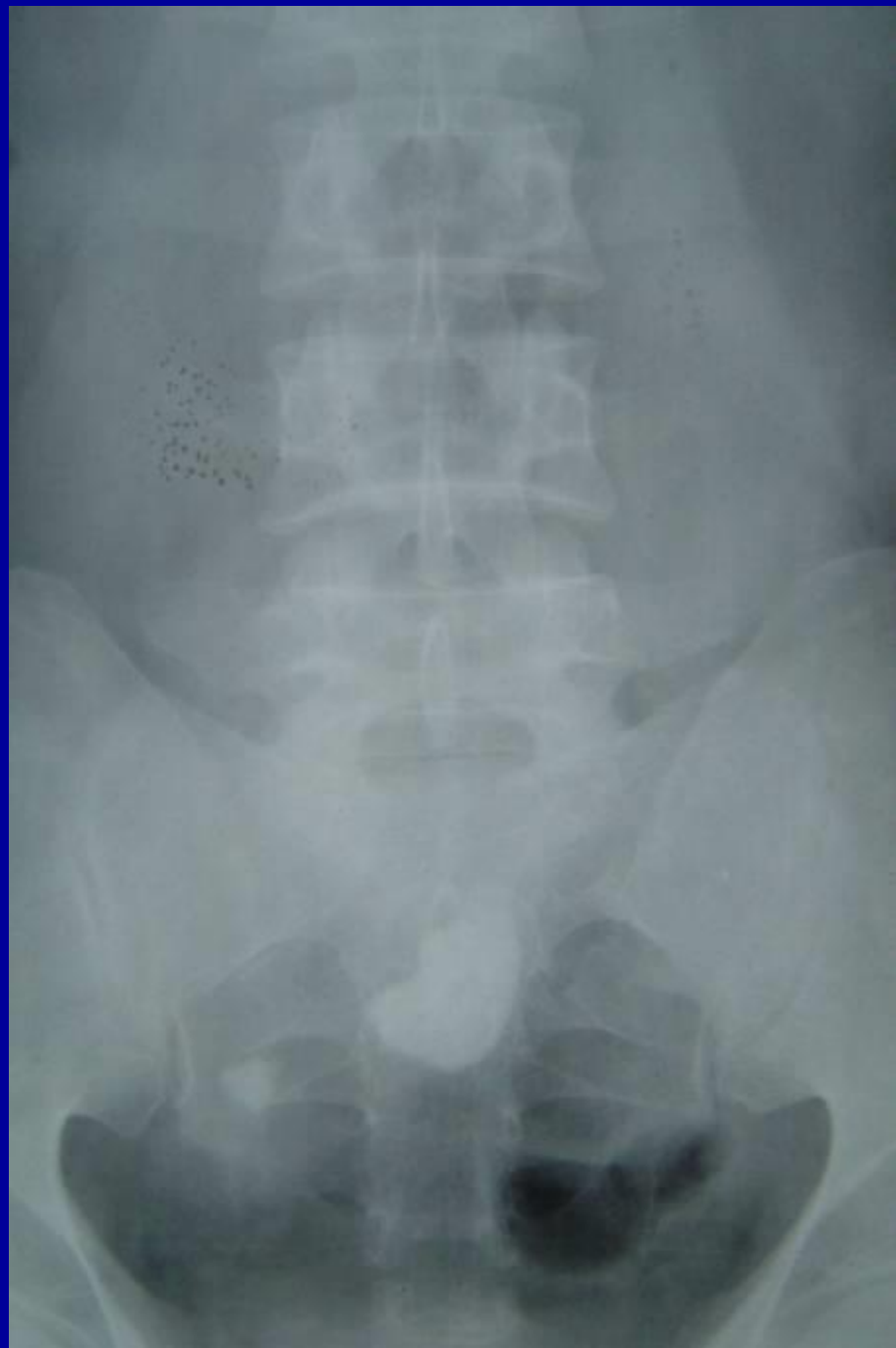
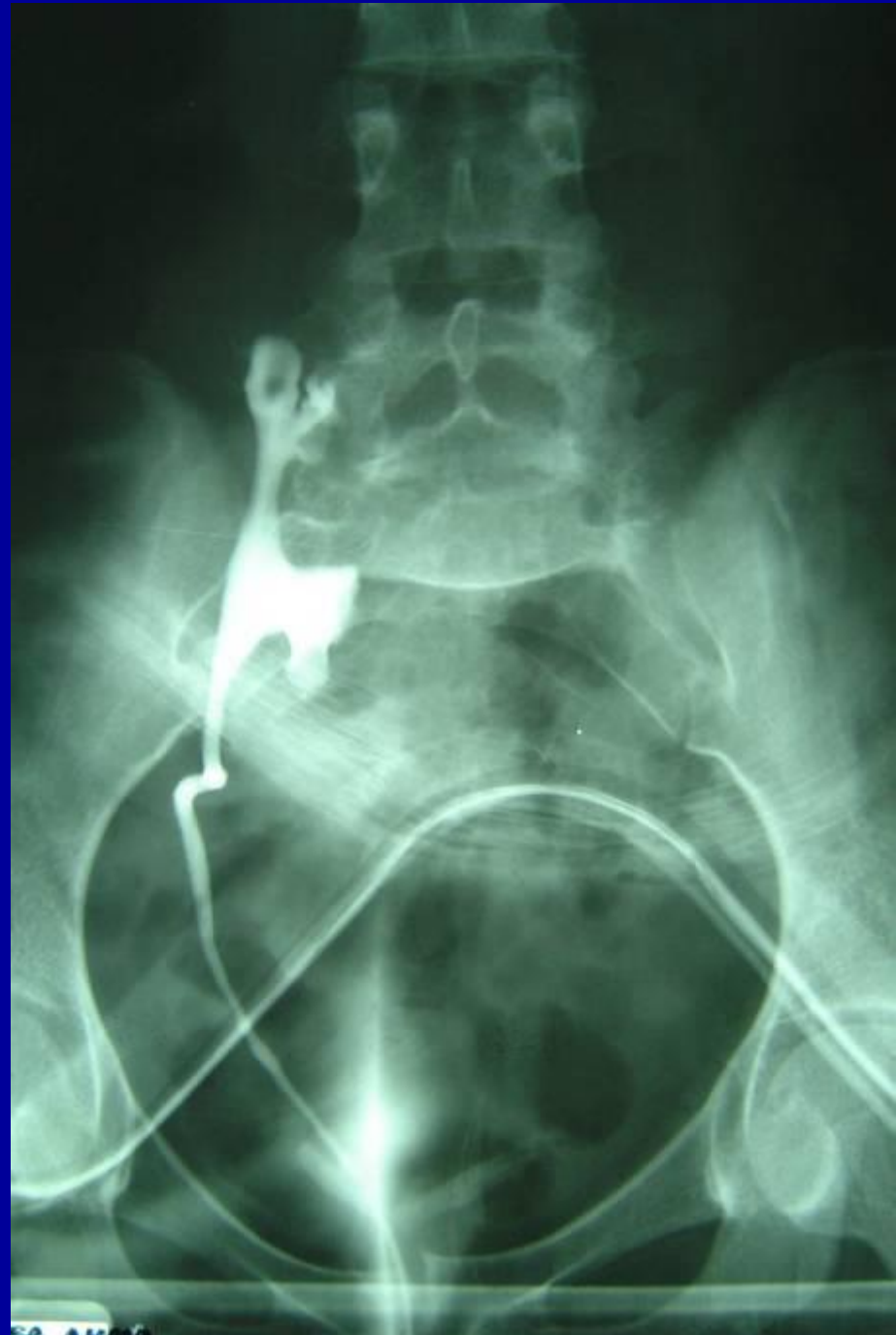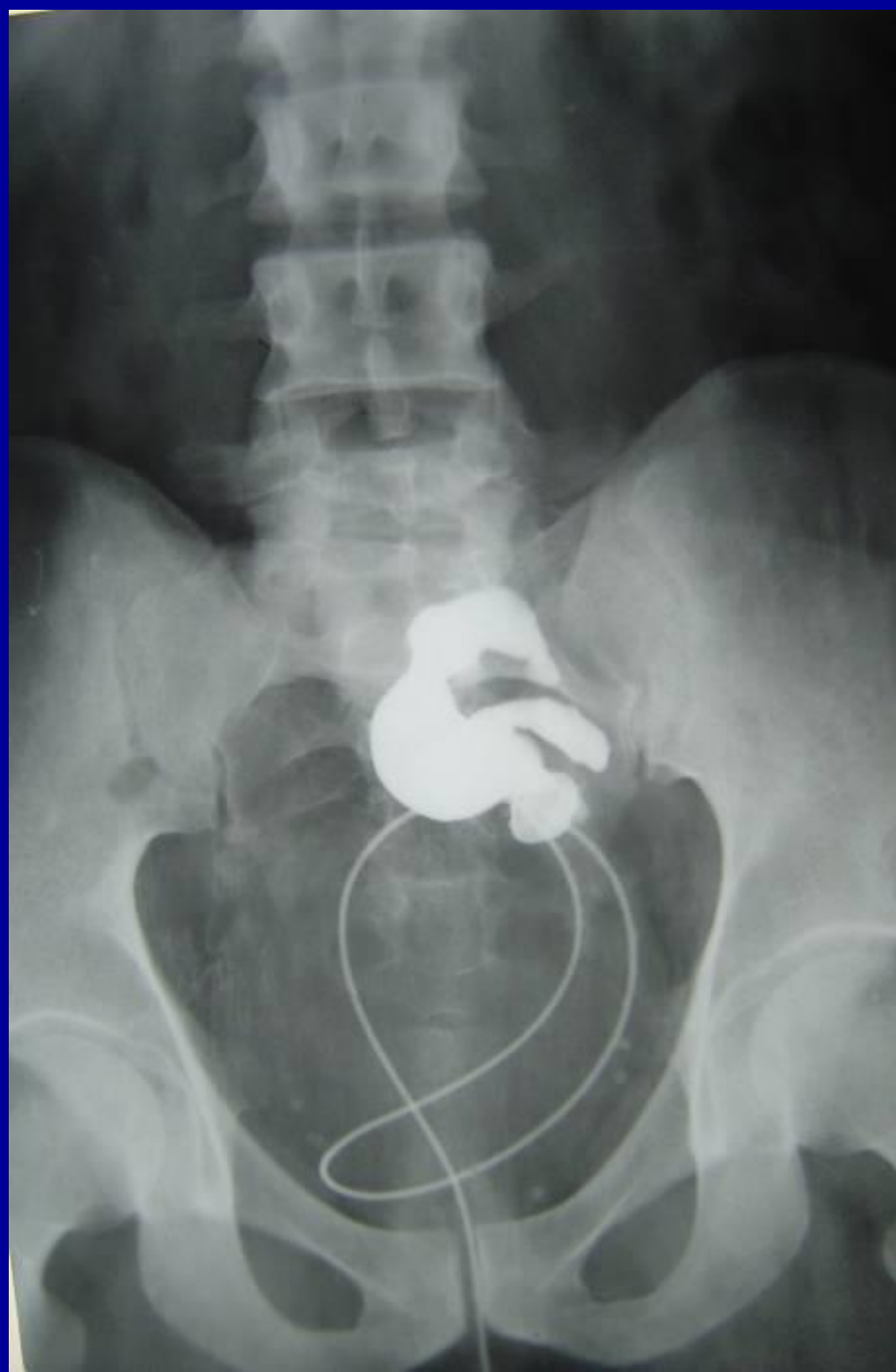CROSSED ECTOPIA OF THE RIGHT KIDNEY

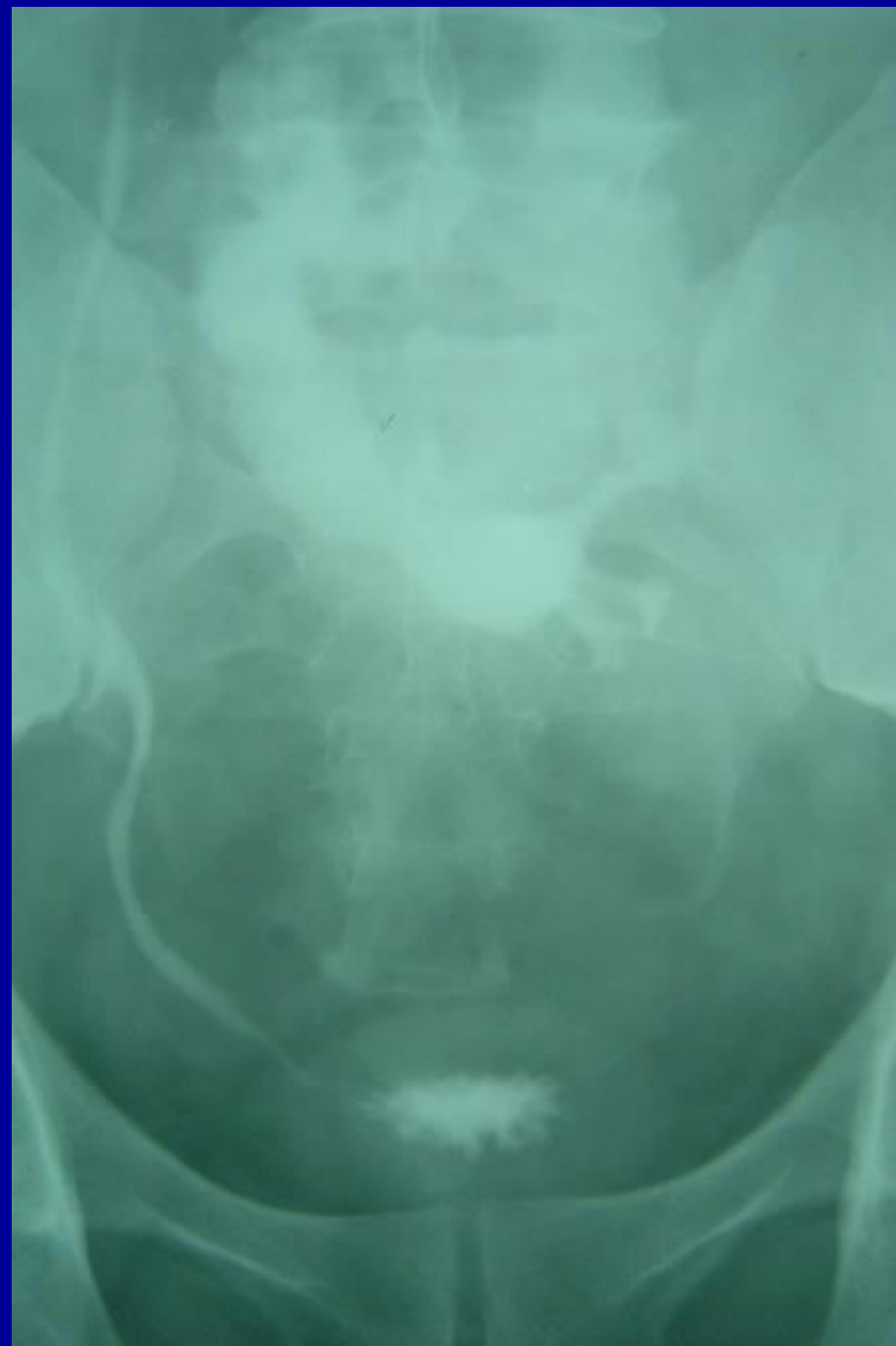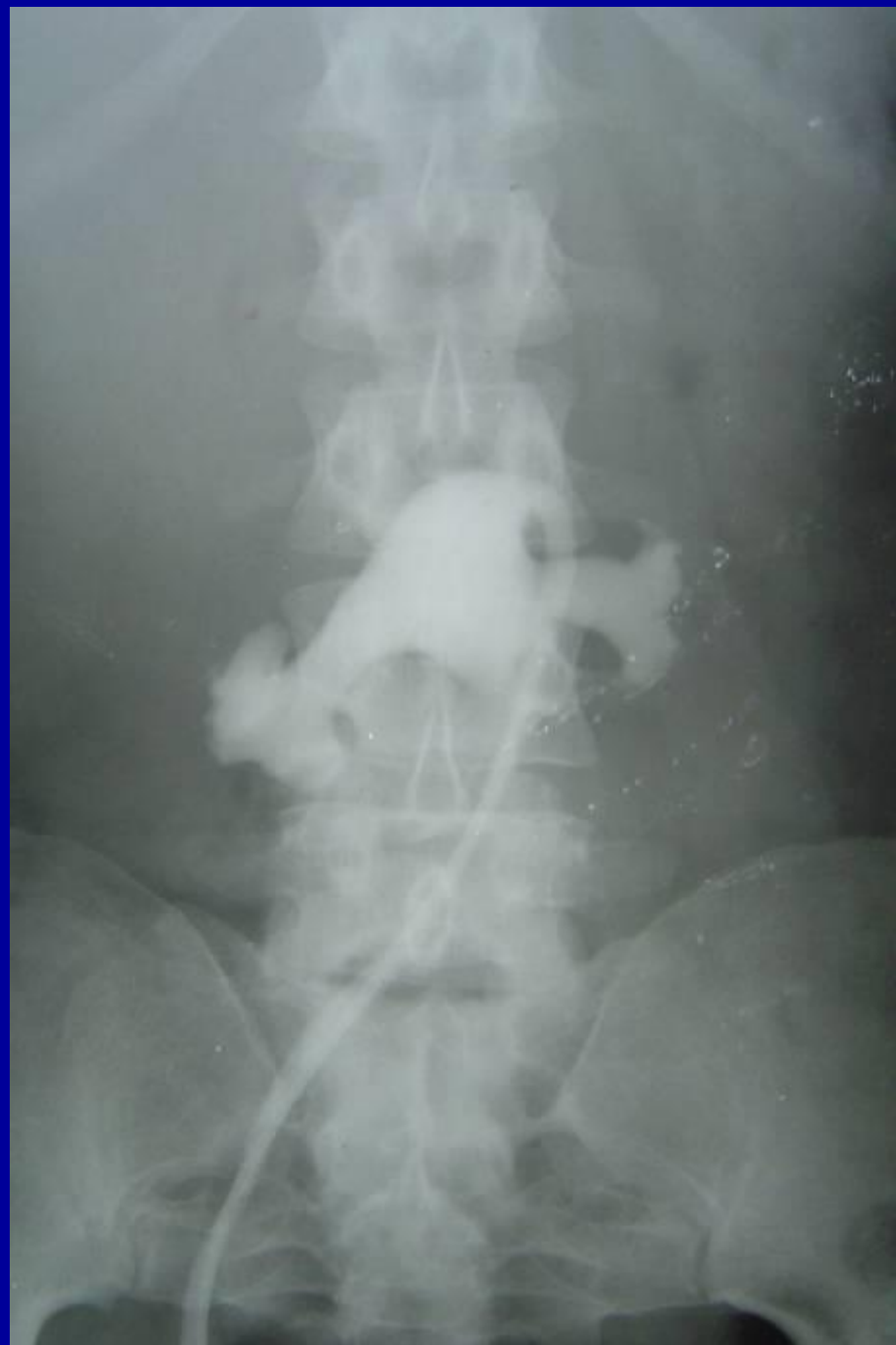*F. Netter M.D.*  
CIBA

THORACIC KIDNEY

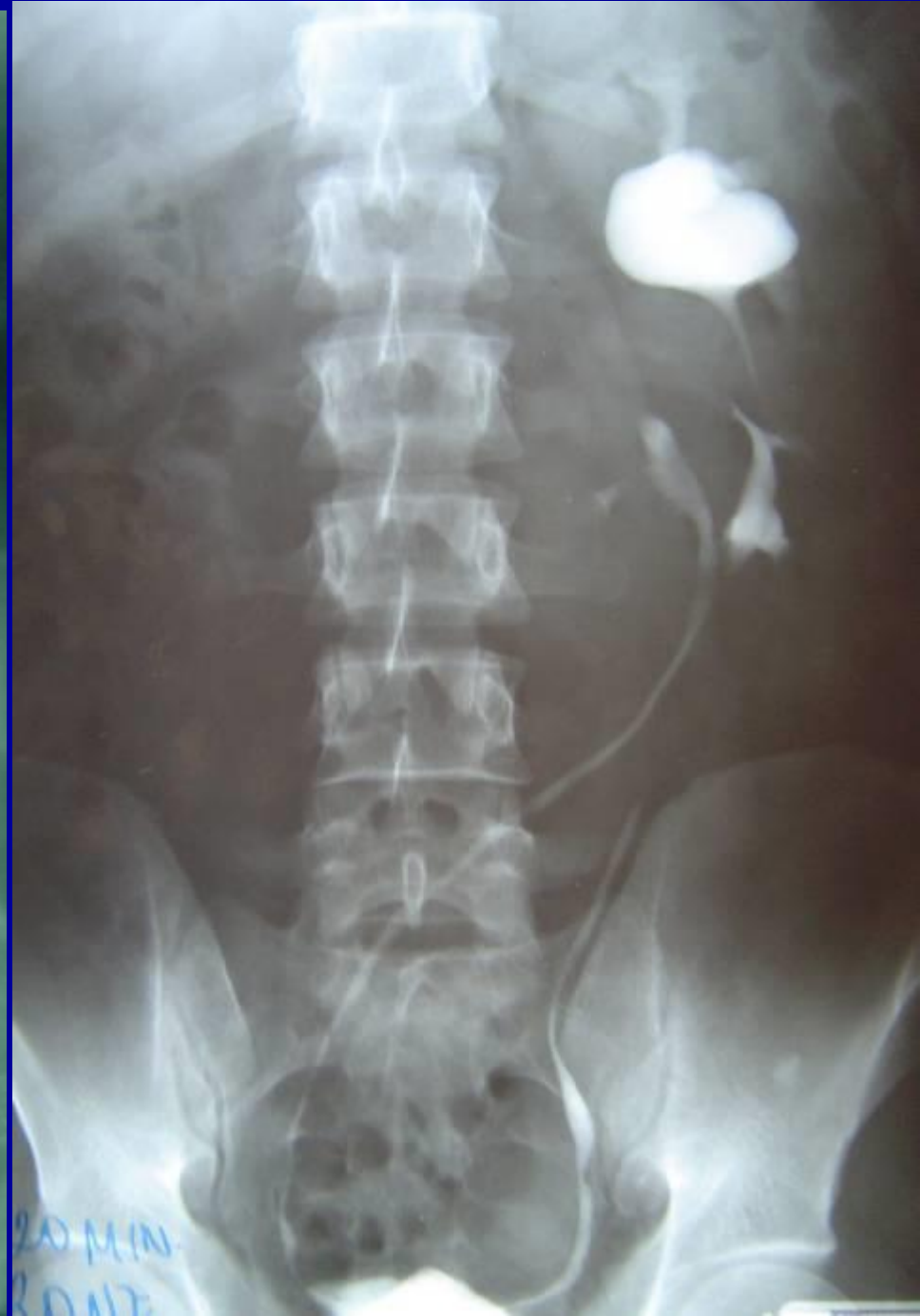
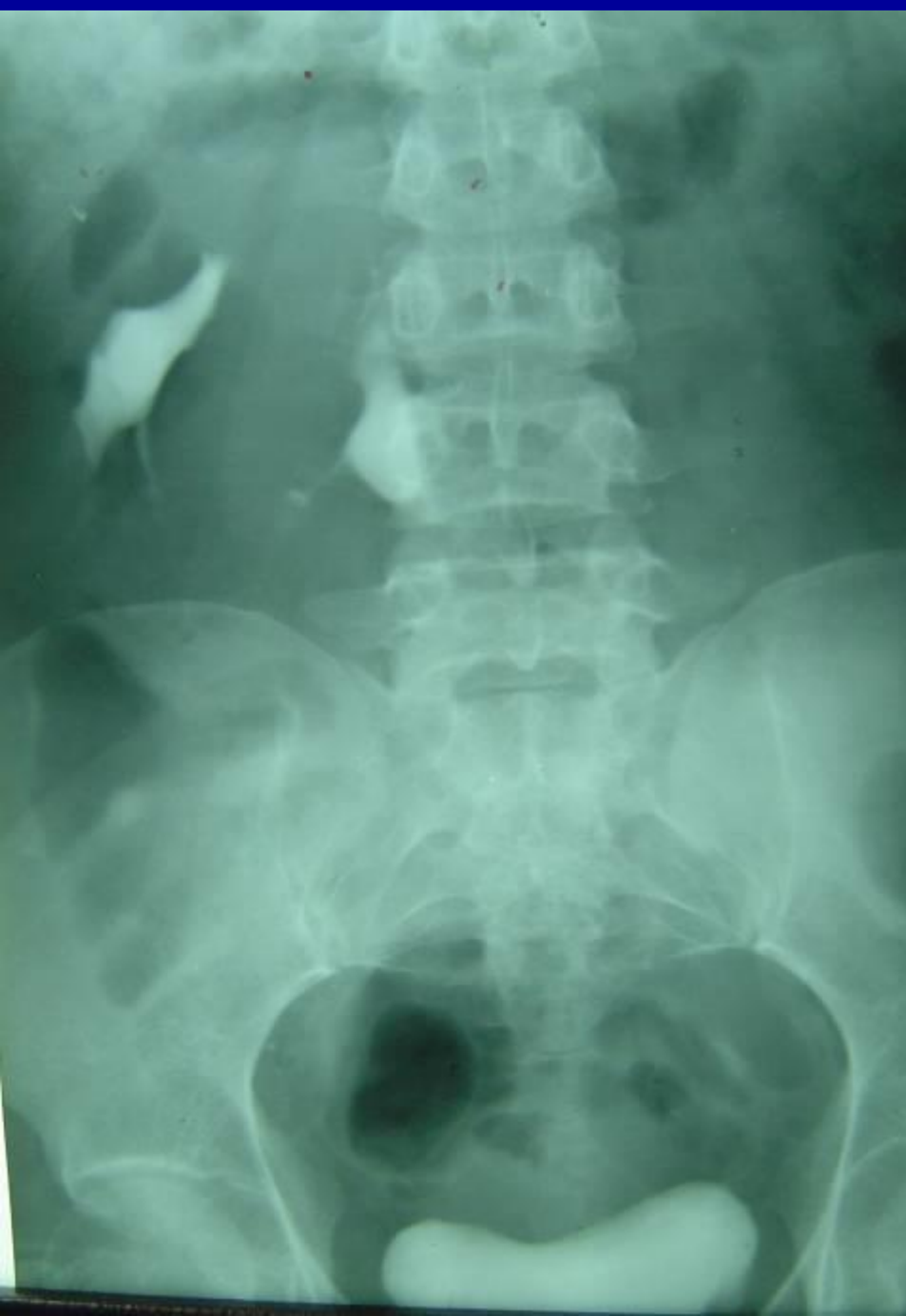
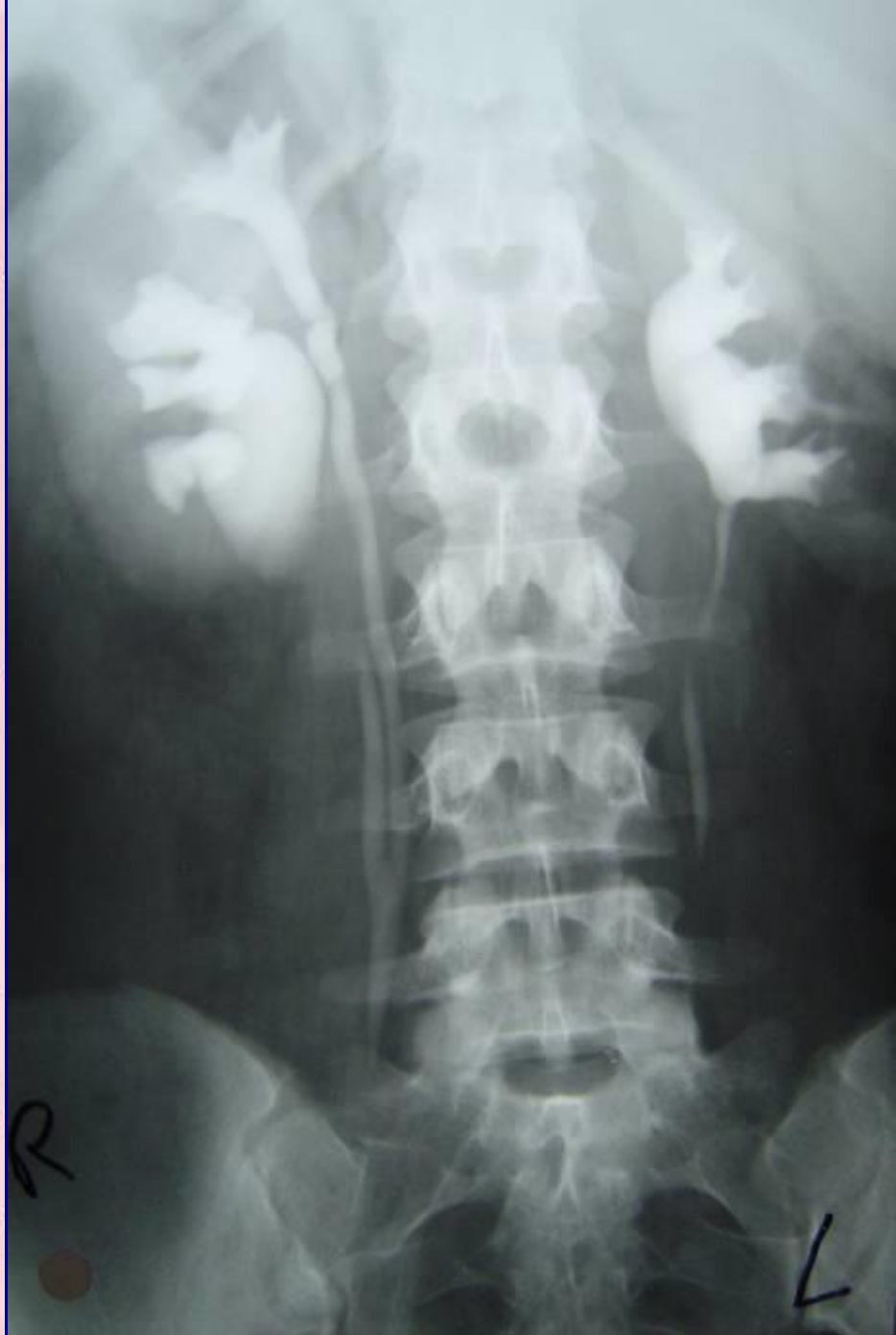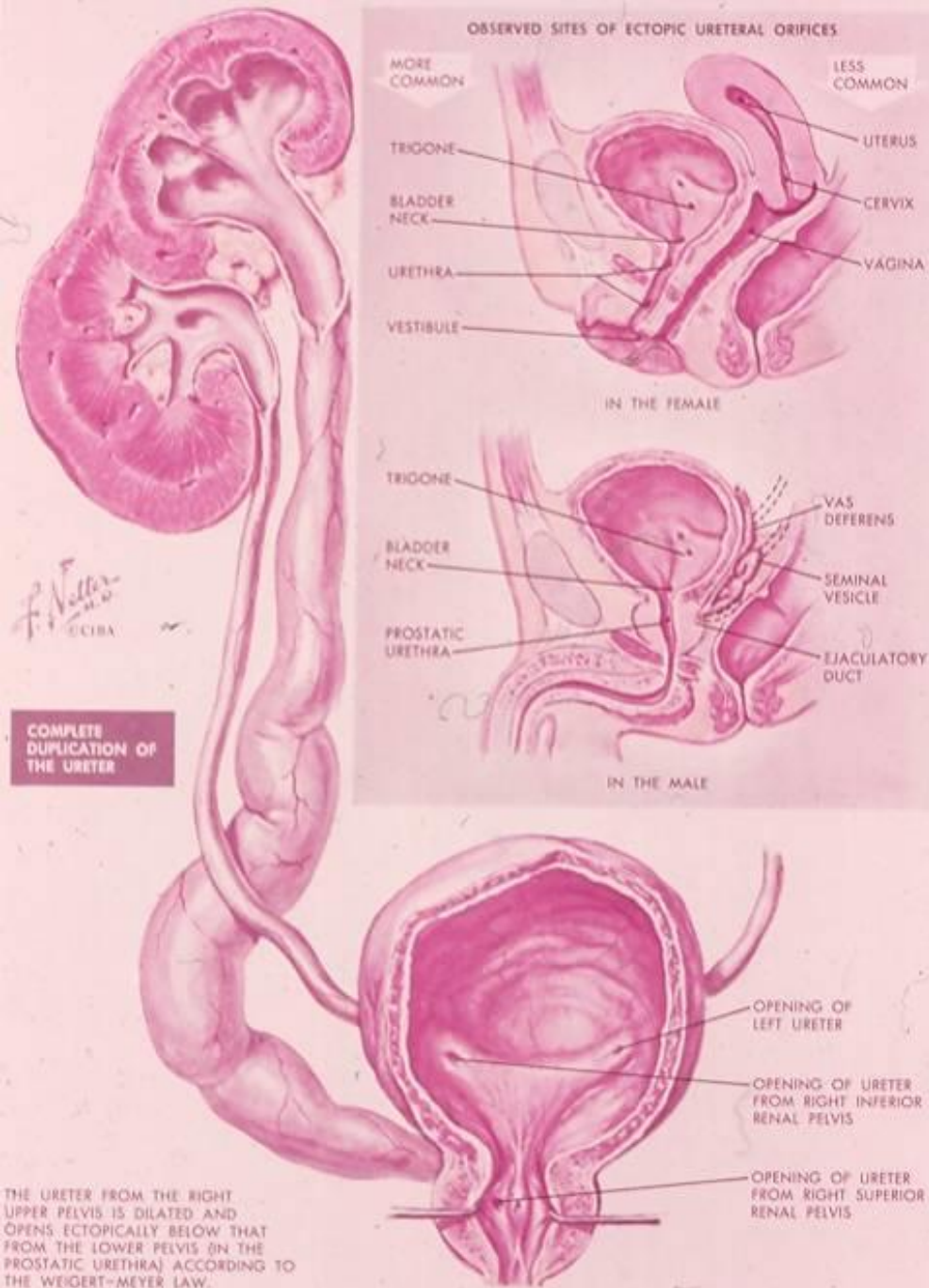





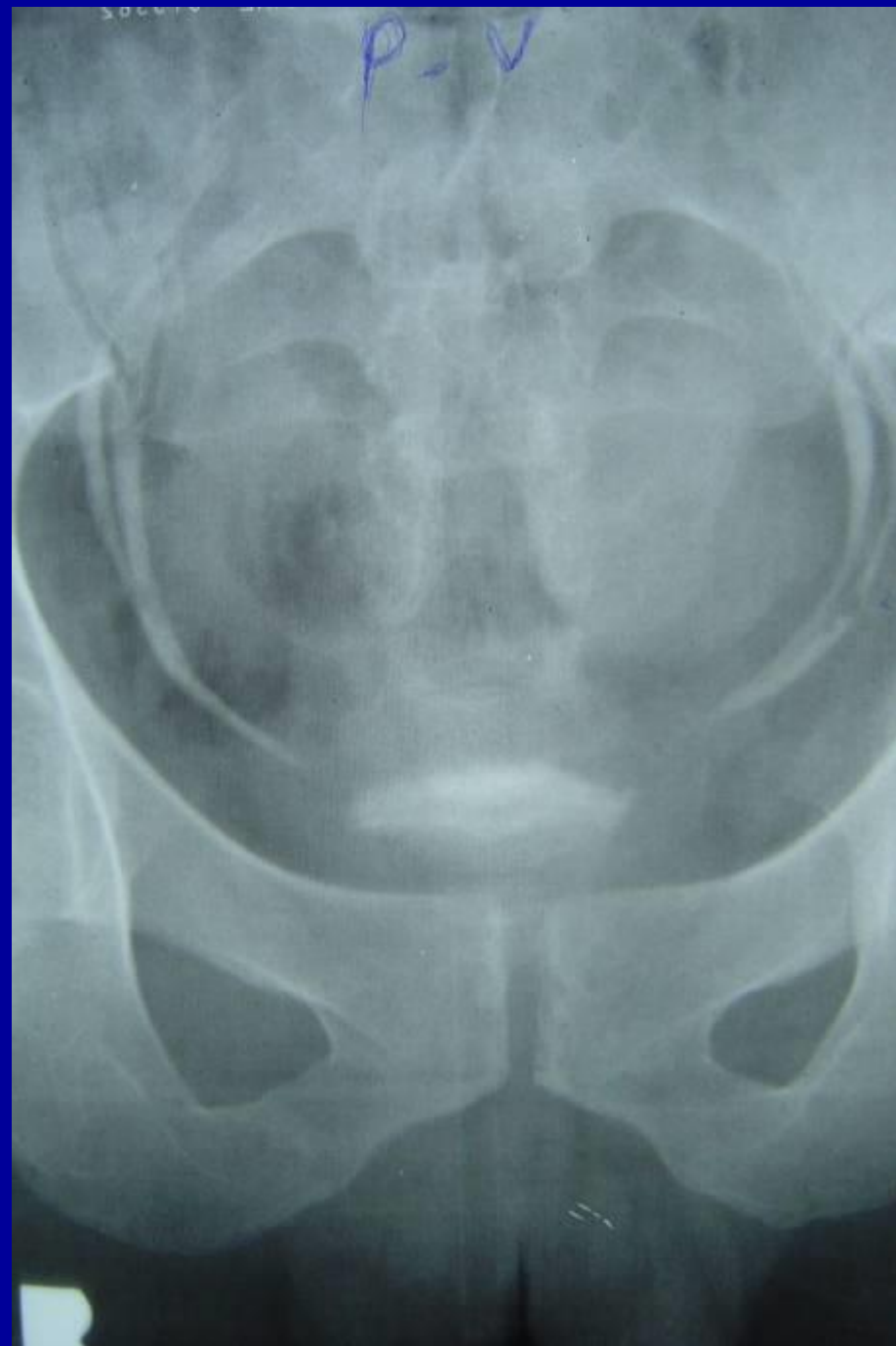
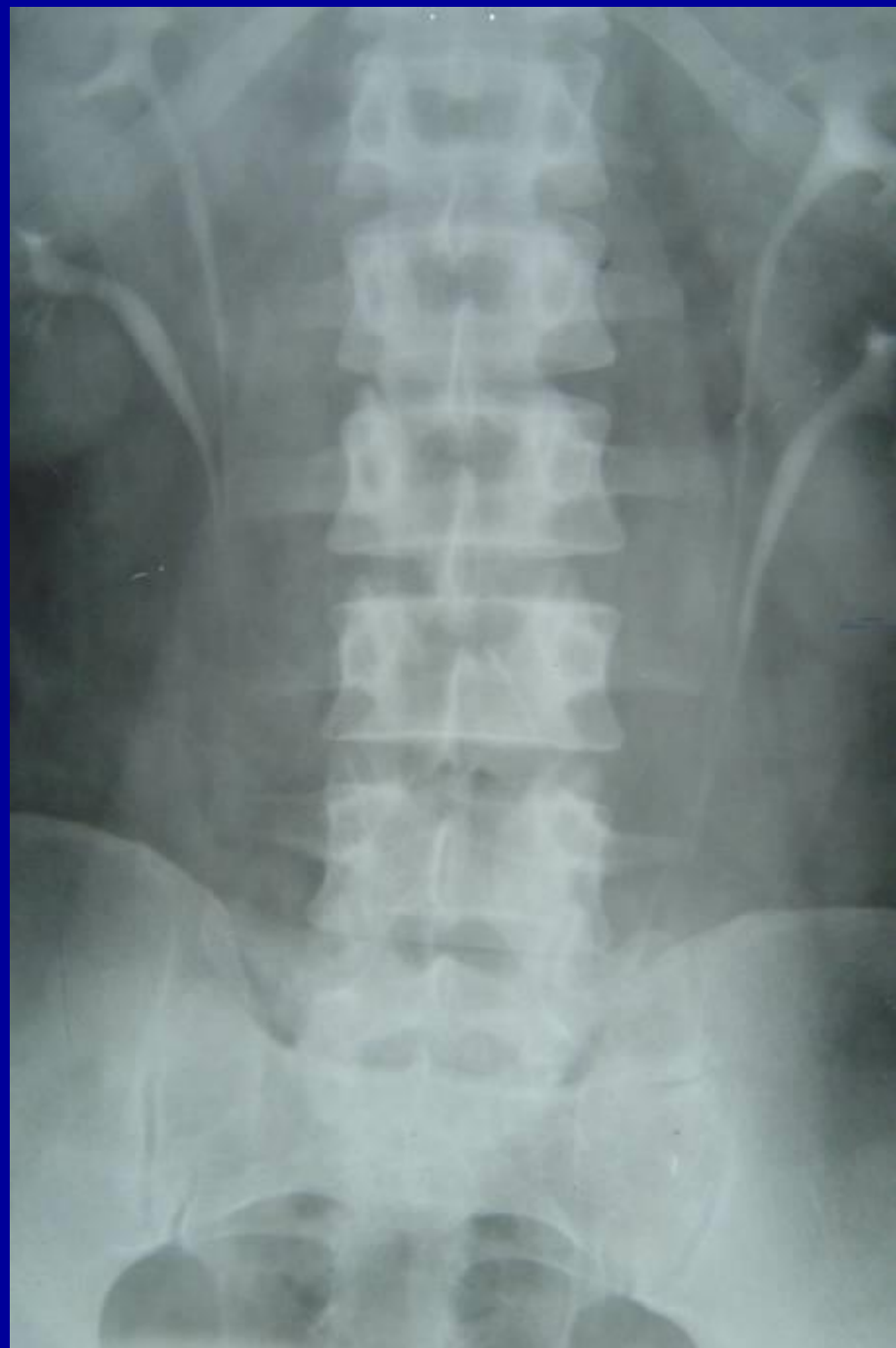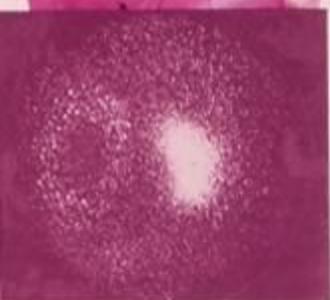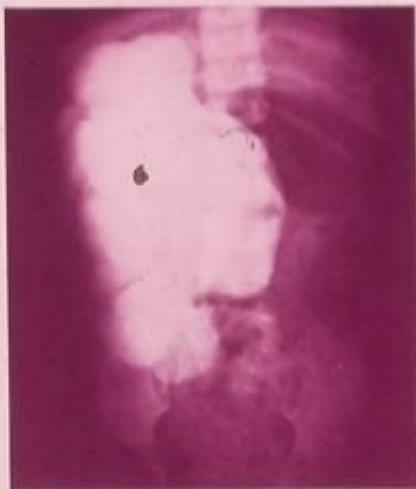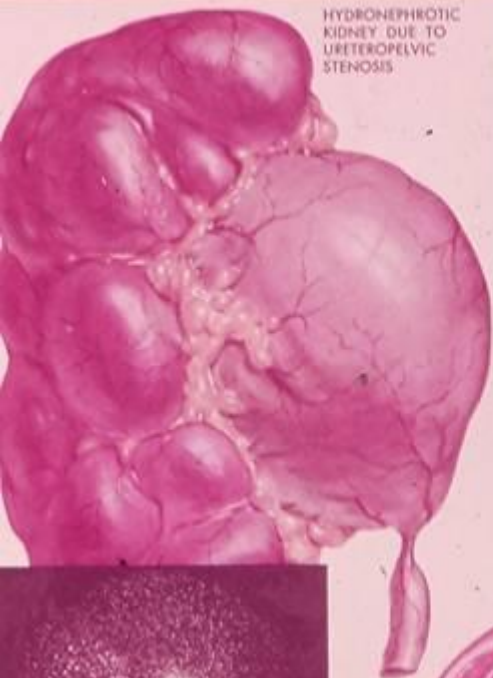




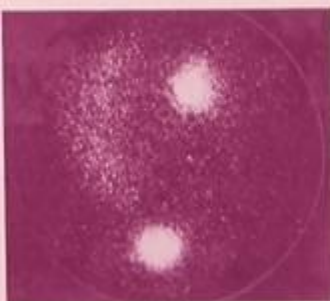




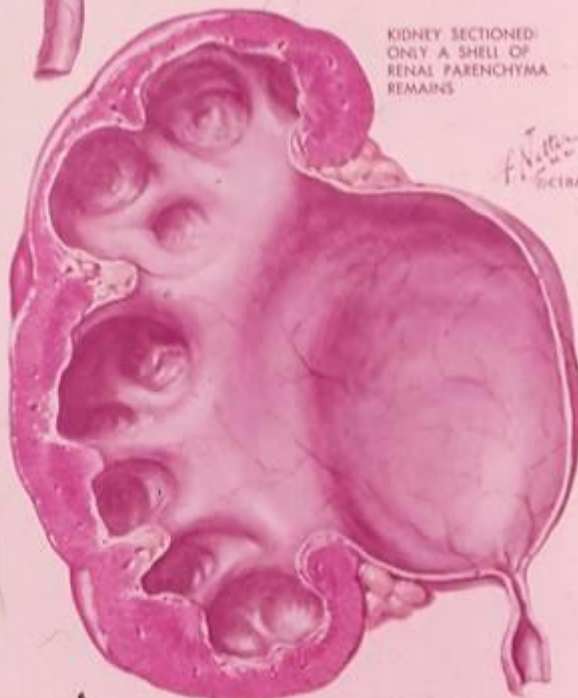




RADIOHIPPURAN SCAN, 2 MINUTES:  
L. KIDNEY NORMAL; R. KIDNEY SHOWS  
JUST A RIM OF PARENCHYMA WITH A  
"COLD" CENTER

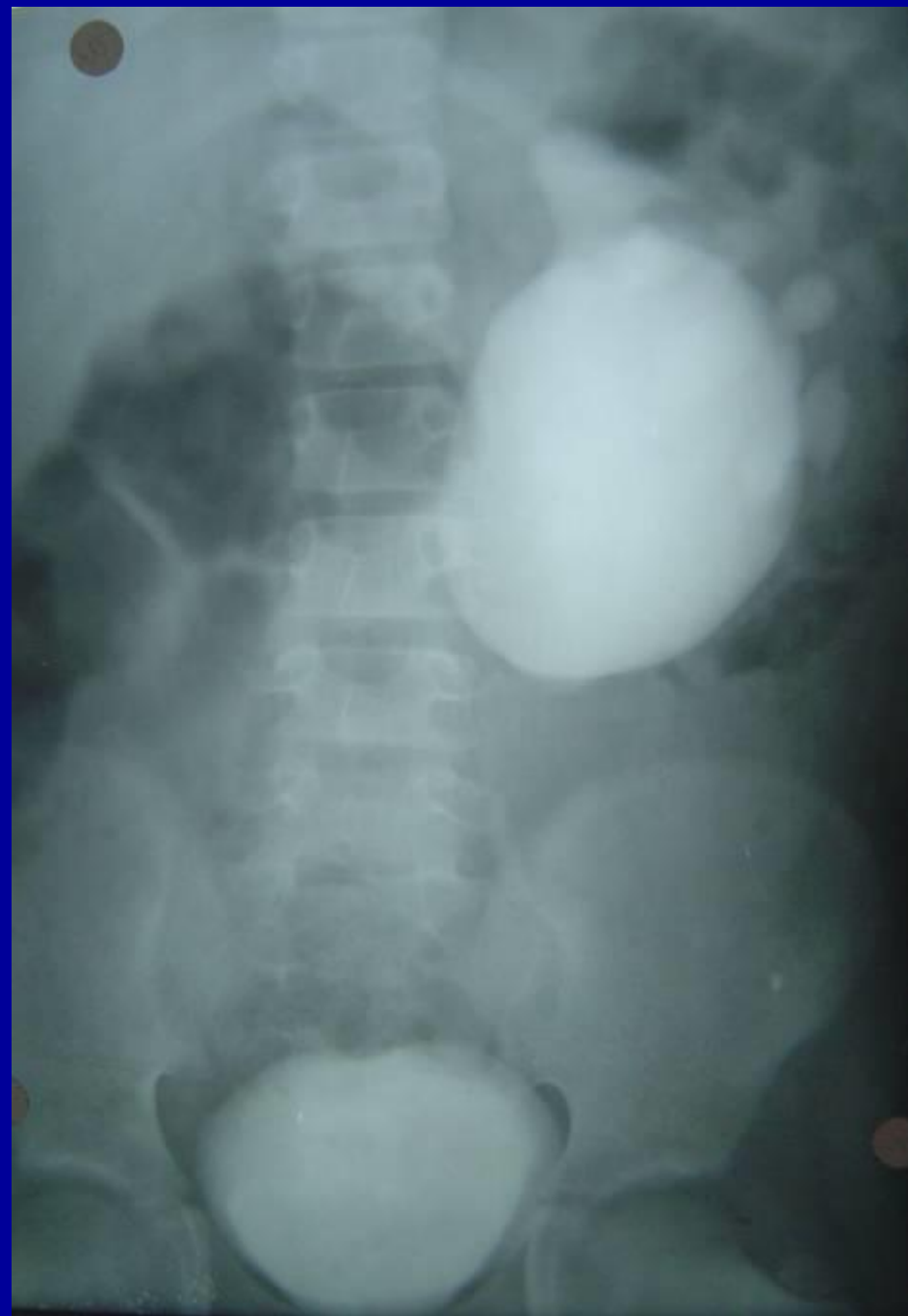

25 MINUTES: ACCUMULATION OF RADIO-ACTIVE URINE IN HUGE HYDRONEPHROTIC  
R. KIDNEY (ALSO IN BLADDER)

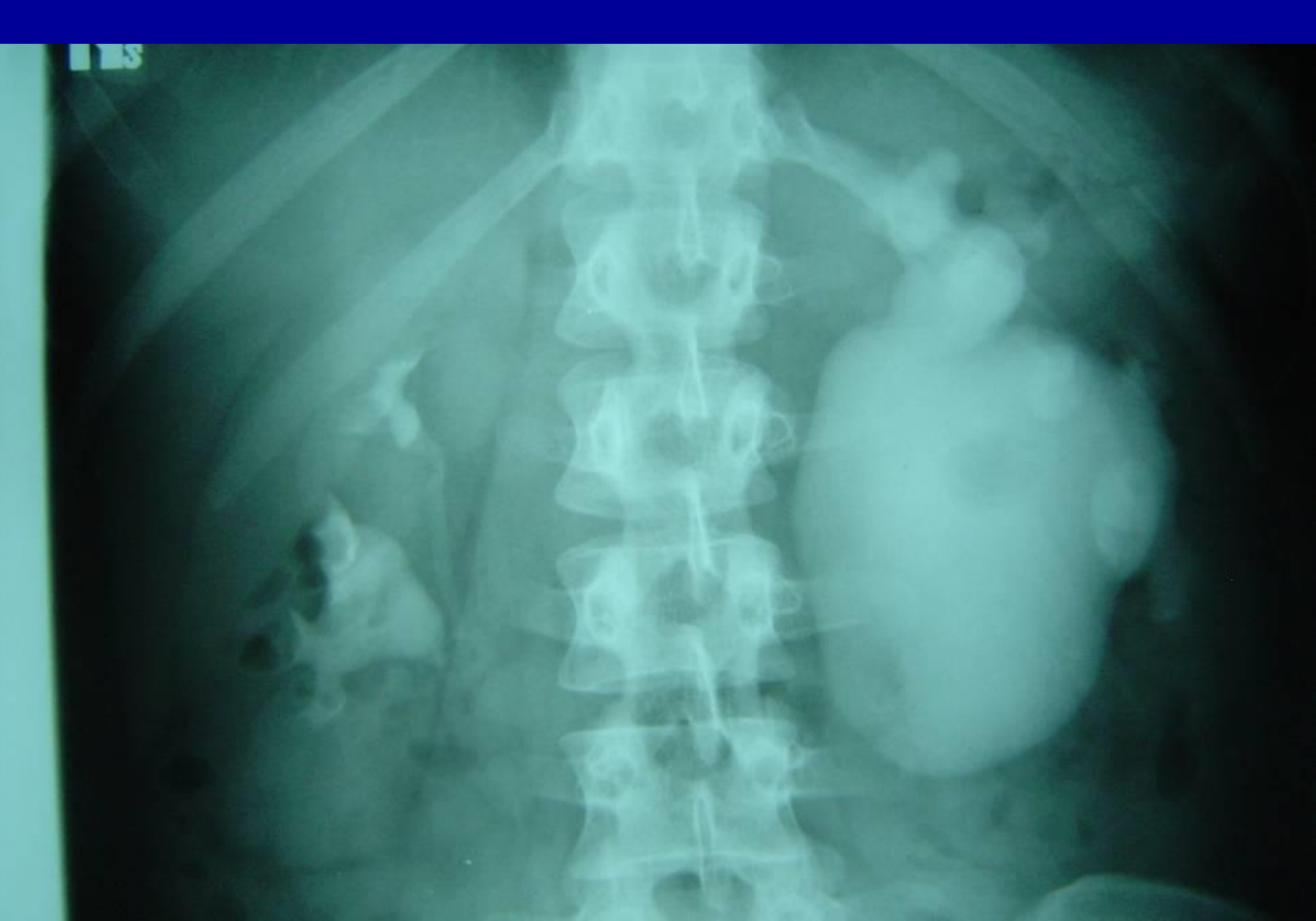

KIDNEY SECTIONED:  
ONLY A SHELL OF  
RENAL PARENCHYMA  
REMAINS

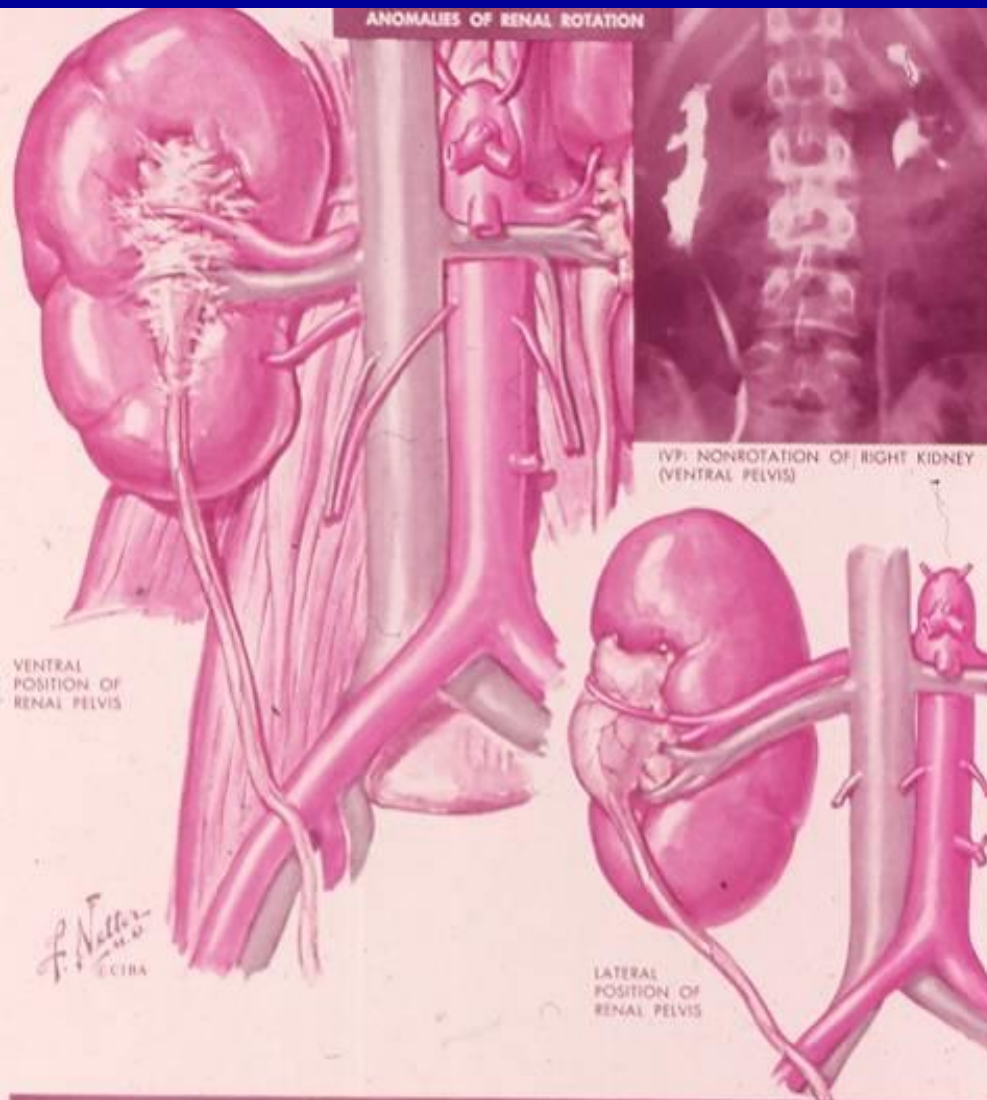
F. J. G.  
1978







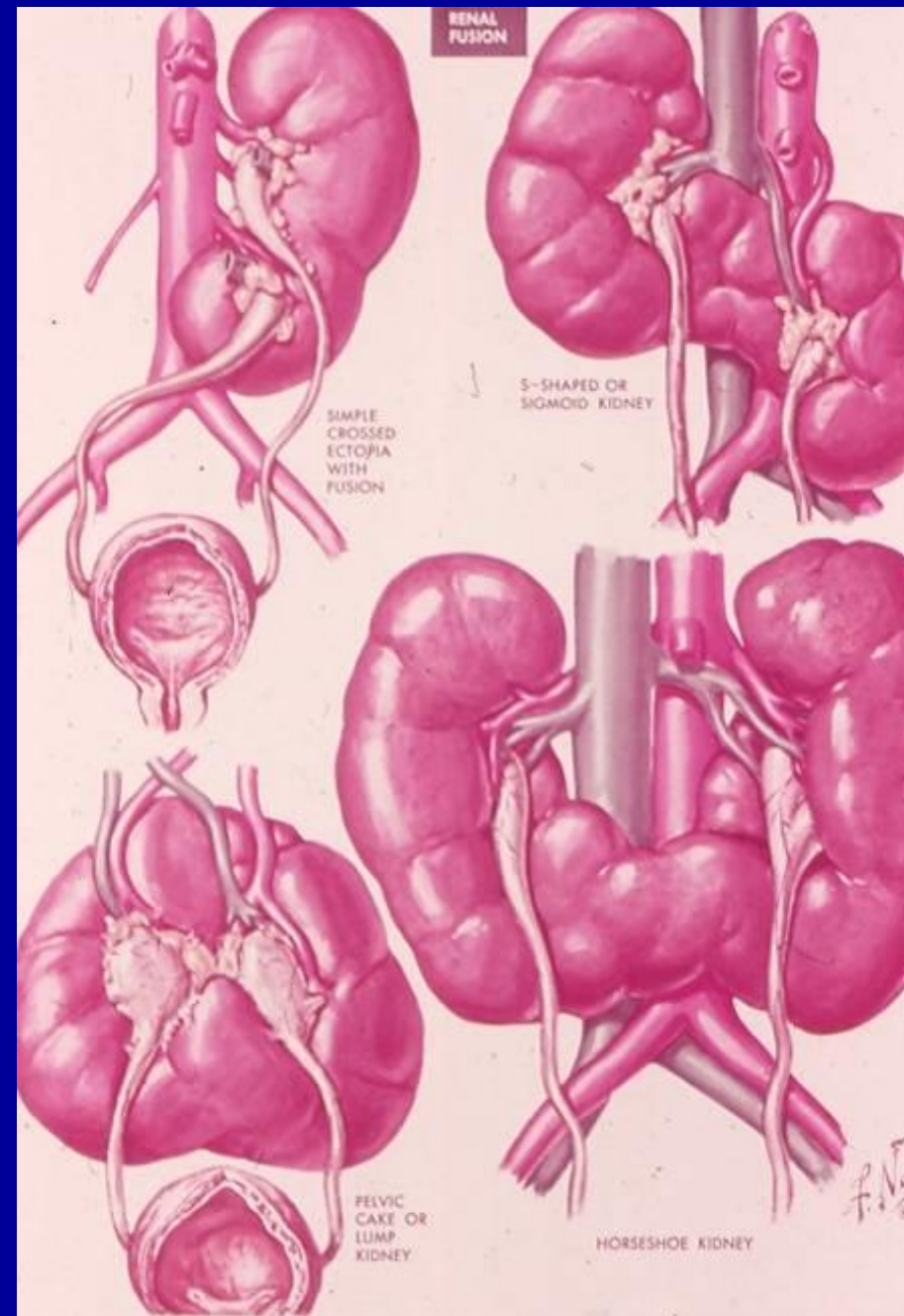
# ANOMALIES OF RENAL ROTATION

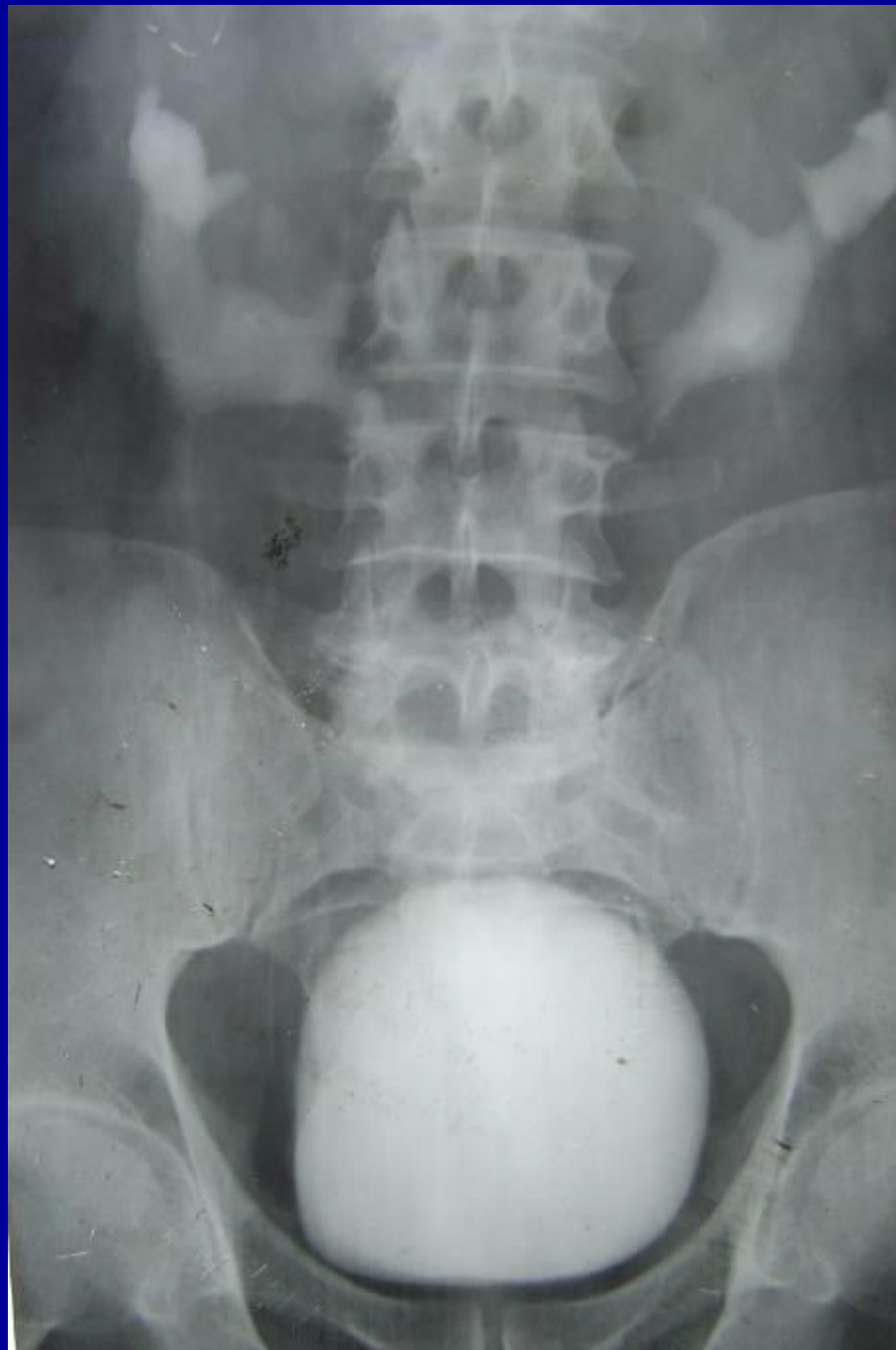
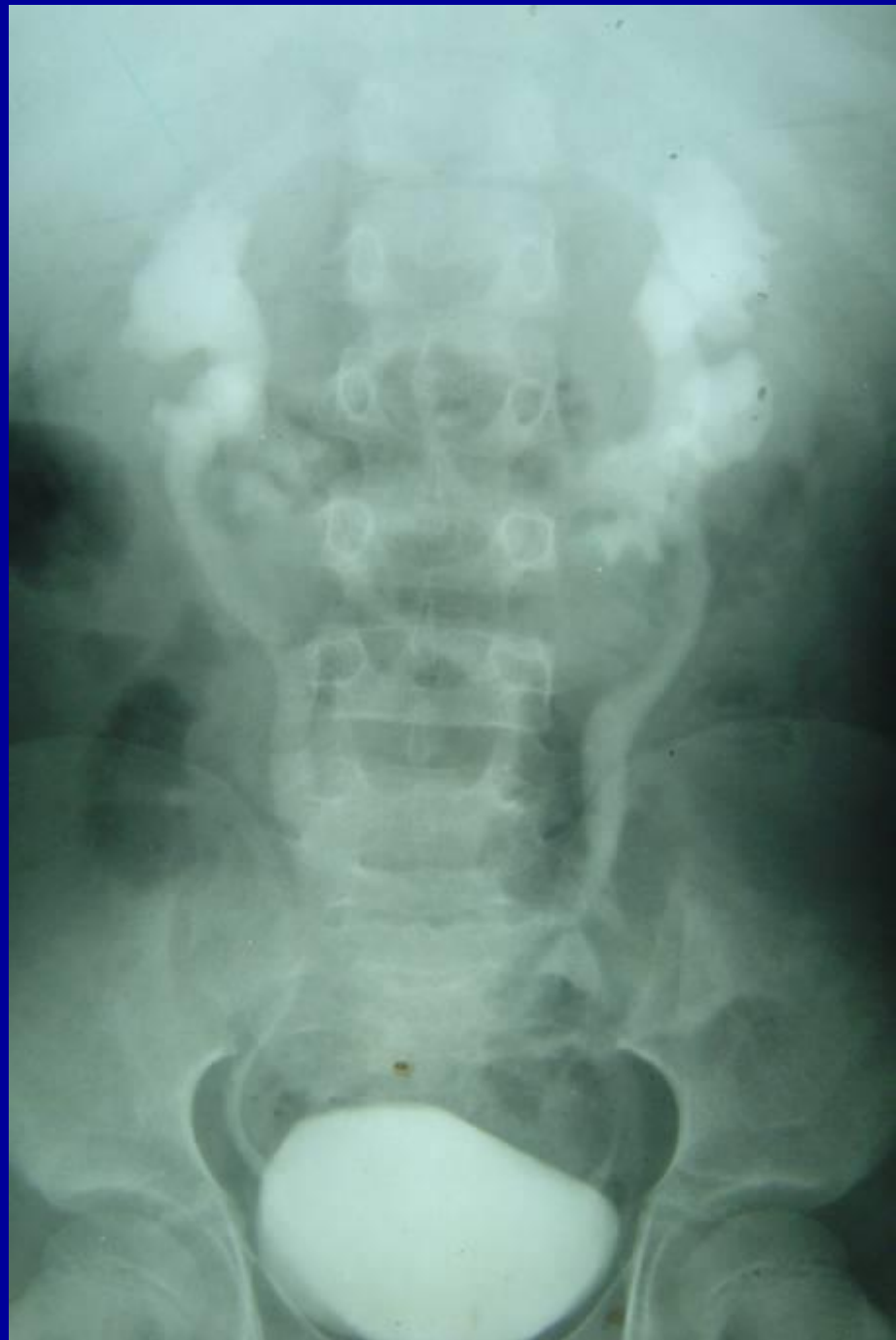
## DEGREES AND VARIETIES OF RENAL MALROTATION

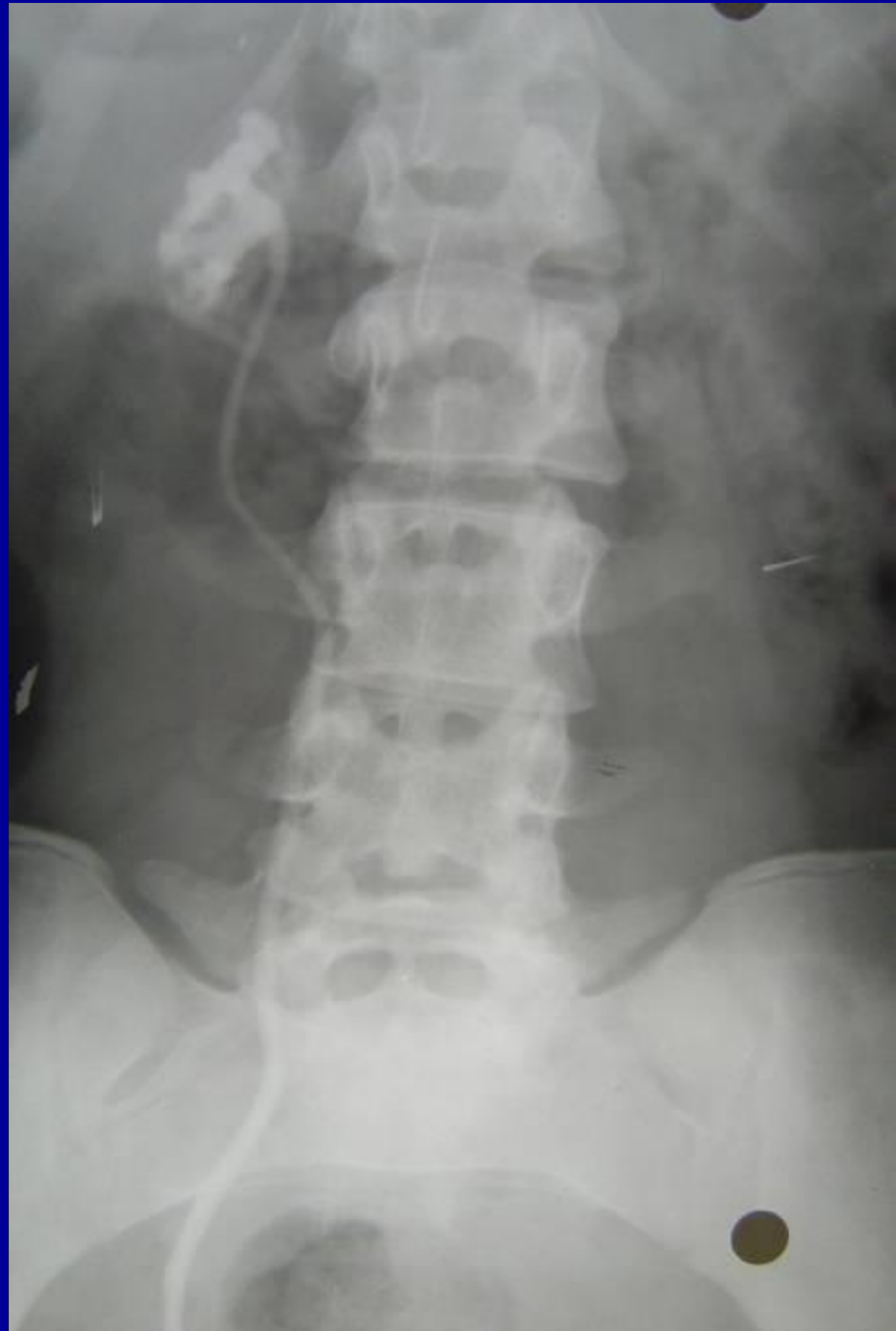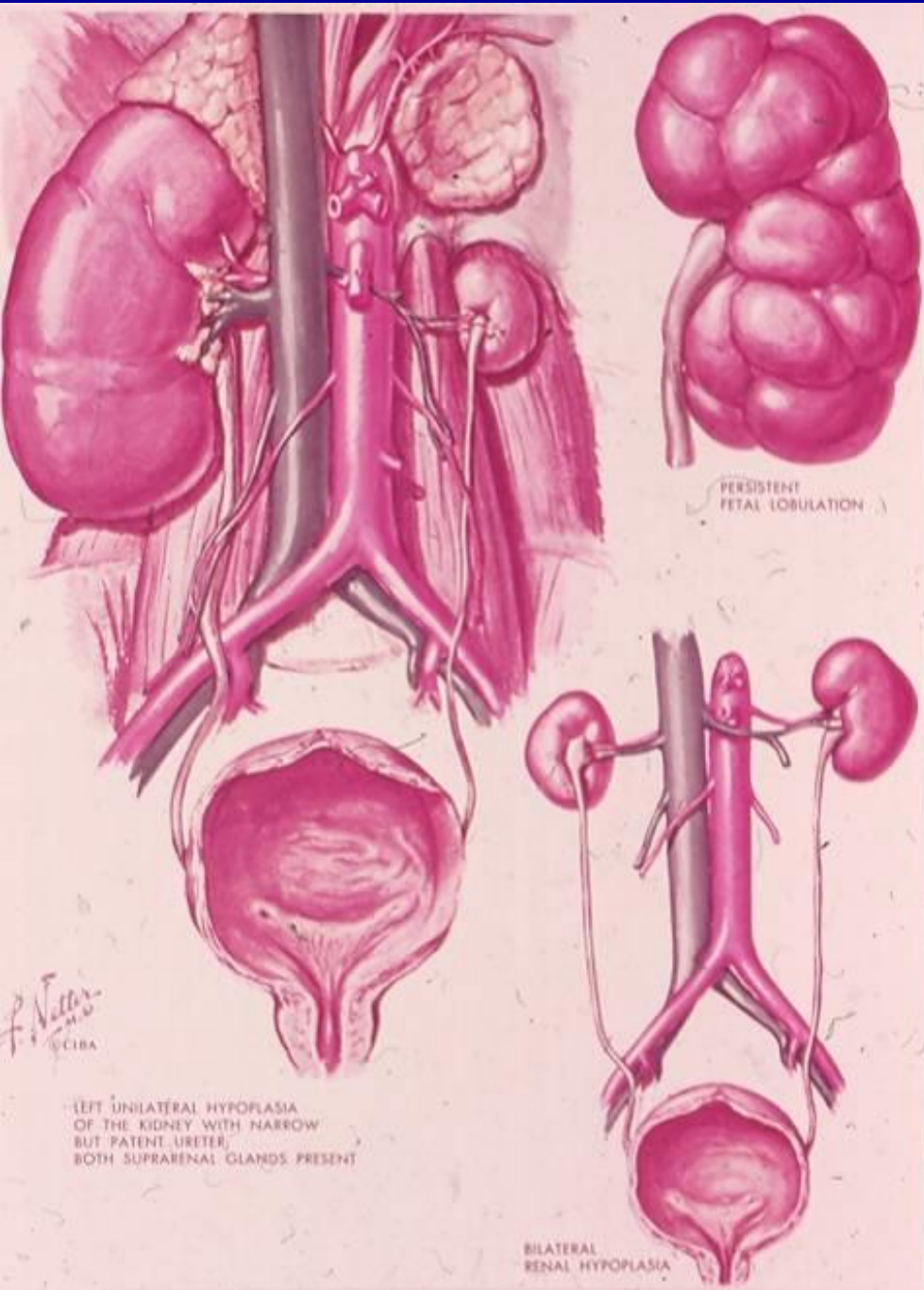


# RENAL FUSION

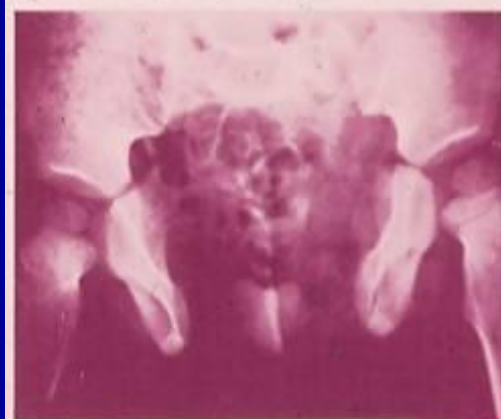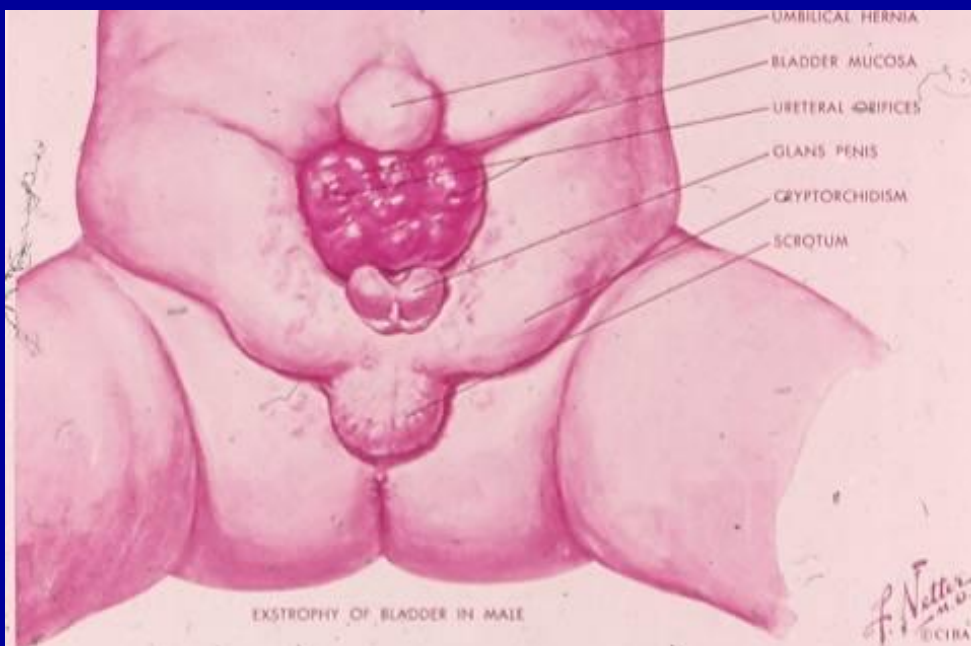




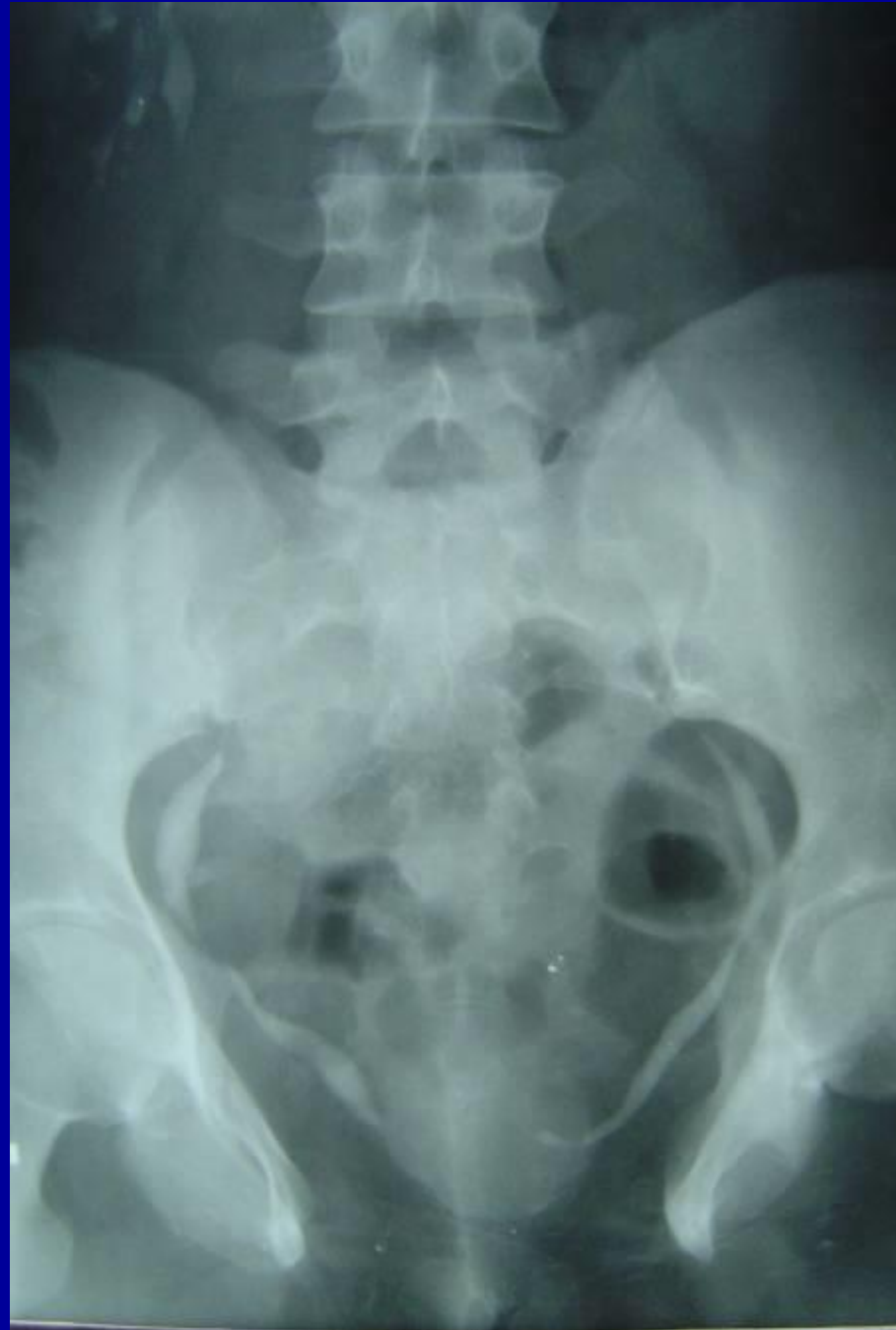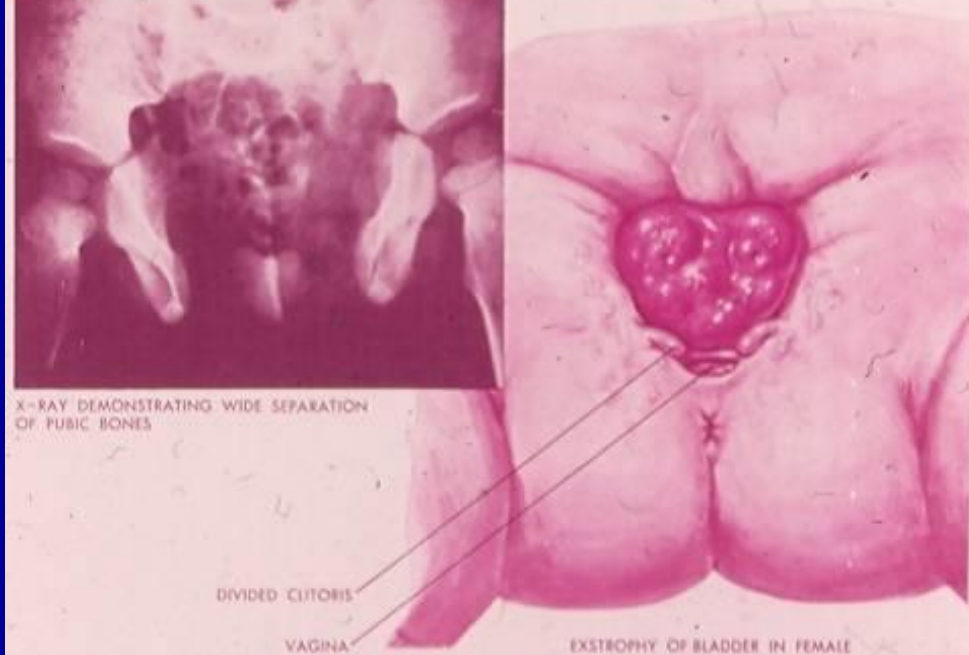








X-RAY DEMONSTRATING WIDE SEPARATION OF PUBIC BONES



# URETEROCELE

