Undescended Testes

By

Dr. Azzawi Mustafa Hadi
Assistant prof. Urology
Tikrit Medical college

Definitions

- Cryptorchidism – “ hidden testis”
- Undescended testis : a failure of the testis to descend into the scrotum, it’s more appropriate term because most testes that are not within the scrotum at birth are detectable by palpation.
- Other terminology:
  - Ascended testis.
  - Gliding testis.
  - Retractile testis.
  - Ectopic testis.
  - Vanishing or absent testis.

Embryology

- Testicular Development
  - Testicular development begins early in fetal life. It is initiated in the 7th week of gestation.
  - By 7 weeks primitive Sertoli cells have developed, and by the 8th week Leydig cells have differentiated.
  - Hormones that control embryonic male sexual defferentiation:
    - Testicular androgen produced by Leydig cells.
    - Mullerian inhibiting substance produced by Sertoli cells.
    - Androgens (Testosterone and dihydroxytestosterone) mediate differentiation of paired wolffian ducts into seminal vesicles, epididymis, vas deferens and ejaculatory ducts.

- Germ cells differentiate into gonocytes at 7th weeks and become fetal spermatogonia by 15 weeks of gestation.
- The gubernaculum appears in the seventh week and extends from the gonad to the fascia between the developing external and internal oblique muscles.
- The external genitalia develop between the 8th and 16th weeks of gestation.

- Testicular Descend
  - Transabdominal passage of the testis from the metanephros to the inguinal ring by 21 weeks.
  - Inguinal transit of the testis from the peritoneal cavity to a position along the processus vaginalis at 28 weeks.
  - Testiculsr descent occur:
    - 10% the descend occurs at 24 weeks.
    - 50% the descend occurs at 27 weeks.
    - 75% the descend occurs at 28 weeks.
    - 80% the descend occurs at 34 weeks to birth.

Incidence

- Isolated cryptorchidism is one of the most common congenital anomalies found at birth.
- Affect 3.4% of full-term male newborns and 30.3% of premature infants (Scorer and Farrington, 1971).
- Unilateral cryptorchidism is more common than bilateral.
- Other studies found that undescended testes are significantly more prevalent in preterm, small-for-gestational-age, low-birth-weight, and twin neonates.
- Approximately 70- 77 % of cryptorchid testes will spontaneously descend, usually by 3 months of age.

- Factors that predict complete spontaneous descent by 3 months of age include:
  - Low birth weight .
  - Bilateral cryptorchidism .
  - Normal scrotal anatomy.
  - Testis that are positioned lower along the normal path of descent.
- Boys with a small or poorly rugated scrotum and boys with hypospadias are more likely to be cryptorchid at 3 months (Cryptorchidism, 1992).
- By 1 year of age, the incidence of cryptorchidism declines to about 1% and remains constant throughout adulthood.

Epidemiology

- Epidemiologic factors that affect the risk for undescended testes are made more difficult by the complex interactions among anatomy, heredity, hormonal, socioeconomic and environmental conditions.
- Can be one of congenital abnormalities like hypothalamic-testicular malfunction, Malformation of inguinal canal and abnormal gubernaculum.
- Low birth weight, IUGR, Prematurity and Hypospadia associated with increase risk.
- Birth weight may be the principal determinant of cryptorchidism at birth and at 1 year of life, independent of the length of gestation. (Hjertkvist et al, 1989 ; Mayr et al, 1999).

- The risk for an undescended testis in a newborn male if a family member is already affected is:
  - 3.6-fold overall.
  - 6.9-fold if a brother is affected.
  - 4.6-fold if the father is affected.

Classification

- Number of classification systems have been devised, ***Kaplan*** (1993) proposed the most popular system, which categorizes cryptorchid testes as:
  - **Palpable:** testes descended beyond the internal ring.
  - **Non palpable:** testes are intra-abdominal.
- The subjective nature of the physical examination confounds the accurate classification of testicular position; more accurate assessment occurs at the time of surgery.
- Cryptorchid testicular position described as:
  - Intra-abdominal.
  - Intra-canalicular.
  - Extra-canalicular .(supra-pubic or infra-pubic)
  - Ectopic.

- Approximately 80% of undescended testes are clinically palpable and 20% are non palpable.
- About 18% of non palpable testes could be palpated during physical examination under anesthesia.
- About 80 % of undescended testes are unilateral.
- **Intra-abdominal testis** is usually located just inside the internal ring, commonly within a few centimeters. Testes may also lie at a high annular position at the internal ring, these testes have been referred to as "**peeping**" because they can move between the abdominal cavity and inguinal canal.
- Rarely, a testis is found in ectopic intra-abdominal positions such as in the perihepatic and perisplenic regions.
- **Intracanalicular testis** is occasionally difficult to palpate and lies within the inguinal canal, between the internal and external ring.

- **Suprapubic testis** lies just beyond the external ring, above the level of pubic symphysis.
- **Infrapubic testis** lies just below the pubic symphysis, often just outside the anatomic scrotum in the retroscrotal space.
- **Ectopic testis** completes normal transinguinal migration but it is misdirected outside the normal path of descent below the external ring.
- The most common ectopic location is within a superficial pouch between the external oblique fascia and Scarpa's fascia, a structure that has been termed the **Denis-Browne pouch**.
- Other abnormal locations include transverse scrotal, femoral, perineal, and prepenile ectopia.

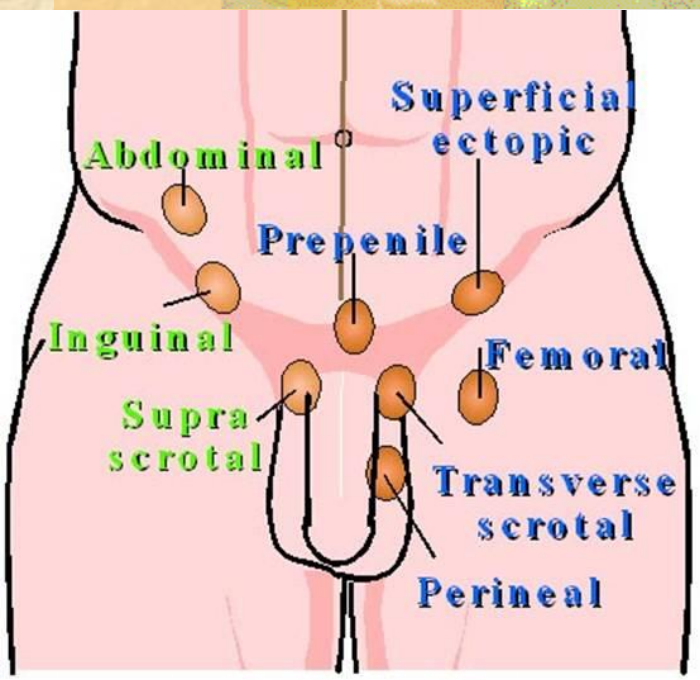

© 1992 Philippe Jeanty

True undescended testicle

Ectopic testicle

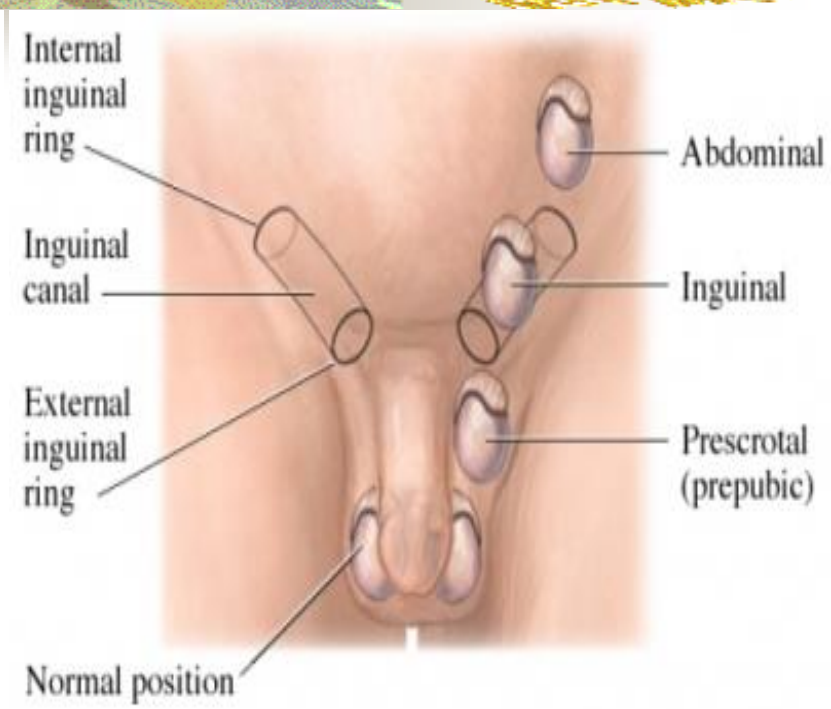

- The term “nonpalpable testis” implies that the testis cannot be detected on physical examination and therefore is either intra-abdominal, absent (vanishing), atrophic, or missed on physical examination.
- **Vanishing** or **Absent testis** is usually encountered during exploration for a nonpalpable testis. The anatomic hallmark of a vanishing testis is blind-ending spermatic vessels that are found just proximal to the internal inguinal ring.
- **Atrophic testis** is a smaller than normal testis that may be cryptorchid .
- These testes can be encountered anywhere along the course of normal descent from within the abdomen to the scrotum.

- **Retractile testis** withdraws spontaneously out of the scrotum toward the inguinal canal by an active cremasteric reflex but can easily be brought down into a dependent position within the scrotum and remains there after traction has been released.
- This condition is considered a variant of normal.
- The risk of ascent may be as great as 50% in children with a “significantly” retractile testis.
- A retractile testis can be found anywhere along the course of descent, but it is usually palpable in the groin on initial examination.
- Most commonly encountered between the ages of 3 and 7 years.
- Retractile testes have normal testicular volume and a normal fertility rate in adulthood.

Consequences of Cryptorchidism

- Infertility.
  - Impairment of germ cell maturation is a well-recognized consequence of cryptorchidism.
  - No significant difference in the fertility index was seen in patients 1 year or younger when comparing undescended with descended testes but that fertility index differences were significantly abnormal in all other age groups.
  - Sperm counts were reported to be normal in approximately 20% of men with a history of bilateral cryptorchidism and 80% of men with unilateral cryptorchidism.

- Biopsy findings from children with unilateral cryptorchidism typically demonstrate reduced total germ cell counts as a result of failure of the two prepubertal steps involved in maturation and proliferation of germ cells:
  - (1) transformation of the fetal stem cell pool (gonocytes) into the adult stem cell pool (Ad spermatogonia) at 2 to 3 months of age and
  - (2) transformation of Ad spermatogonia into primary spermatocytes (meiosis) at 4 to 5 years.
- The risk for later infertility was as high as 90% in the absence of transformation.

- Neoplasia .
  - Approximately 10% of testicular tumors arise from an undescended testis. (Whitaker, 1970)
  - The location of the undescended testis affects the RR for tumor development. The higher the position of the undescended testis, the greater the risk for development of a malignancy.
  - Almost half the tumors that develop from undescended testes occur in testes located abdominally, sixfolds higher than for inguinal testes.
  - The most common tumor that develops from a cryptorchid testis is **Seminoma** .

- The prevalence of carcinoma in situ is 1.7% in patients with cryptorchidism.
- Carcinoma in situ is more commonly detected in abdominal testes.
- Routine testicular biopsy during childhood Orchiopexy appears to have no predictive value for the development of later malignant degeneration, because no evidence of histological premalignant changes occurring before the onset of puberty was observed in men in whom testicular malignancies later developed.

- Hernia.
  - A patent processus vaginalis is found in more than 90% of patients with an undescended testis.
  - The processus normally closes between the period after complete testicular descent and the first month after birth.
  - High incidence of epididymal anomalies is associated with a patent processus vaginalis.

- Torsion.
  - The increased susceptibility of the testis to undergo torsion is the result of a developmental anatomic abnormality between the testis and its mesentery.
  - The mechanism is believed to be related to a greater relative broadness of the testicle than its mesentery (Scorer and Farrington, 1971).
  - Although torsion of an undescended testis is rare, it should be considered in any child with abdominal or groin pain and an empty ipsilateral hemiscrotum.

Diagnosis

- Approx. 20% of undescended testes are impalpable on initial examination.
  - 20% of testes are absent .
  - 30% of testes are atrophic.
- **History:**
  - Preterm and maternal history.
  - Perinatal history, including documentation of a scrotal examination at birth.
  - The child's medical and previous surgical history.
  - Family history of cryptorchidism or syndromes.

- **Physical examination:**
  - Requires a relaxed child observed in the supine , sitting and squatting position.
  - Inspection for any penile malformations, including hypospadias, micropenis, or ambiguous genitalia.
  - Symmetry and development of the scrotum.
  - Inspection of the Inguinal canal.
  - Gonad s should be carefully examined for size, turgor, any palpable paratesticular anomalies, and the presence of a hernia or hydrocele.
  - Warm hands and soapy water on the fingertips to reduce skin friction.
  - The examiner's fingers are swept down from just above the internal ring along the inguinal canal into the scrotum.

- Imaging:
  - Ultrasonography.
  - CT & MRI.
  - Angiography.
  - Venography.
  - Pneumoperitoneography.
- Many of these techniques are invasive, require anesthesia, are technically difficult to perform, or associated with a significant rate of false-negative results.
- The overall accuracy of radiologic testing for an undescended testis is 44%.

- Investigations:
  - **Genetic karyotyping**.
  - **HCG stimulation test**: conventional regimen is 5000 U hCG divided into six injections over a period of 3 weeks, with DHT, FSH, and LH levels rechecked within 24 hours of last dose.
  - All boys with nonpalpable testes and normal serum gonadotropin levels must undergo surgical exploration regardless of the results of the hCG stimulation test.
  - Measurement of serum **Mullerian Inhibitory Substance (MIS)** and **Inhibin B**.

Treatment

- Definitive treatment of an undescended testis should take place between 6 and 12 months of age.
- The approach and timing should be predicated on the anatomic position and whether both testes are undescended.
- Hormonal therapy:
  - GnRH or LHRH– *Hadziselimovic 1984*
  - hCG – *Polaschik 1996*
- The mechanism of action in both cases increases serum testosterone production by stimulation of the hypothalamic-pituitary-gonadal cascade.
- hCG stimulates Leydig cells directly to produce testosterone, whereas GnRH stimulates the pituitary to release LH and thereby promote testicular production of testosterone.

- Successful results are more commonly reported in older groups of children and in testes that were retractile or below the external inguinal ring, that is, the lower the pretreatment position, the better the success rate.
- Regular reexamination of children treated with hormonal therapy is indicated because re-ascent has been reported in up to 25% of patients.
- Hormonal treatment is not indicated in patients with previously operated testes or prior surgery that would result in inguinal scar tissue formation, in those with ectopic testes, or in those with an inguinal hernia.
- Most effective treatment demonstrated to be a total dose of at least 10,000 IU to achieve maximal stimulation of the Leydig cells.
- A typical treatment schedule is 1500 IU/m^2 given by intramuscular injection twice a week for 4 weeks.

- Side effects of hormonal treatment(with doses exceeding 15,000 IU) include increased rugation and pigmentation of the scrotum.
- Rarely, there is an increase in size of the penis and the development of pubic hair, which regresses after cessation of therapy.
- hCG should be avoided in immunosuppressed patients because of a transient decrease in the absolute number of total peripheral blood lymphocytes, total T cells, helper-inducer T cells, and CD8 during therapy.
- The overall efficacy of hormonal treatment is less than 20% for cryptorchid testes and is significantly dependent on pretreatment testicular location.
- Surgery remains the gold standard for the management of undescended testes.

- Surgical Treatment:
- It is very useful to examine the child after induction of general and regional anesthesia to reaffirm testicular position or attempt to establish testicular position in the case of a previously non palpable testis.
- Success rates for surgery are directly related to the anatomic position of the testis.
- In case of erectile testes, annual follow up is necessary , and the surgical interference indicated only if:
  - Testes ascend.
  - Puberty.
  - Torsion.

- **Standard Orchiopexy:**
- The key steps in this procedure are :
  - Complete mobilization of the testis and spermatic cord.
  - Repair of the patent processus vaginalis by high ligation of the hernia sac.
  - Skeletonization of the spermatic cord without sacrificing vascular integrity to achieve tension-free placement of the testis within the dependent position of the scrotum.
  - Creation of a superficial pouch within the hemiscrotum to receive the testis.

- **A transverse inguinal skin incision is made in the midinguinal canal, usually in a skin crease in children younger than 1 year**
- **The dermis is opened with electrocautery, and subcutaneous tissue and Scarpa's fascia are opened sharply.**
- **The skin and subcutaneous tissue are quite elastic in younger children and allow for a tremendous degree of mobility by retractor positioning for viewing the entire length of the inguinal canal.**

One should be careful to observe that the testis is in the superficial inguinal pouch

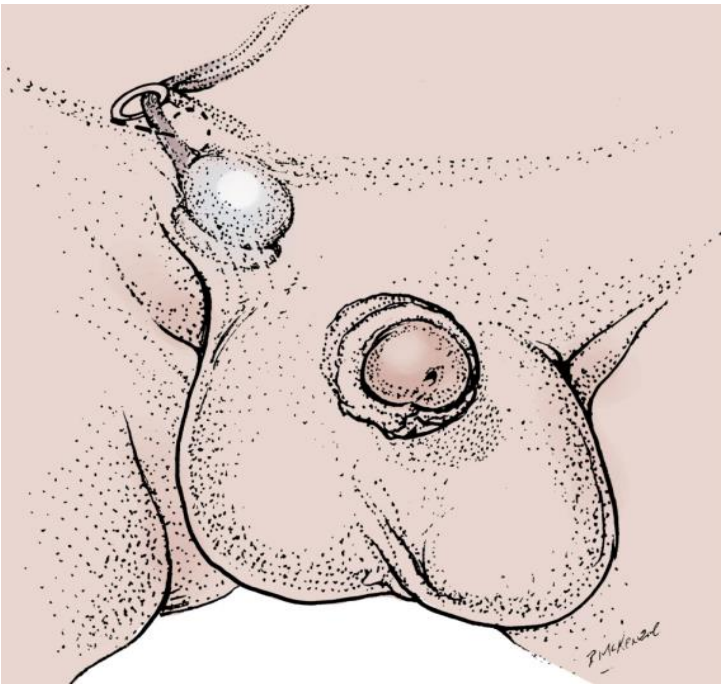

A,The external ring is opened.

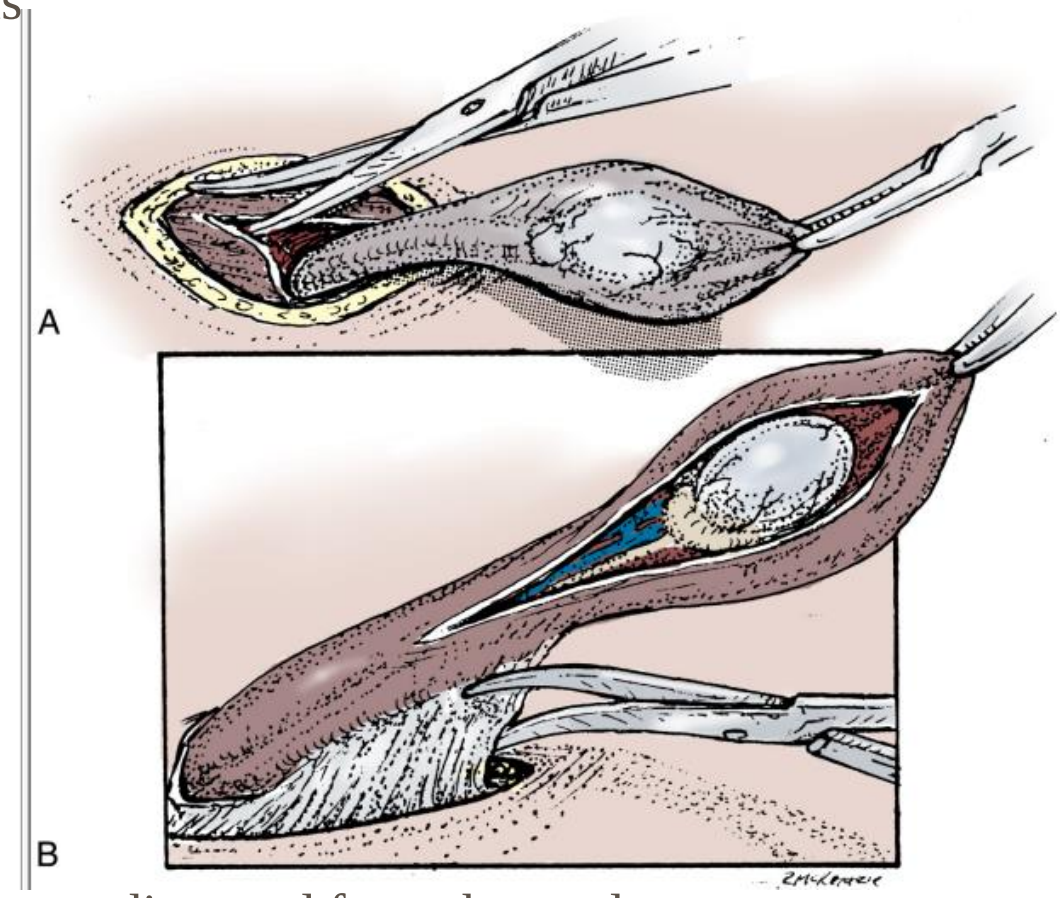

B, Cremasteric fibers are dissected from the cord

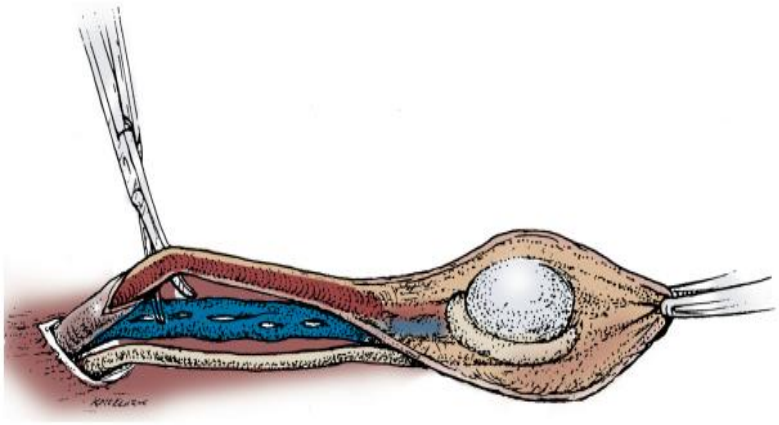

A. High ligation of the processus vaginalis at the internal inguinal ring.

B. The ligated processus and the cord structures

Figure 127-3 Dissection to separate the processus vaginalis from the cord structures.

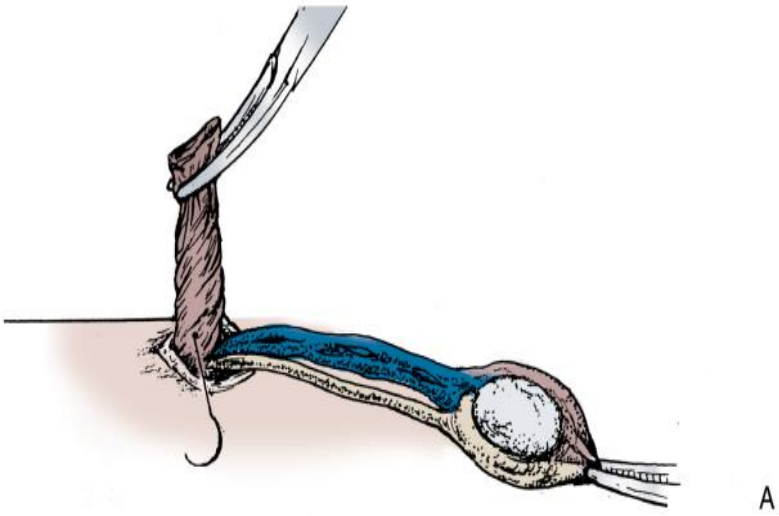

A

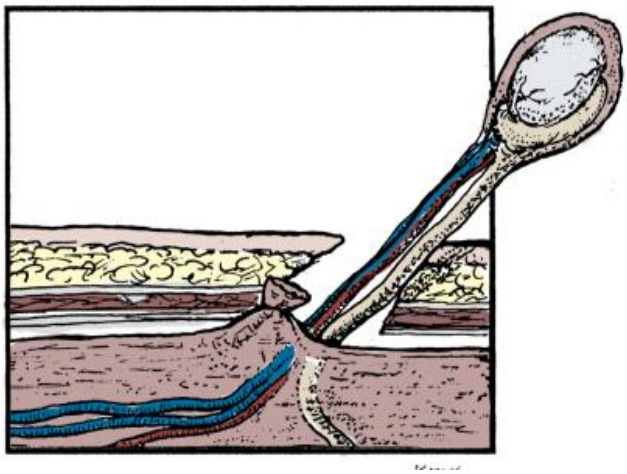

B

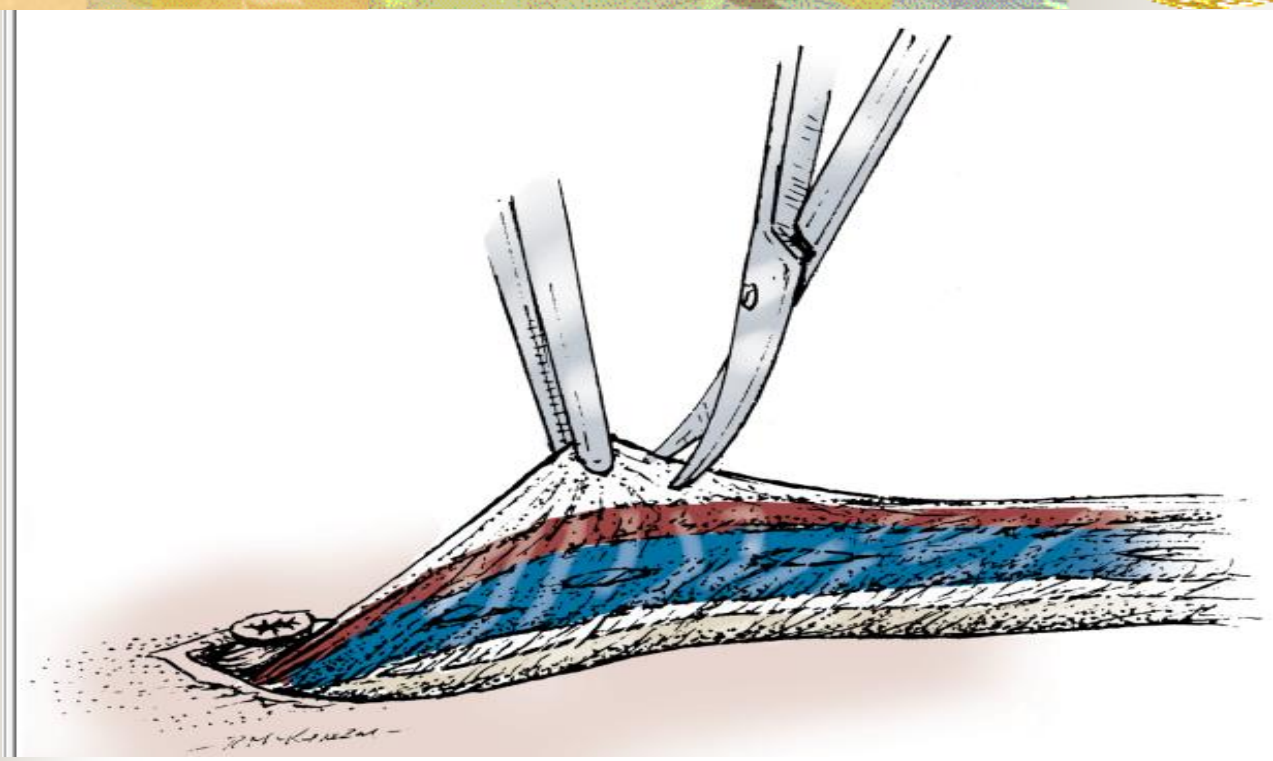

Separation of the internal spermatic fascia from the cord structures after ligation of the processus vaginalis

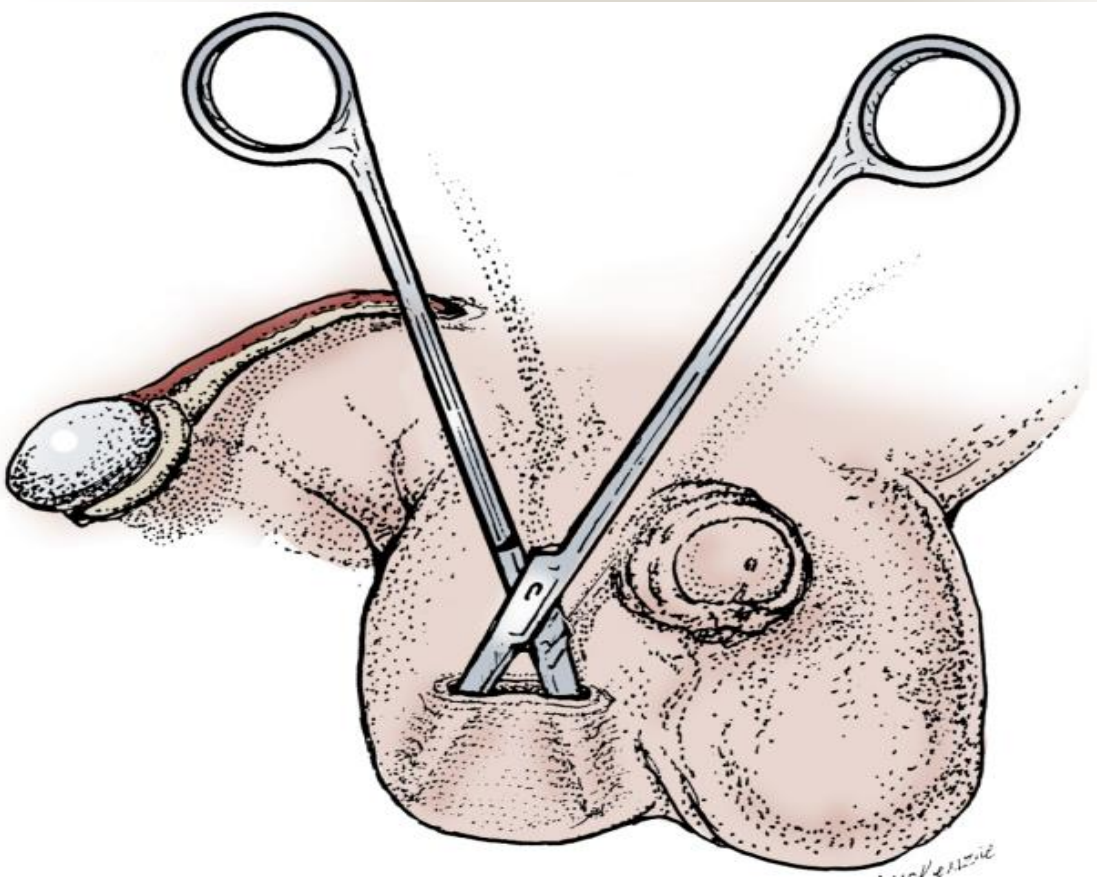

Formation of a dartos pouch

A, Formation of a passage to the scrotum.

B and C, Passage of the testis into the scrotal pouch

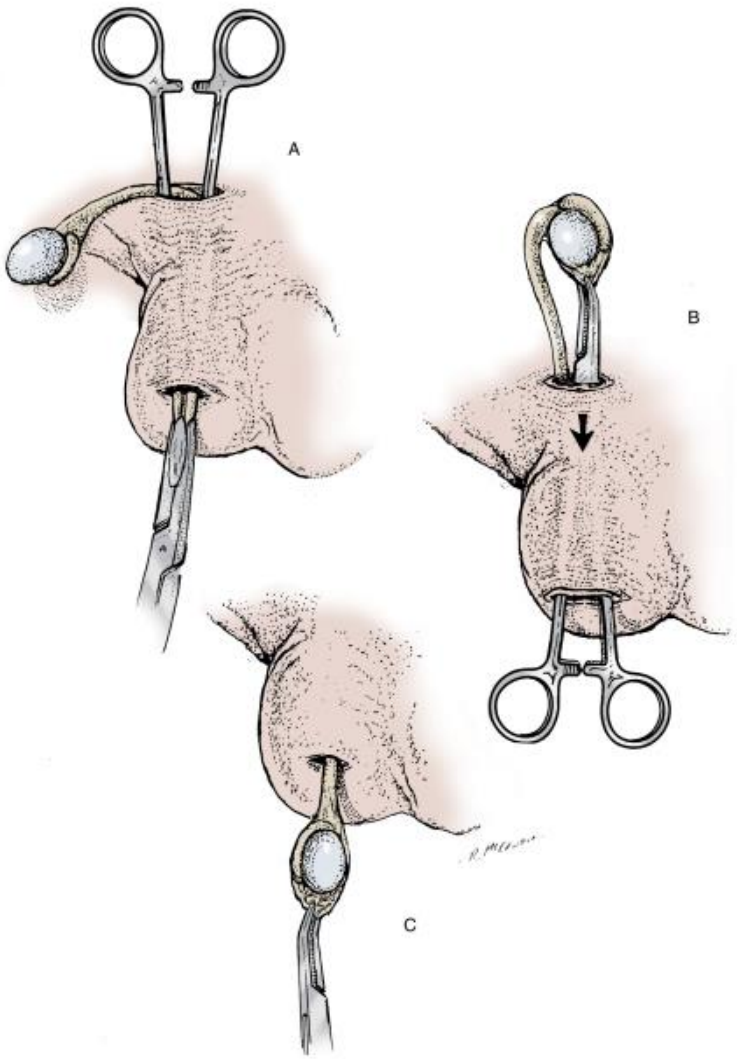

- **Techniques for High Undescended Testes:**
- **Prentiss Maneuver:**
  - Described in 1960.
  - Helpful in adding length to the spermatic vessels by positioning the spermatic vessels medially.
  - Performed by incising the floor of the inguinal canal through the external ring and dividing the inferior epigastric vessels.
  - Passing the testis under the floor of the inguinal canal to an exit site just above the pubic tubercle.
  - The internal ring and transversalis fascia are then closed lateral to the cord.

- A two stages orchiopexy can be performed if anatomic conditions prevent adequate spermatic vessel length from being achieved during primary orchidopexy, the testis is anchored to the external ring or pubic symphysis after maximal mobilization in the first stage, and a second procedure is performed 6 to 12 months later.

- **Fowler-Stephens Orchiopexy**:
- Normally, the testis has three sources of arterial blood supply, the testicular artery (primary), the deferential artery of the vas deferens and the cremasteric arteries.
- Fowler and Stephens devised a means to repair a high undescended testis and preserve its blood supply via collateral circulation.
- The technique described by Fowler and Stephens was originally a one-stage procedure, but it may also be performed in two stages.
- Procedure:
  - High transverse inguinal incision is made.
  - External oblique fascia is opened.
  - Inguinal canal are examined for hernial sac.

- Anterior abdominal muscles are opened to expose the peritoneum, which is then opened.
- Identify and mobilize the testes without transecting any proximal structures.
- Inspection of the primary and collateral vessels as well as the course of the vas deferens.
- Fowler-Stephens test performed by temporarily occluding the testicular artery with a vascular clamp for 5 minutes and inspecting the testis for color, as well as making a small incision in the tunica albuginea of the testis to document arterial bleeding.
- If the blood supply at this point considered tenuous, a two-stage repair should be performed to allow for development of the collateral circulation.

- If the testis appears viable, the testicular artery is ligated and divided high above the testis.
- Testis is then mobilized .
- An incision is made in the lateral peritoneal reflection, and the peritoneum medial to the testis is left undisturbed.
- Prentiss maneuver may be used.
- Standard orchiopexy.

- The advantages of a two-stage orchiopexy:
  - Allow for development of collateral blood supply.
  - Allow for greater mobility of the testis to place it within the scrotum.

- **Laparoscopic orchidopexy**
  - Diagnostic and therapeutic
    - Radmayr et al JUrol 2003.
- **Microvascular Autotransplantation**
  - Before surgery, hCG or testosterone can be given to increase vascular caliber.
  - Procedure is performed through a **Gibson incision.**
  - Donor vessel preparation requires 1 to 3 cm of the vessel to be dissected free of surrounding tissue for anastomosis of the spermatic vessels to the ipsilateral inferior epigastric artery and vein by a microvascular techniques.
  - Fixation of the testis in the scrotum is performed .
  - Doppler ultrasound or radioactive isotope perfusion scanning can be used postoperatively to determine patency of the anastomosis.

- **Reoperative Orchiopexy**
  - Performed in cases of secondary cryptorchism after orchiopexy or inguinal hernia repair.
  - Skin incision and initial exposure should be in a previously non operated area.
  - Dissection to free the testes.
  - Careful mobilization of the spermatic cord.
  - Mobilize the cord proximally above the internal ring to gain length may be necessary.
  - Standard orchiopexy can then be applied.

- **Complications of Orchiopexy:**
  - Testicular retraction.
  - Hematoma formation.
  - Ilioinguinal nerve injury.
  - Postoperative torsion (either iatrogenic or spontaneous).
  - Damage to the vas deferens.
  - Testicular atrophy.

Thank You