VESICOVAGINAL FISTULA

By
Dr. Azzawi Mustafa Hadi
Assistant prof. Urology
Tikrit Medical college

Etiology

- **Traumatic:**
  - **Postsurgical: > 75 %**
    - Hysterectomy . (Abdominal or Vaginal) most common.
    - Anti-incontinence surgery.
    - Colporrhaphy.
    - Vaginal biopsy.
    - Bladder biopsy, endoscopic resection, laser procedures .
    - Pelvic surgery (e.g., vascular, rectal).
  - **External trauma (e.g., penetrating, pelvic fracture, sexual)**

- Radiation therapy.(external beam and interstitial)
- Advanced pelvic malignant disease. (cervical, vaginal, and endometrial carcinomas, about 3-5%)
- Infectious or inflammatory.
- Foreign body.
- Obstetric :
  - Obstructed labor. (ex: CPD)
  - Forceps laceration.
  - Uterine rupture. (22% associated with bladder injury)
  - Cesarean section.
- Congenital.

Risk Factors

- **Intraoperative injury to the urinary bladder .**
- **Prior uterine surgery (cesarean section).**
- **Endometriosis.**
- **Infection.**
- **Diabetes.**
- **Arteriosclerosis.**
- **Pelvic inflammatory disease.**
- **Prior radiation therapy.**
- **Operative approach to hysterectomy. (three times more common during abdominal hysterectomy compared with vaginal hysterectomy).**

Evaluation

- **Presentation:**
  - Constant urine drainage per vagina: most common, amount can vary from patient to patient.
  - Recurrent cystitis.
  - Perineal skin irritation.
  - Vaginal fungal infections
  - Pelvic pain. rarely

- **Examination:**
  - **Vaginal bivalved speculum.**
    - Most commonly, VVFs after hysterectomy are located along the anterior vaginal wall at the level of the vaginal cuff.
  - **Palpation for masses or other pelvic disease.**
  - **Notation of prior incisions in the perineum, lower abdomen, and thigh is necessary.**
  - **Vital blue dye and Pad test.**

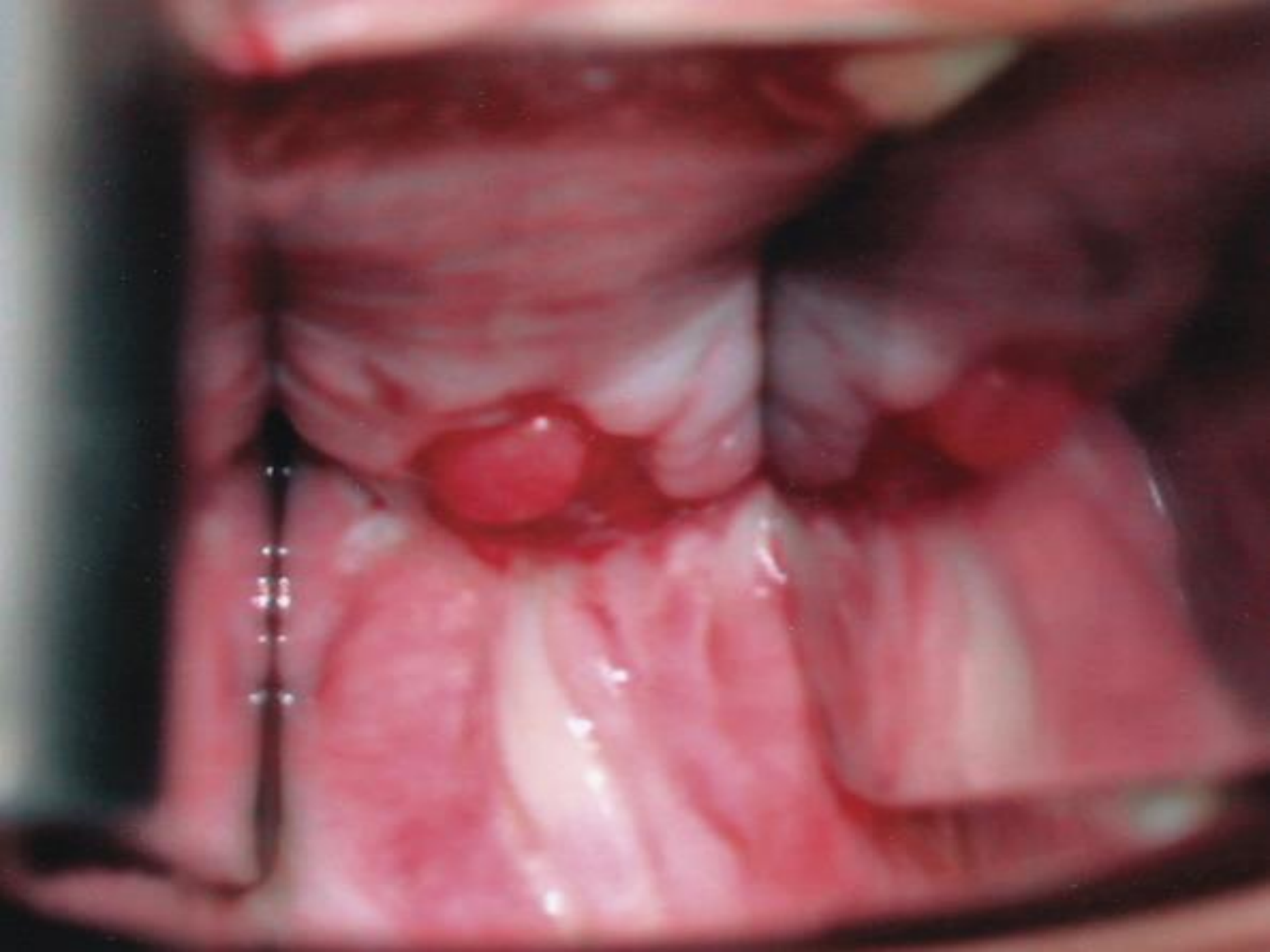

- **Double dye or tampon test:**
  - Tampon is placed per vagina.
  - Oral phenazopyridine is administered
  - Vital blue dye is instilled into the bladder.
  - If the tampon is discolored yellow-orange at the top, it is suggestive of a ureterovaginal fistula.
  - Blue discoloration in the midportion of the tampon suggests VVF.
  - Blue staining at the bottom suggests a urethrovaginal fistula.
- **Clear vaginal discharge after hysterectomy does not invariably represent a urinary tract fistula or incontinence, it may be normal vaginal secretions, less commonly peritoneovaginal fistula, lymphatic fistula, vaginitis, and fallopian tube fluid.**

- **Cystoscopy:**
  - An immature fistula may appear as an area of localized bullous edema without a distinct ostium.
  - Mature fistulas may have smooth margins with variably sized ostia.
  - Guide wire or ureteral catheter may be used to visualize the fistula tract in case of multiple pits and cavities.
  - Confirm the presence of the fistula but also may assess the size of the track, the presence of collateral fistulas, and the location of the ureteral orifices in relation to the fistula.
  - With history of pelvic malignant disease, biopsy of the fistula is done to evaluate the possibility of a recurrent malignant neoplasm.

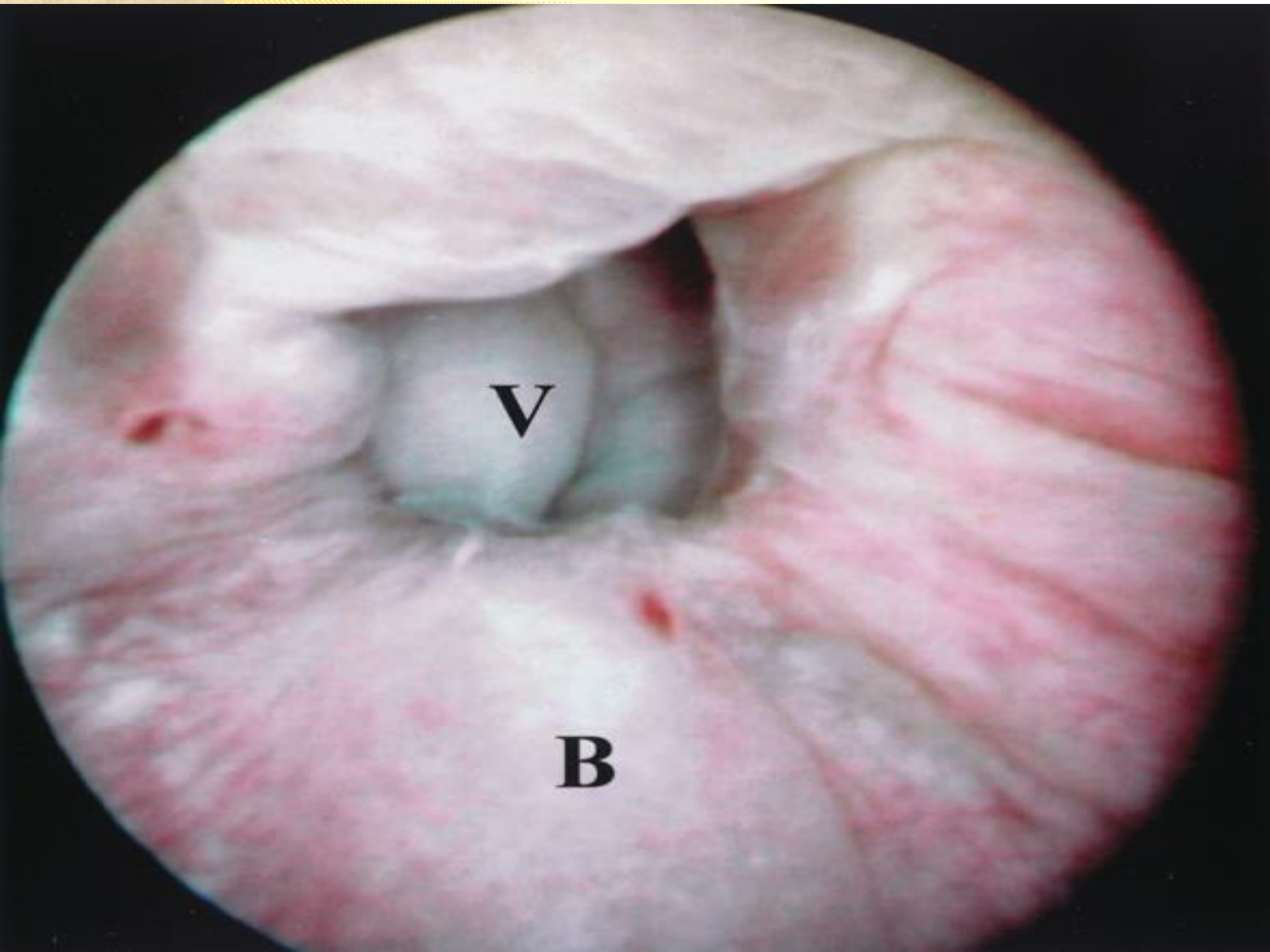
V
B

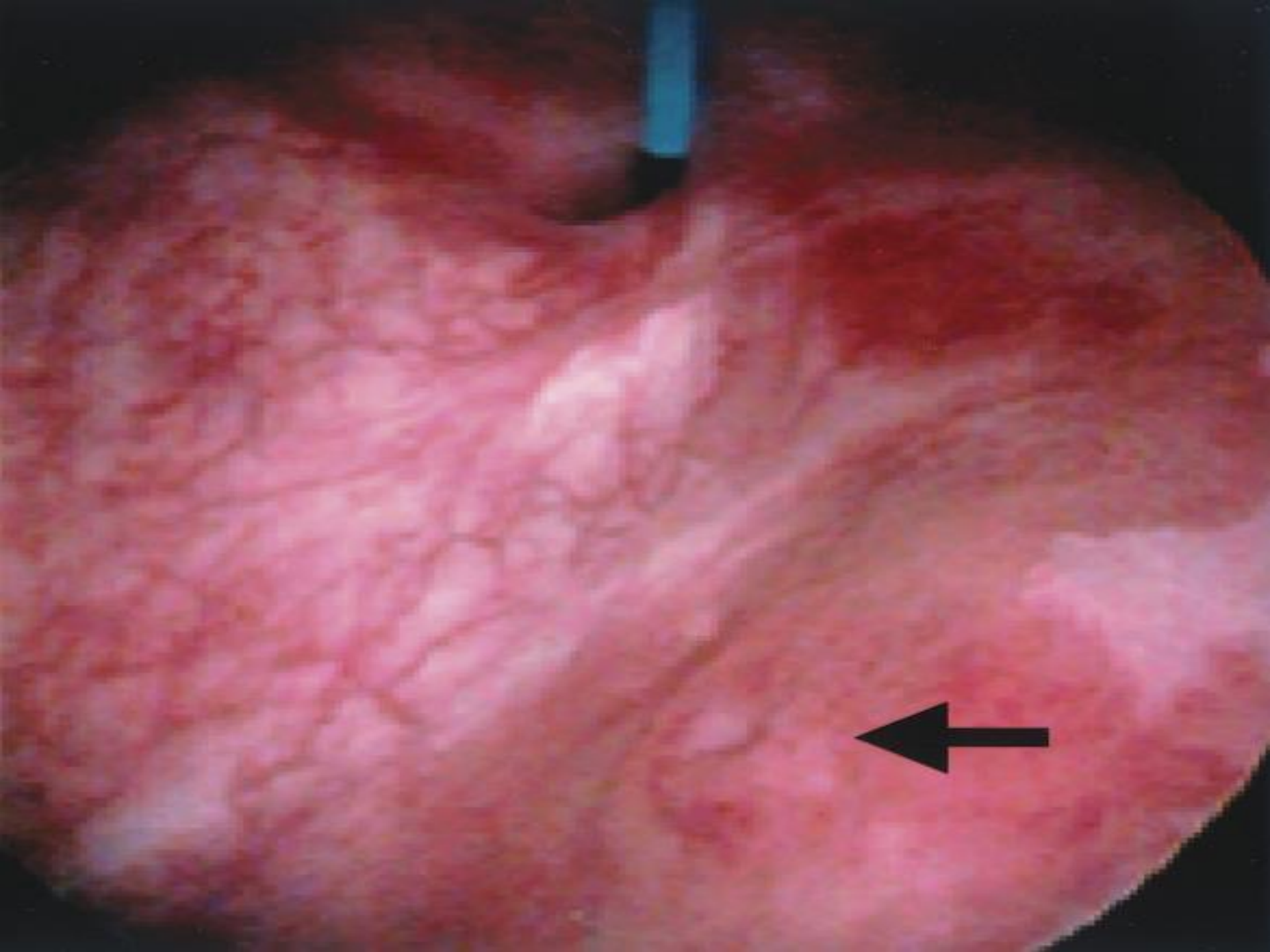

- **Imaging:**
  - **Cystography or voiding cystourethrography.**
    - May objectively determine the presence and location of the fistula.
    - Voiding images may be necessary in some patients with small fistulas to demonstrate the VVF.
    - Upper urinary tract evaluation is important because up to 12% of postsurgical VVFs have an associated ureteral injury or ureterovaginal fistula (Goodwin and Scardino, 1980).
    - Intravenous urography is usually sufficient for this purpose, but if a ureterovaginal fistula is suspected or if the distal ureter is not well seen on intravenous urography, retrograde pyelography may be performed.

R
25
A

R
25
B

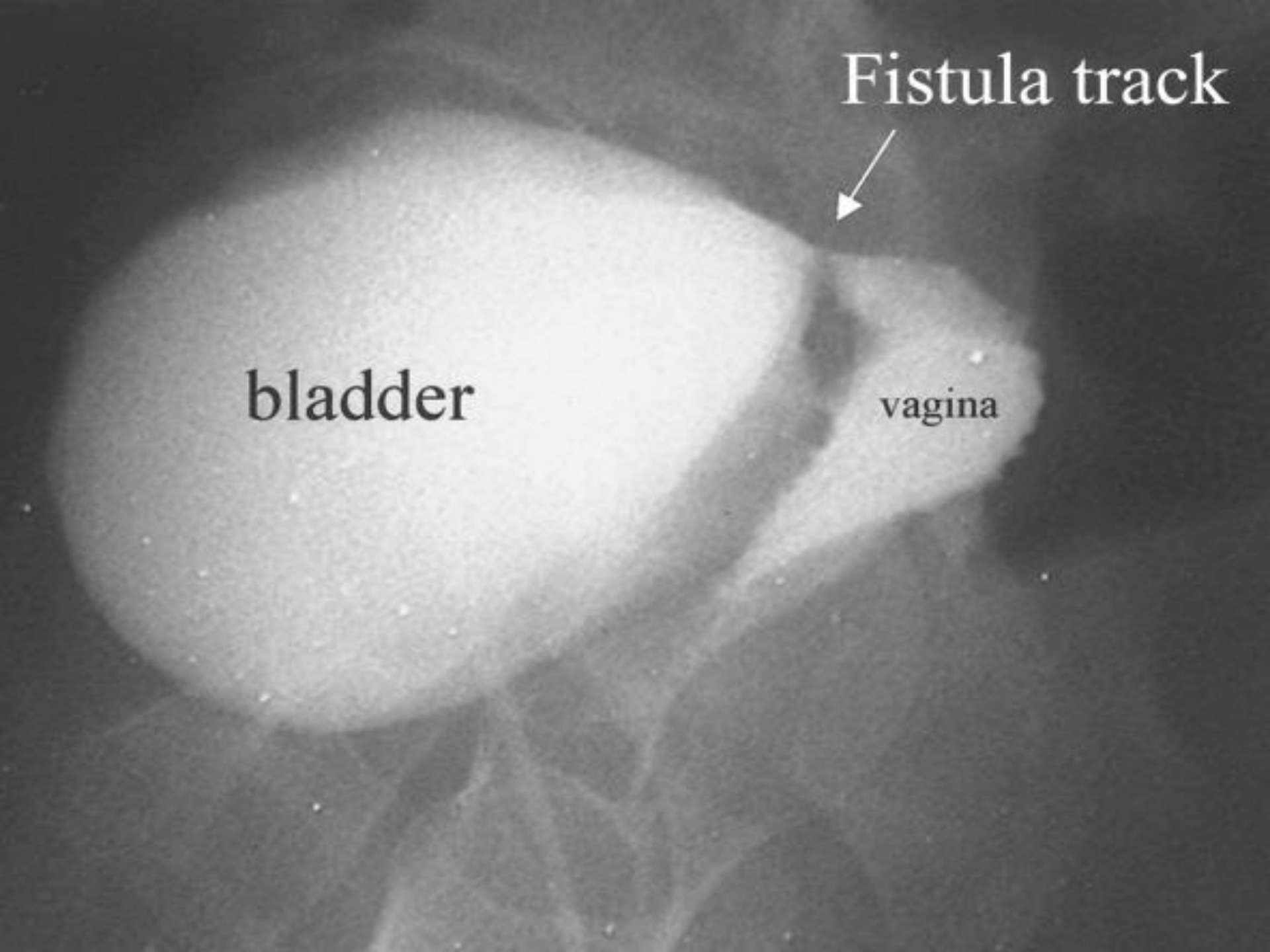
Fistula track
bladder
vagina

- **Computed tomography.**
  - Delayed CT visualization of contrast material within the vagina is considered highly suggestive of VVF in the majority of cases.
  - Cross-sectional imaging may also be helpful in assessment for recurrent malignant disease.
- **Ultrasonography.**
- **Magnetic resonance imaging.**
- **Other studies:**
  - Urine culture.
  - Cytological analysis.
  - Urodynamic evaluation in patient with history of significant symptoms of voiding dysfunction and incontinence preceding the VVF.

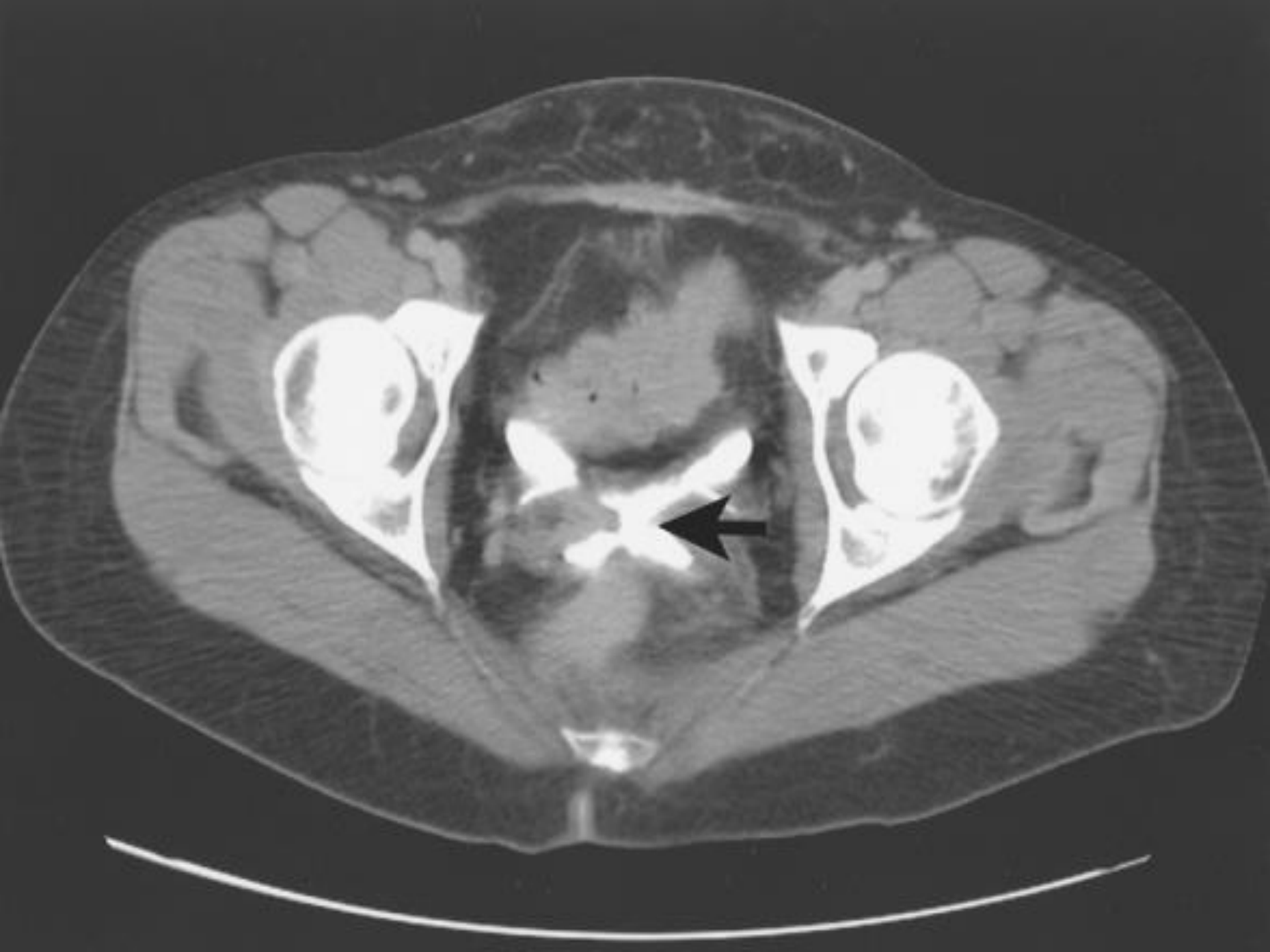

Treatment

- **Conservative measures:**
  - Useful for small, oblique fistulas, usually less than 2 or 3 mm in diameter.
  - **Indwelling catheterization:** for at least 2 to 3 weeks.
  - Especially applicable in those patients in whom the initial placement of the catheter immediately resolves the vaginal leakage.
  - Fistulous tracks that remain open 3 weeks or more after adequate catheterization are unlikely to resolve without further intervention, especially those that appear completely epithelialized on examination.

- **Minimally invasive treatment :**
  - **Curettage** of the fistula track with an ordinary screw followed by prolonged catheterization has been reported to be successful.
  - **Electrocoagulation** of the fistula track combined with catheterization, it exert its favorable effects by disruption of the epithelial component of the VVF track with subsequent fibrosis, scarring, and closure of the track.
  - **Fibrin sealant :** a gel-like material may be injected directly into the fistula track after fulguration followed by catheterization which plugs the hole until tissue ingrowths occurs from the edges of the fistula.

- **Surgical Repair:**
  - Repair of VVF should be as expeditious as possible to minimize the patient's suffering.
  - Generally accepted that VVF resulting from obstructed labor should be associated with a 3 - 6 month delay before definitive repair.
  - For radiation-induced fistulas, 6 -12 months have been advocated .
  - Uncomplicated postgynecologic urinary tract fistulas may be repaired as soon as they are identified and confirmed.
  - Vaginal approach can be attempted as soon as 2 to 3 weeks after the initial injury .

- **Vaginal Techniques:**
- **Vaginal Flap:**
  - Can be performed as an outpatient procedure.
  - Applicable to most simple, uncomplicated VVFs.

- **Steps:**
- Positioning:
  - Lithotomy.
- Preparation:
  - Surgical solution.
  - Vaginal speculum.
  - Suprapubic tube.
  - Cystoscopy.
  - Silk labial retraction sutures
  - Ring retractor with hooks.
  - Foley catheter.
  - Ureteral catheters.

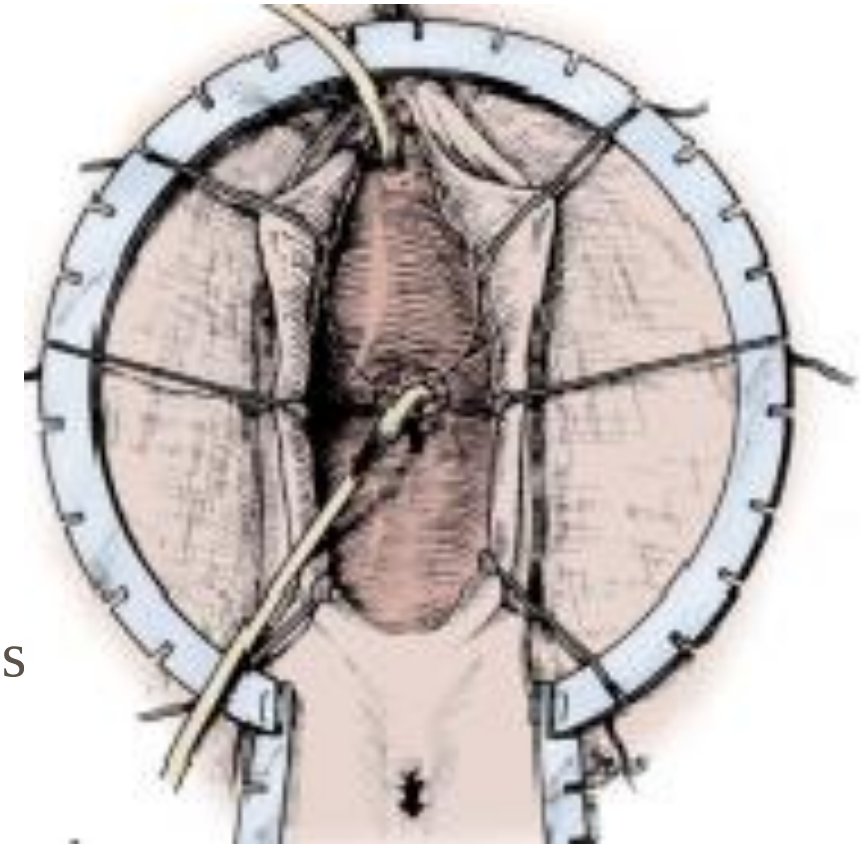

- Incision:
  - Fistula track is cannulated.
  - Marking the vaginal flap.
  - Saline injection.
  - Fistula track is circumscribed
  - U-shaped incision.
  - Circumscribed fistula is incorporated into the curved portion of the incision.

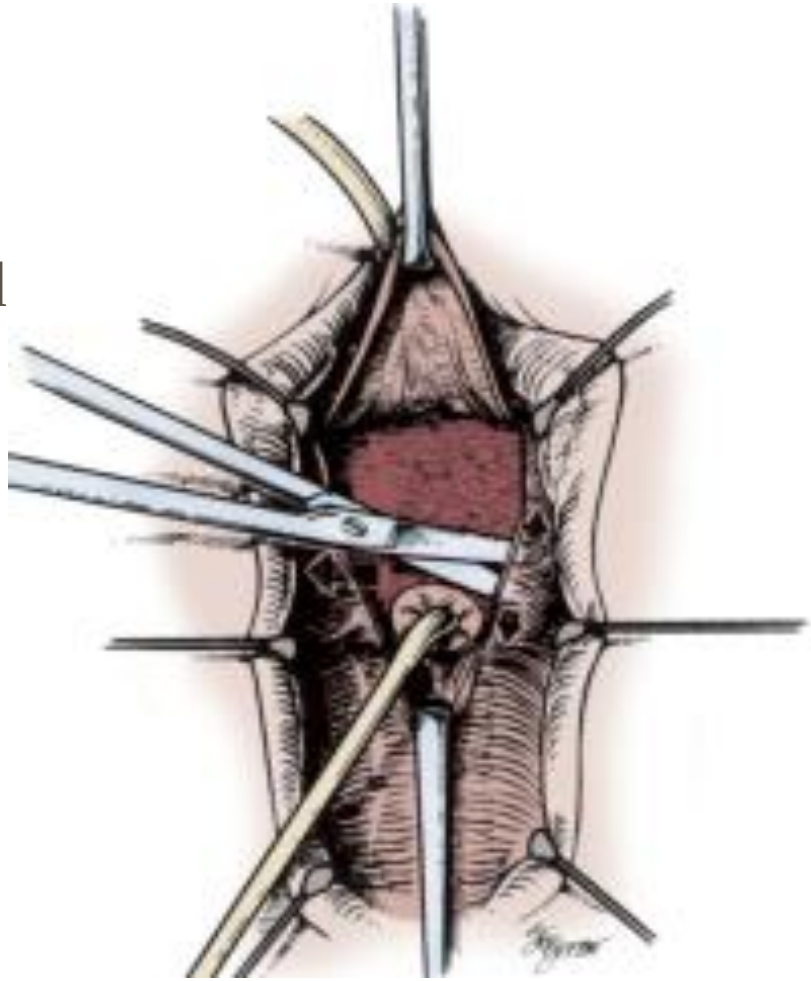

- development of vaginal wall flaps:
  - Dissection away from the incision.
  - Mobilization of the vaginal wall.

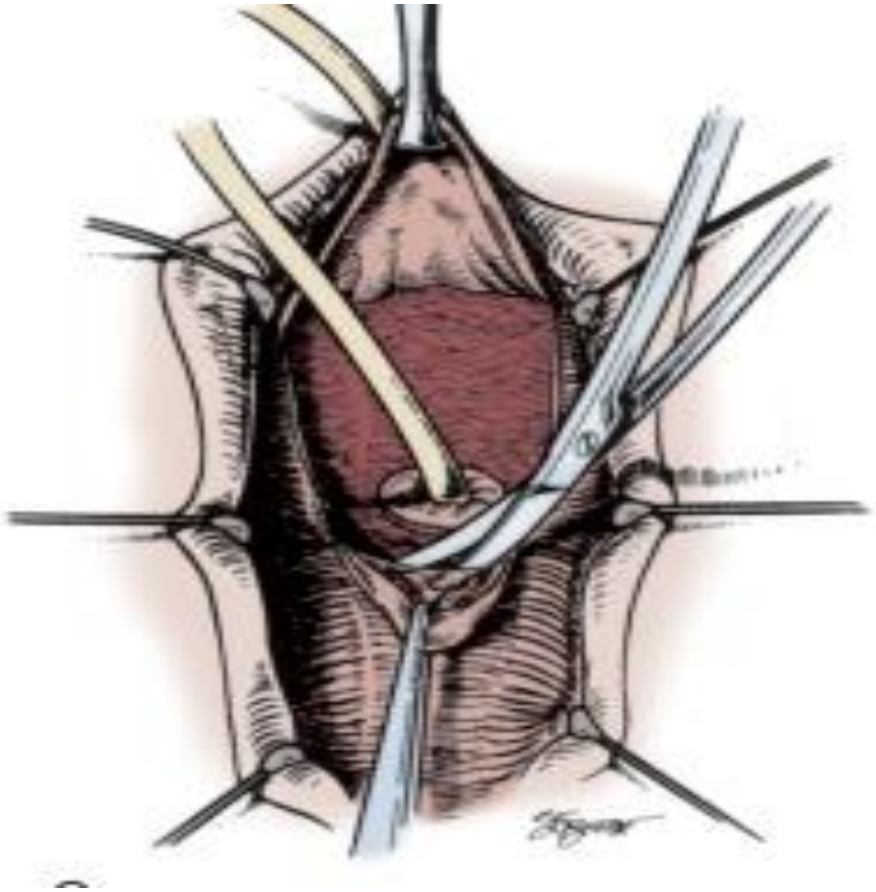

- Fistula closure:
  - Catheter is removed.
  - First layer of the repair is performed.
  - Second layer is performed to invert the 1st layer.
  - Confirm the integrity of repair.

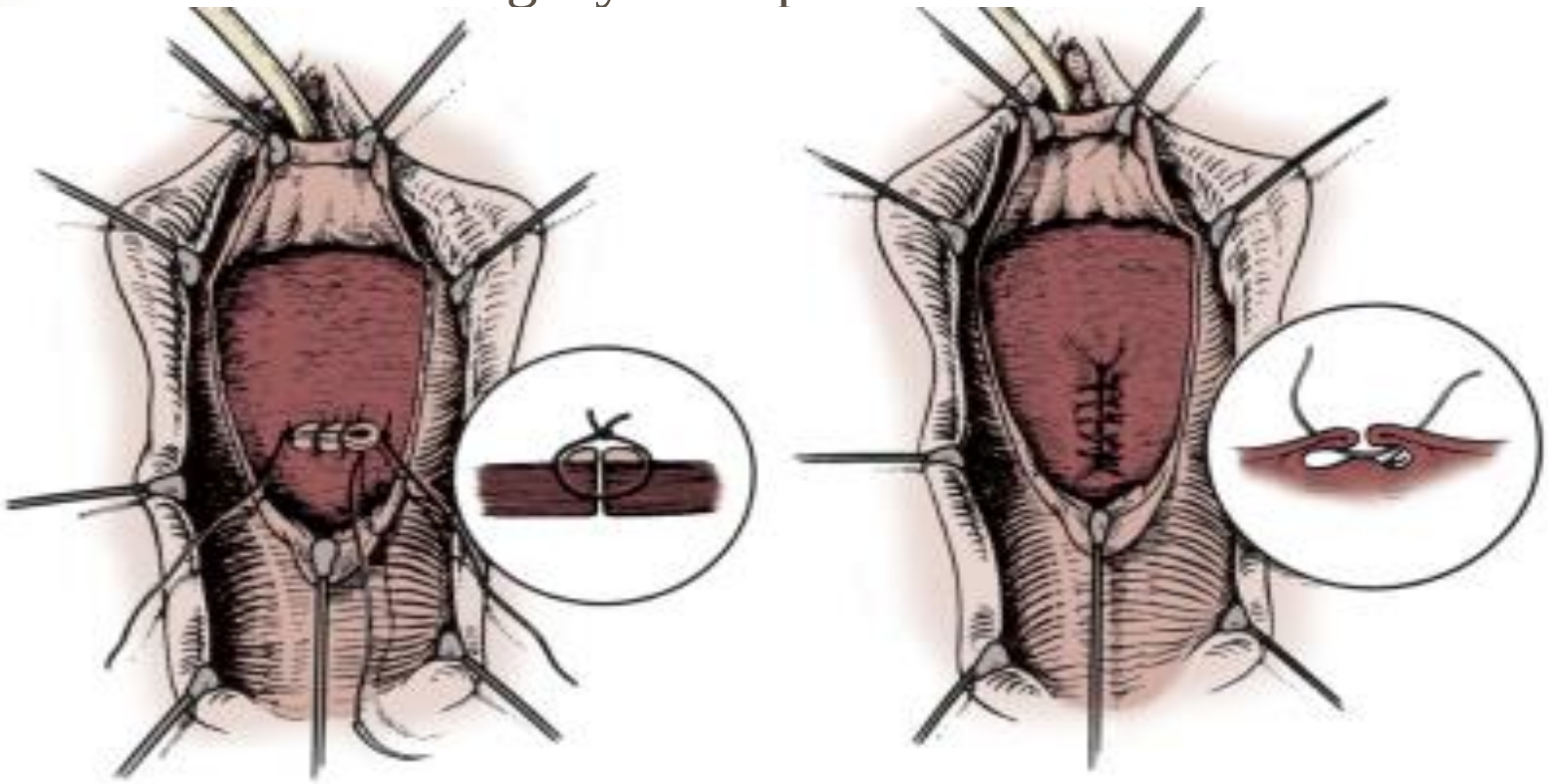

- Advancement and closure of vaginal wall flap.
- Closure of the vaginal wall.
- Vaginal packing is placed for 24 hr postoperatively.
- Urethral Foley and suprapubic catheters are left to drainage for 10 - 14 days until cystography confirms successful repair of the fistula.

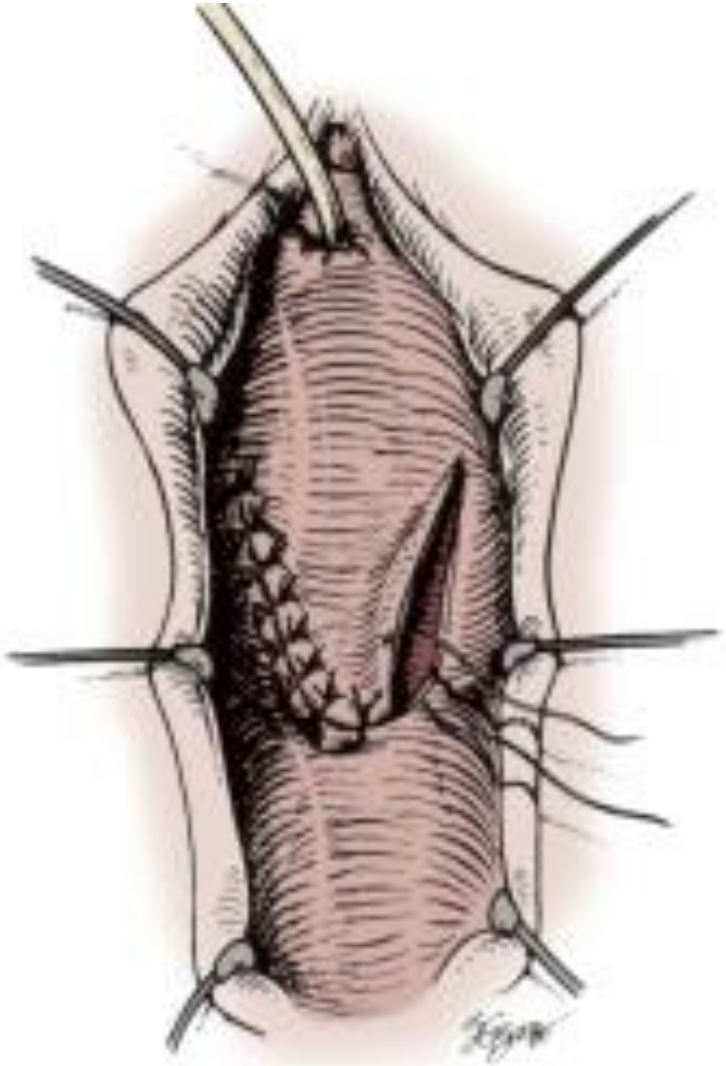

- **Other Transvaginal Techniques:**
- Latzko technique:
  - Success rates in excess of 90%.
  - Fistula track is isolated and the tissue surrounding the VVF track is denuded of vaginal “epithelium” circumferentially for a distance of 1 to 2 cm.
  - Denuded areas are then reapproximated over the fistula track.
  - Edges of the vaginal wall are then reapproximated as a second layer.
  - Advantages : minimal blood loss, no need for ureteral reimplantation .
  - Disadvantages : possibility of vaginal shortening , directly overlapping suture lines.

- **Advantages of a Transvaginal Approach:**
  - Avoidance of a laparotomy and its associated morbidity.
  - Short operative time.
  - Brief inpatient stay.
  - Quick convalescence and return to normal activities.
  - Minimal postoperative pain.
  - Minimal blood loss.
  - Approach is not compromised by multiple prior abdominal or pelvic surgeries.
  - Concomitant anti-incontinence or prolapse surgery may be performed.
  - If failure occurs, a subsequent abdominal approach is not compromised.

- **Disadvantages of a Transvaginal Approach:**
  - Recurrence of the fistula.
  - The possibility of ureteral injury is concern if the VVF is adjacent to the insertion of the ureter.
  - vaginal shortening and stenosis. (long term).

- **Abdominal Techniques:**
- **Transabdominal** repair is the preferred approach in those cases requiring augmentation cystoplasty or ureteral reimplantation.
- Compared with the vaginal approach, the abdominal approach to VVF repair is associated with :
  - Longer recovery time
  - Long inpatient hospitalization.
  - Greater blood loss.
  - More cosmetic deformity.
  - In general, greater morbidity.

- **Suprapubic Intraperitoneal-Extraperitoneal Approach:**
  - The bladder opened and bivalved down to the level of the VVF.

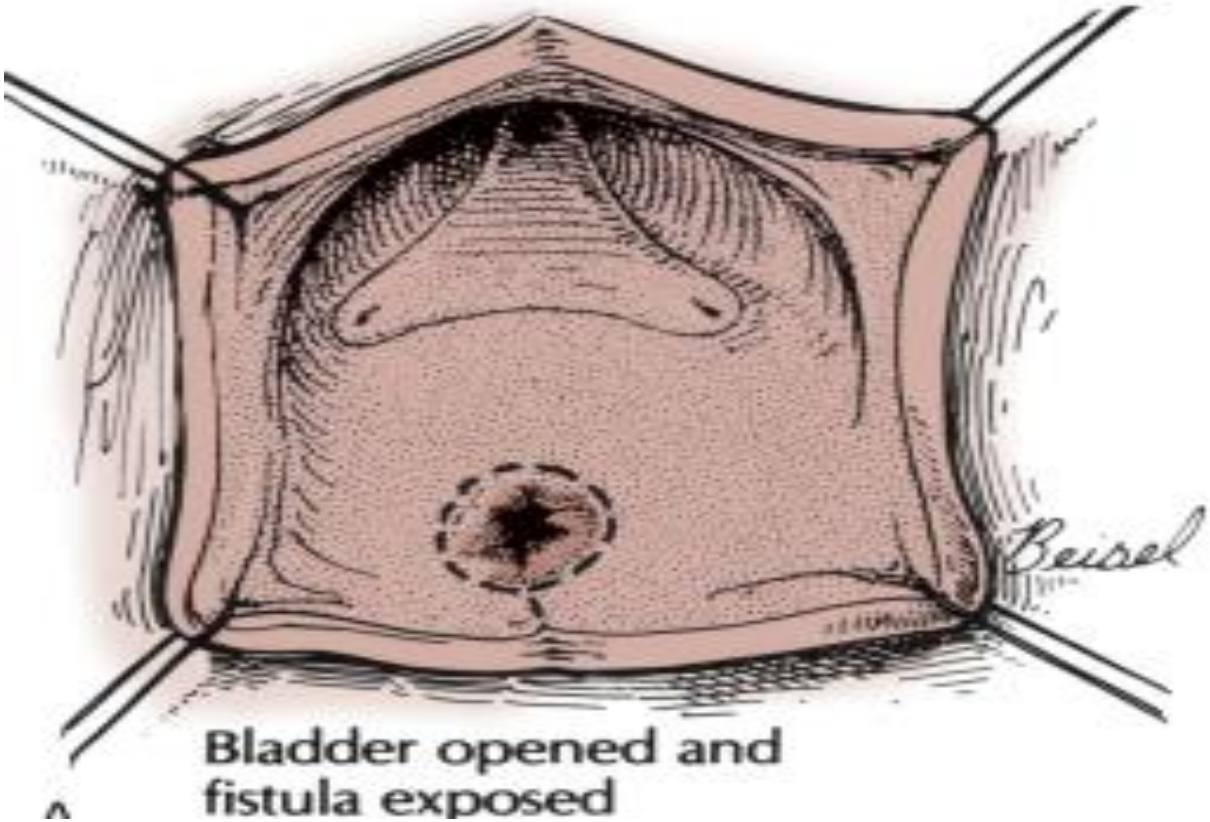

- The VVF track is excised.

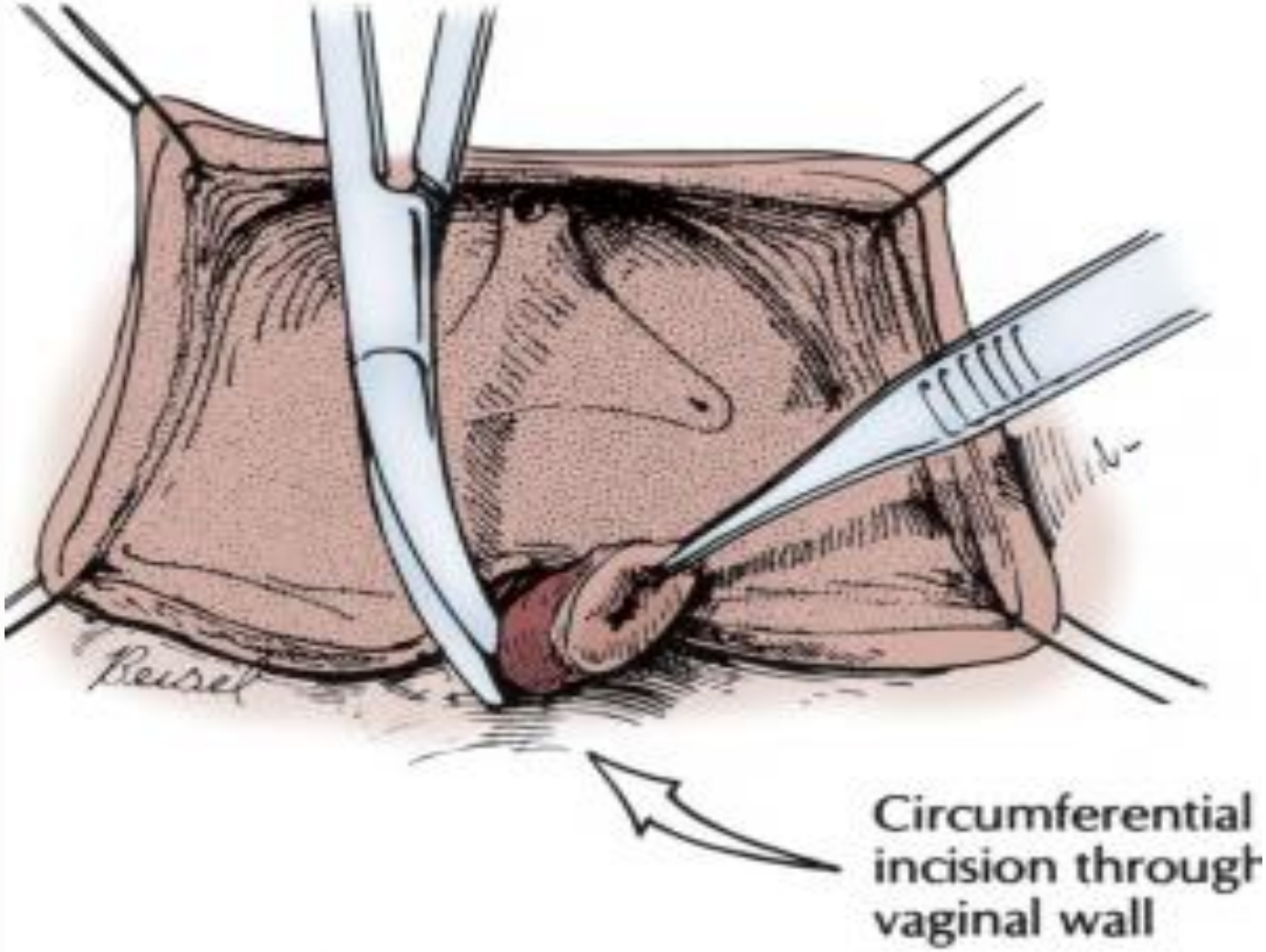

- Dissection and separation of the vagina.
- Closure of the vagina.
- Closure of the bladder.

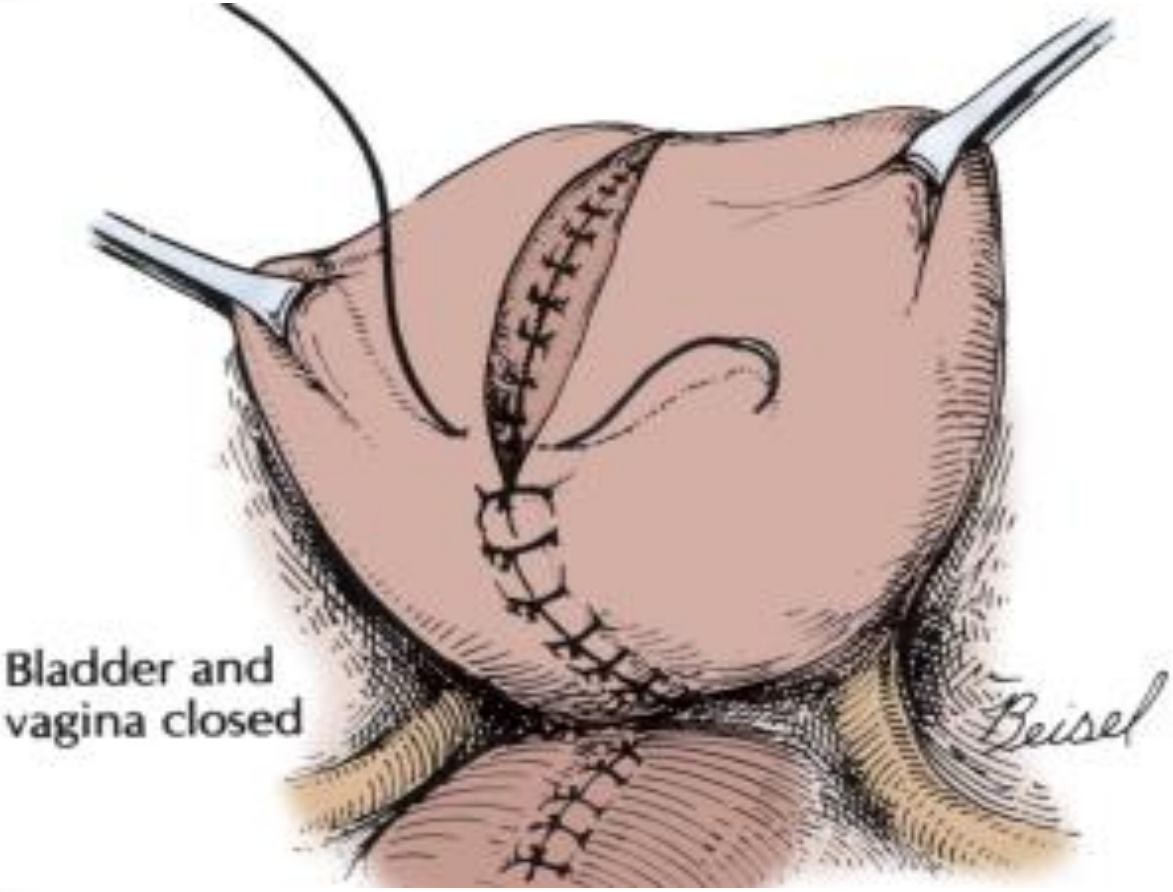

- Omentum is interposed between the bladder and vaginal closures.

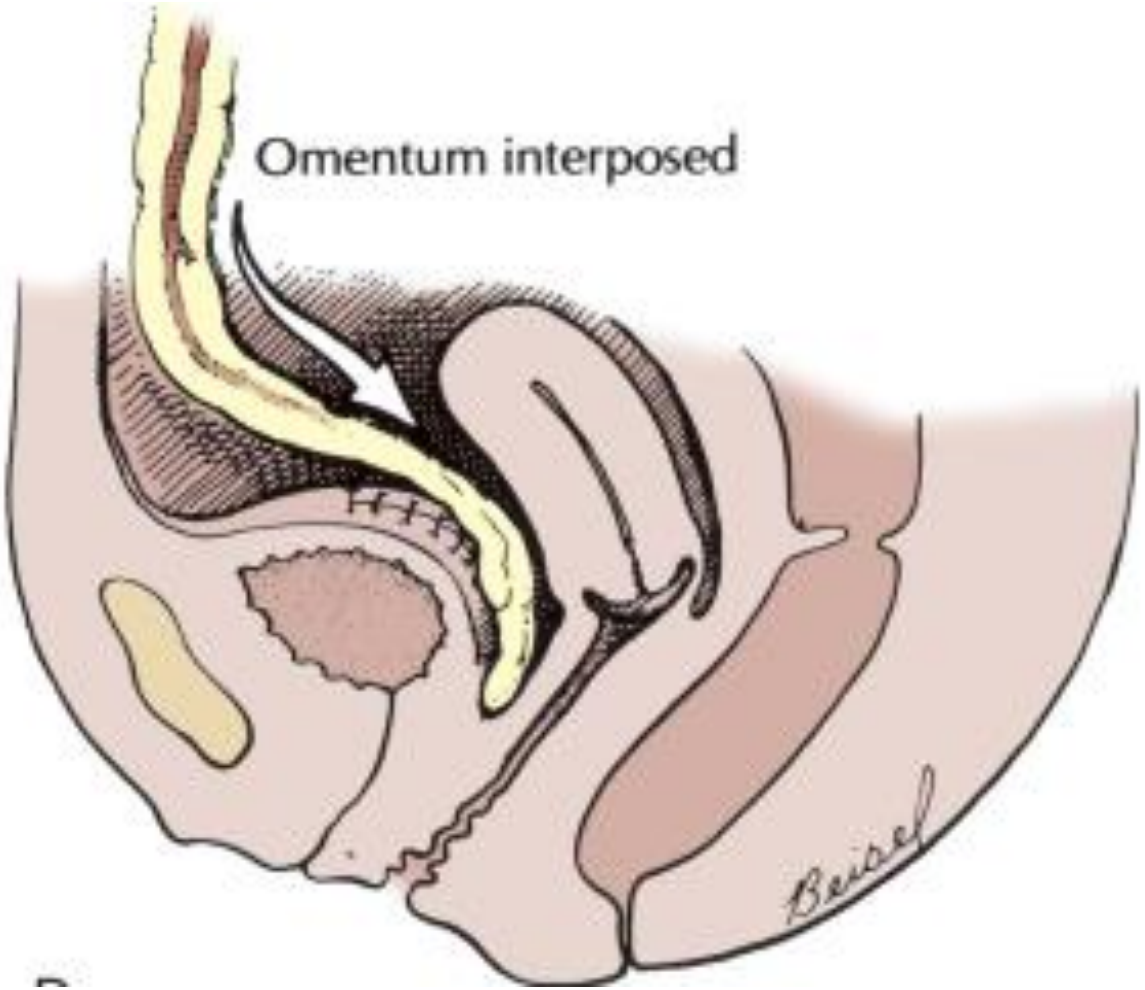

- **Suprapubic transvesical approach:**
  - Bladder is opened through a vertical cystotomy but is not bivalved down to the VVF track.
  - The VVF track is circumscribed and excised transvesically.
  - The vaginal edges are then carefully mobilized from the bladder.
  - The vagina and bladder are closed sequentially.
  - V-shaped flap of adjacent posterior bladder wall may be brought down as a flap to close a large gap or to minimize overlapping suture lines.
  - This approach has been successful in both simple and complex fistulas

- **Other Techniques for VVF Repair:**
  - Laparoscopic approaches.
  - Laser tissue welding.
  - Transurethral endoscopic suturing.
- **Adjuvant Techniques:**
  - **Tissue Interposition.**
  - Tissue flaps are especially helpful in**:**
    - Recurrent fistula.
    - Fistula related to previous radiotherapy.
    - Ischemic or obstetric fistula.
    - Large fistula.
    - Fistula associated with a difficult or tenuous closure because of poor tissue quality.

- **Martius Flap:**
- The fibrofatty labial flap was first described by Heinrich Martius in 1928.
- For low or distal fistulas.
- This flap consists of adipose tissue and connective tissue.
- Is the preferential tissue for fistulas involving the trigone, bladder neck, and urethra.
- The blood supply to the flap is provided inferiorly by the internal pudendal artery, superiorly by the external pudendal artery, and laterally by the obturator artery.

- **Procedure:**
- Incision is made over the labia majora.
- Gentle dissection to get the flap.

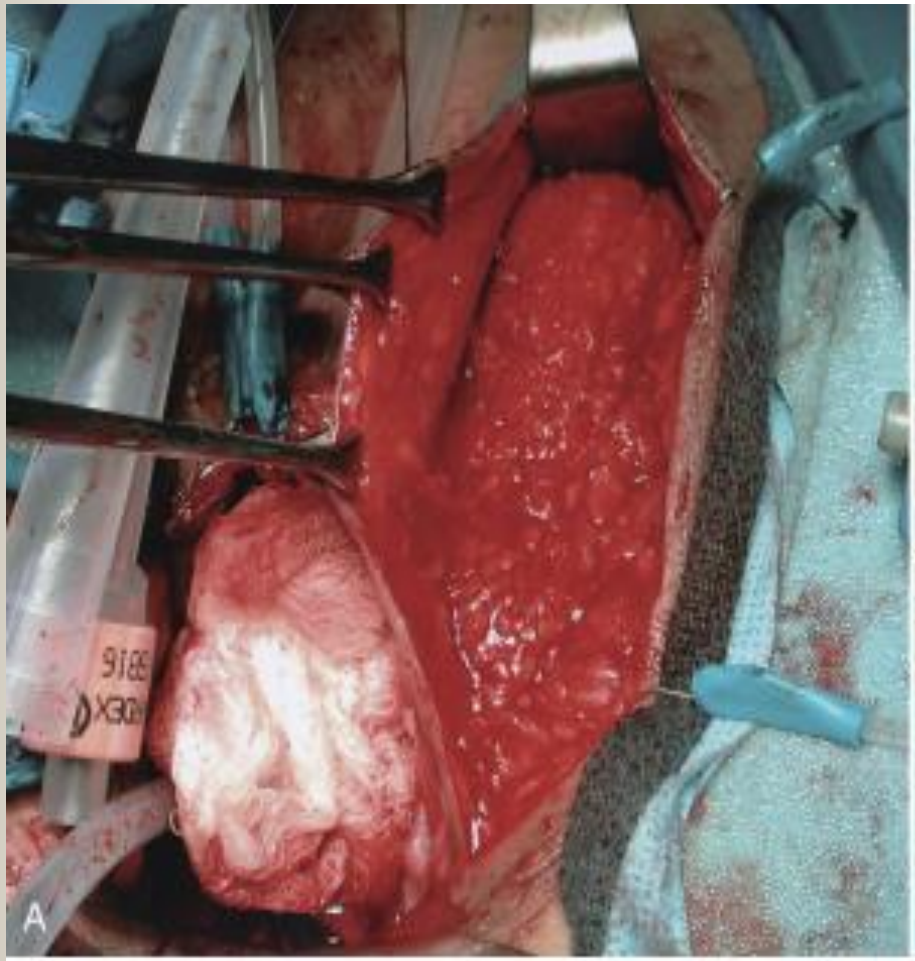

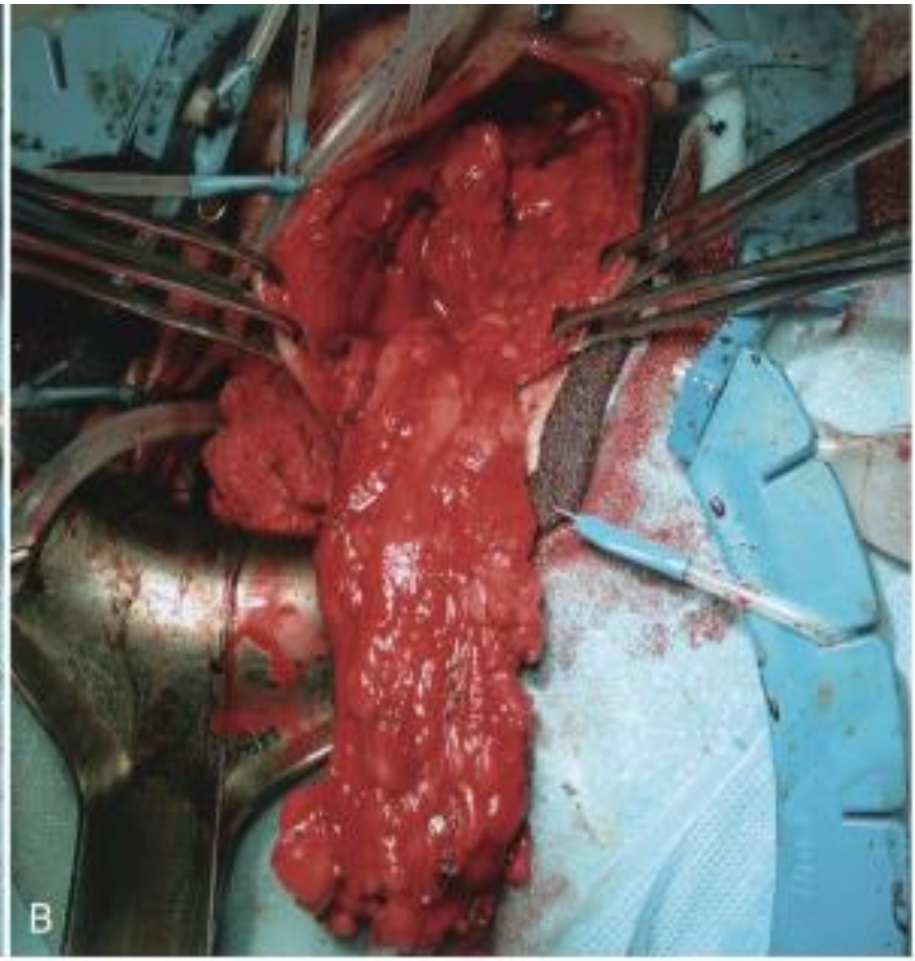

- Mobilization of the flap.
- Tunnel is developed from the labial incision to the site of the fistula repair.
- Flap is placed over the fistula repair and secured with interrupted absorbable sutures in a tension-free manner.
- Vaginal wall flap is advanced over the Martius flap and closed.
- Labial incision is closed.
- Pressure dressing applied to the labial skin incision .

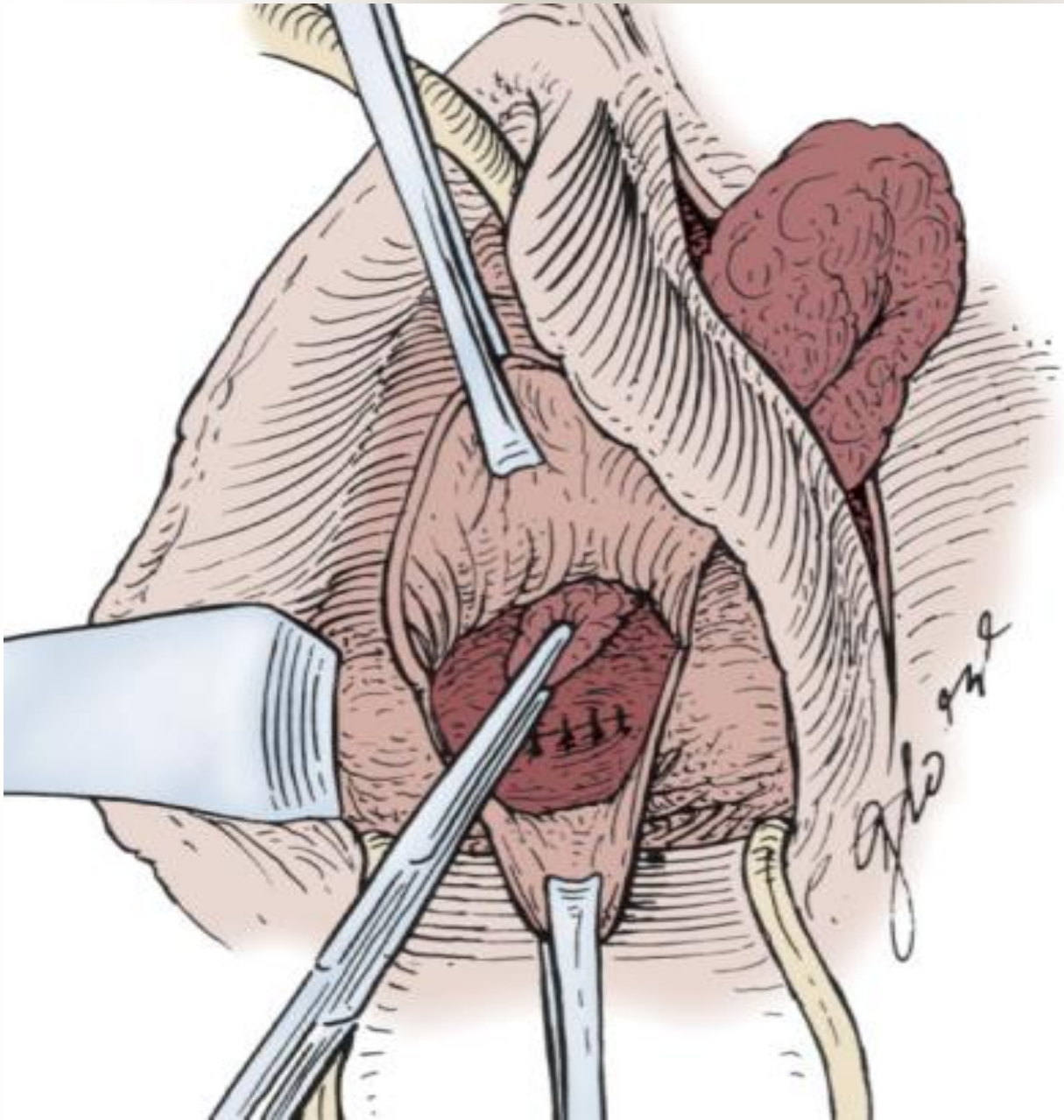

- **Peritoneal Flap:**
- This technique is primarily used in conjunction with repair of a high-lying, post-hysterectomy VVF.

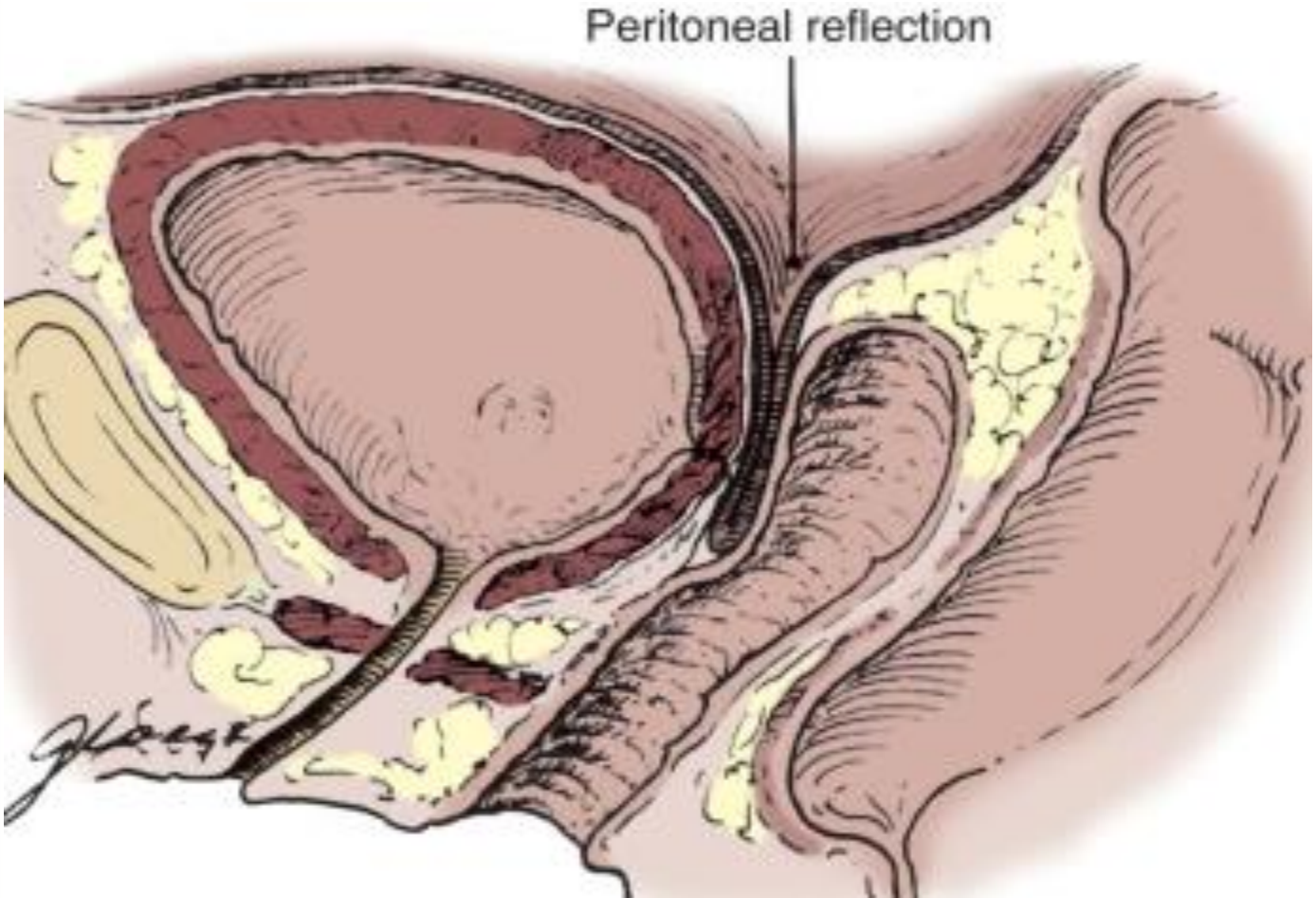

- Dissection just beyond the posterior wall of the bladder will expose the edge of the peritoneum.
- The peritoneum and preperitoneal fat are mobilized from the caudal origin of the vaginal wall flap by sharp dissection.
- The peritoneum is not opened but is mobilized and then advanced over the fistula repair.

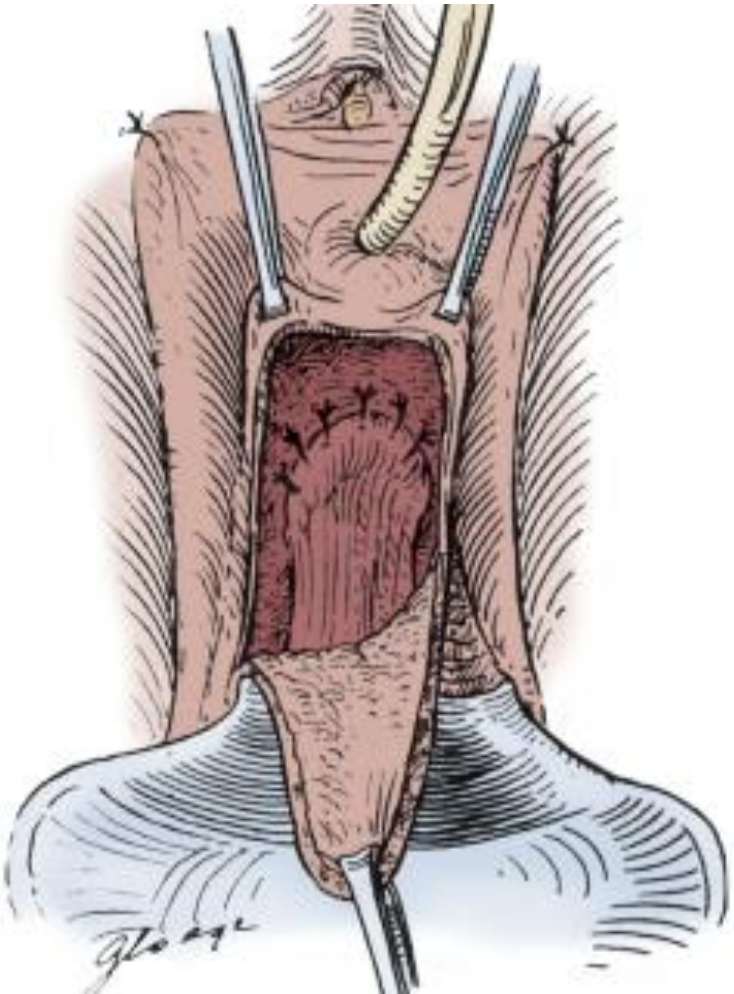

- **Greater Omentum:**
- Most commonly used during transabdominal VVF repair as an interpositional layer between the bladder and vagina.
- Has ability to be mobilized on a well-vascularized pedicle into the deep pelvis without tension, its inherent lymphatic properties, its ability to contribute to healing even in the presence of infection.
- The blood supply of the greater omentum derives principally from the right and left gastroepiploic arteries as well as the distal branches of the gastroduodenal and splenic arteries.
- The free distal end of the greater omentum is often long enough to reach into the deep pelvis tension free without any further mobilization.

- **Other Flap and Graft Techniques.:**
  - **Gracilis muscle flaps .**
  - **Labial myocutaneous flaps .**
  - **Seromuscular intestinal flaps .**
  - **Rectus abdominis flaps .**
  - **Bladder mucosa .**

Thank You