

# ***Study the protective effect of Curcuma longa rhizomes extract against the toxicity of lead acetate that induce infertility in male albino rats***

## **Study the protective effect of Curcuma longa rhizomes extract against the toxicity of lead acetate that induce infertility in male albino rats**

*Rasha SH Hussein*

*Dept of biology, College of Education, Univ. of Tikrit, Iraq*

### **Abstract**

The present study used 20 male albino rats that divide randomly to five groups (each group consist 4 rats), the first group was control group administrated only normal diet and water, the second group administrated with lead-acetate for two weeks, the third group administrated with lead-acetate for four weeks, the fourth group administrated with lead-acetate for two weeks and then, treated with 1ml rhizomes extract for 15 days, the fifth group administrated with lead-acetate for four weeks and then, treated with 1ml rhizomes extract for 15 days. the rats that administrated with lead acetate show decreased in the number of living sperms and increased the deformity of sperms with decreased the levels of LH, FSH and testosterone hormone and showed high significant changes ( $P < 0.01$ ) compared with control group, with different changes in testicular tissue, but the levels of all parameters back to normal when the groups that treated with Curcuma longa rhizomes extract. It was concluded from this study that rhizome extract has amply good effect on the fertility of male albino rats.

### **Introduction**

Curcuma longa (turmeric), a member of Zingiberaceae family, commonly known as turmeric, originate in tropical and subtropical regions of India and China [1], a yellow food color and an ingredient in curry powder, for long time has been used in Asian traditional medicine as a stomach tonic and blood purifier, and for the treatment of skin disease and wound healing [2]. Medicinal properties of Curcuma longa have been attributed primarily to

curcuminoids, which are located in the plant rhizome. Curcumin (diferuloylmethane) is the most important fraction of Curcuma longa [1]. Oral administration of rhizomes to healthy human subjects resulted in increased insulin secretion. [3] A water-soluble peptide, turmerin, has been isolated from rhizomes with antihyperglycemic properties as demonstrated by inhibition of  $\alpha$ -amylase and  $\alpha$ -glucosidase activities [4]. Human

# ***Study the protective effect of Curcuma longa rhizomes extract against the toxicity of lead acetate that induce infertility in male albino rats***

pancreatic  $\alpha$ -amylase inhibitory activity has also been demonstrated for bisdemethoxycurcumin, present in rhizomes [5]. In recent years, many studies have shown that *Curcuma longa* possesses antioxidant [6], anti-tumor [7], hepato-protective properties, intestinal worms, diarrhea, intermittent, fevers, hepatic disorders, biliousness, urinary discharges, dyspepsia, inflammations, constipation, leucoderma, amenorrhea, and colic[8-12]. So the aim of this study is to show the protective effect of *Curcuma longa* rhizomes extract against the toxicity of lead acetate that induce infertility in male albino rats

## **Materials & methods**

### ***Animal model***

twenty adult male albino rat, (wt 200-250 g) obtained from the Public company of medicines manufacture and requirements medicals - Samara, Iraq, and kept on standard pellet diet and water.

### ***Preparation of the extract***

The rhizomes of *Curcuma longa* were collected from Kirkuk market, cut into small pieces. The dried rhizome was

then grinded to obtain a fine powder. The powder was again dried and was ready for use. The grinded powder was then extracted with 1000ml double distilled water containing 3-4 drops of chloroform for 48h. The extract was then concentrated at temperature less than 45°C. The residue was then dried and refrigerated [13].

### ***Chemicals***

Lead-acetate ( $(\text{CH}_3\text{COO})_2\text{Pb} \cdot \text{H}_2\text{O}$ ) was dissolved in distilled water. Treated rats were received distilled water rich in lead acetate (2 g/l).

### ***Experimental design***

In this study 20 albino rat were used and divided for five groups (each group consist four rats) as follow:

- 1. Group A:** control group administrated with normal saline only for seven days, then killed all were euthanized at eighth day.
- 2. Group B:** administrated with lead-acetate for two weeks, and then killed.
- 3. Group C:** administrated with lead-acetate for four weeks, and then killed.

## ***Study the protective effect of *Curcuma longa* rhizomes extract against the toxicity of lead acetate that induce infertility in male albino rats***

**4. Group D:** administrated with lead-acetate for two weeks. After that, treated with 1ml rhizomes extract for 15 days, and then killed all were euthanized at sixteenth day after treatment.

**5. Group E:** administrated with lead-acetate for four weeks. After that, treated with 1ml rhizomes extract for 15 days, and then killed all were euthanized at sixteenth day after treatment.

### ***Prepare of blood solution***

Subjected mice under anesthesia then later took heart blood and put in test tubes that contain EDTA. This solution was mixed with phosphate buffer, centrifugation 2000 cycle/min for 10 min. Supernatant was taken and 1 ml distilled water added for it. LH, FSH and testosterone in blood extract were analysed with least significant difference in  $p < 0.01$ .

### ***Sperm analysis***

The epididymis was dissected out, sectioned and immediately the content of the tail of each epididymis was squeezed gently in clean watch glass, diluted 10 times with isotonic solution of sodium citrate (2.9%) at (37° C), take one drop

from isotonic solution on slide and added one drop of eosin - nigrosin stain and made smear, this technique was used for the percentage of live/dead and for morphological abnormal sperms to be counted [14]. The content of the head of epididymis was squeezed immediately in clean watch glass contained 9.8 ml. buffer formalin with 0.1 ml. eosin 5%, this was used for counting the sperm concentration using hemocytometric technique [15].

### ***Histological study***

Fresh pieces of testis from each rat was cut out rapidly, fixed in 10% formalin and then dehydrated with ascending grades of ethanol. Dehydration was then followed by clearing then tissue samples in two changes of xylene before being impregnated with three changes of melted paraffin wax, embedded and blocked out. Tissue sections thickness (5  $\mu$ m) were stained with haematoxylin-eosin [16].

### ***Microscopic study and microscopic photograph***

The microscopic investigation of testis sections involved the descriptive

## ***Study the protective effect of Curcuma longa rhizomes extract against the toxicity of lead acetate that induce infertility in male albino rats***

histology. A light microscope (Motic microscope) was used to perform the microscopic investigations of this study. Microscopic photograph was made using (Optica\Italy) microscope supplied with a special camera prepared for this purpose.

### ***Statistical analysis***

Data were analyzed statistically using a statistical Minitab program under SPSS and Microsoft Excel XP system. The data were presented in simple measure of mean  $\pm$  SD (standard deviation), minimum and maximum values. Results were analyzed statistically using Analysis of Variance (ANOVA) test, in order to evaluate the significance of variability between treated and control groups. Means of data were compared using Duncan's Multiple Range test. Probability levels of more than 0.01 were regarded as statistically non-significant, whereas values less than 0.01 were considered as significant as follows:

$P < 0.01$  highly significant [17].

## **Results**

### ***Sperm analysis***

The results of the present study showed significant changes ( $P > 0.01$ ) in number of live sperm and deformity of sperm between groups. As shown in chart (1, 2), the groups that administrated lead-acetate for two weeks and for four weeks showed significant change in number of live sperm and deformity of sperm compared with control group, but in the groups D and E, (groups that administrated with lead-acetate and treated rhizomes extract), showed non-significant changes compared with control group.

### ***Luteinizing hormone test***

The results of the present study showed significant changes ( $P > 0.01$ ) in level of LH between groups. As shown in chart (3), the groups that administrated lead-acetate for two weeks and for four weeks showed significant change compared with control group, but in the groups D and E, (groups that administrated with lead-acetate and treated rhizomes extract), showed non-significant changes compared with control group.

### ***Follicle stimulating hormone test***

## ***Study the protective effect of Curcuma longa rhizomes extract against the toxicity of lead acetate that induce infertility in male albino rats***

The results of the present study showed significant changes ( $P>0.01$ ) in level of FSH between groups. As shown in chart (4), the groups that administrated lead-acetate for two weeks and for four weeks showed significant change compared with control group, but in the groups D and E, (groups that administrated with lead-acetate and treated rhizomes extract), showed non-significant changes compared with control group.

### ***Testosterone hormone test***

The results of the present study showed significant changes ( $P>0.01$ ) in level of testosterone between groups. As shown in chart (5), the groups that administrated lead-acetate for two weeks and for four weeks showed significant change compared with control group, but in the groups D and E, (groups that administrated with lead-acetate and treated rhizomes extract), showed non-significant changes compared with control group.

### ***Histological examination***

#### ***A. Control group***

The microscope examination showed the normal structure of testis and demonstrated the seminiferous

tubules, spermatogonia, spermatid, spermatocytes and the interstitial connective tissue (Fig. 1).

#### ***B. group administrated lead acetate for two weeks***

The cross sections that prepared from this group showed damage wall of seminiferous tubules with decreased in the numbers of spermatogonia and spermatocytes and the spermatid absent in most tubules (Fig. 2).

#### ***C. group administrated lead acetate for four weeks***

The cross sections that prepared from this group showed damage wall of seminiferous tubules and the lumen of some seminiferous tubules appeared containing necrotic materials decreased in the numbers of spermatogonia and the spermatocytes absent in most tubules (Fig. 3).

#### ***D. group administrated lead acetate for two weeks and treated with rhizomes extract***

The microscope examination showed recovery of seminiferous tubules with normal spermatogenic cells which including spermatogonia, spermatid, spermatocytes and the interstitial connective tissue (Fig. 4).

## ***Study the protective effect of *Curcuma longa* rhizomes extract against the toxicity of lead acetate that induce infertility in male albino rats***

***E. group administrated lead acetate for two weeks and treated with rhizomes extract***

The microscope examination showed more recovery of seminiferous tubules with normal spermatogenic cells which including spermatogonia, spermatid, spermatocytes and the interstitial connective tissue (Fig. 5).

### **Discussion**

The results of present study show the toxicity of lead acetate on fertility of male albino rats. Where, the rats that administrated with lead acetate show decreased in the number of living sperms and increased the deformity of sperms with decreased the levels of LH, FSH and testosterone hormone and with different changes in testicular tissue. Ahmed & Karima (2012) referred that the rabbits treated with lead acetate showed increased in sperm deformity and decreased in sperm number compare with control group. Also, Leiva et al. (2011) reported a reduction in epididymal sperm number and daily sperm production in male rats treated with lead acetate and explained this reduction in sperm number that Lead

acetate administration inhibited spermatogenesis by reducing the length of the stages related to spermiation and onset of mitosis, that is in agreement with results of present study. In study carried by Biswas & Ghosh (2004) to show the effect of lead on sexual hormones in male rats, they found that the LH, FSH and testosterone levels were decreased in groups that administrated lead compare with control group. Taiwo et al. (2010) stat that the levels of LH and testosterone were decreased in male rats that administrated with lead, that is in agreement with results of present study. Histologically, Ahmed & Karima (2012) referred that the rabbits treated with lead acetate showed different lesions in testis including degenerative changes in seminiferous tubules and decreased in the numbers of spermatogenesis cells. Taiwo et al. (2010) referred that the rats treated with lead showed different changes in testis including deformities in the testis architecture with a serious damage within the somniferous tubules, that is in agreement with results of present study.

# ***Study the protective effect of Curcuma longa rhizomes extract against the toxicity of lead acetate that induce infertility in male albino rats***

The present study show the protective effect of Curcuma longa rhizomes extract against the toxicity of lead acetate on the fertility of male albino rats. Where, rats that administrated with lead acetate and treated with rhizomes extract showed a good recovery in levels of sperm count, LH, FSH, testosterone and the testicular tissues. El-Wakf et al. (2011) referred that the nitrate lead to decreased the level of testosterone and the sperm numbers with destruction the seminiferous tubules and degenerative changes in the spermatogenesis cells in male rats, but when they used Tumeric and Curcumin into treatment, they found that the level of testosterone and sperm numbers back to the normal ranges with recovery the testicular tissues. The protective effect of curcumin on the testis explained by the fact that its prevents cellular damage that occurring as a result of oxidative stress in spermatogenic cells of seminiferous tubules and leydig cells (Aly et al. 2009). That is in agreement with results of present study.

## **Reference**

1. Araújo, C. A. & Leon, L. L. (2001). Biological activities of

Curcuma Longa L. Memorias Do InstitutoOswaldo Cruz, 96 (5):723–728.

2. Pizorrone G.E. (1999). Curcuma longa (Turmeric). In: Murray MT, ed. Textbook of natural medicine. London: lingstone; 686-693.
3. Wickenberg J, Ingemansson SL, Hlebowicz J. (2010). Effects of Curcuma longa (turmeric) on postprandial plasma glucose and insulin in healthy subjects. Nutr J. 9: 43-49.
4. Lekshmi P.C., Arimboor R., Raghu K.G. & Menon A.N. (2012). Turmerin, the antioxidant protein from turmeric (Curcuma longa) exhibits antihyperglycaemic effects. J. Nat. Prod. Res., 26(17): 1654-8.
5. Ponnusamy, S., Zinjarde S., Bhargava S., Rajamohan P.R. and Ravikumar A. (2012). Discovering Bisdemethoxycurcumin from Curcuma longa rhizome as a potent small molecule inhibitor of human pancreatic  $\alpha$ -amylase, a

***Study the protective effect of Curcuma longa rhizomes extract against the toxicity of lead acetate that induce infertility in male albino rats***

- target for type-2 diabetes. J. Food Chem, 135(4): 2638-42.
6. Sewan R. and Subrana L. (1995). The antioxidant activity of Curcuma longa. J.Ethnoph., 47(2):59-67.
7. Aggrawal, B.B., Kumar A. and Phatric A.C. (2003). Anticancer potential of curcumin. J. Anticancer Res., 23(1):366-378.
8. Park, E.J, Jeon C.H. and Kong G. (2000). Protective effect of curcumin in mice liver injury induced by tetrachloride carbon. J. pharm. pharmacol 52:437-440.
9. Nelson, S.D. (1990). Molecular mechanisms of the hepatotoxicity caused by acetaminophen. J. Semin Liver Dis., 10: 267-278.
10. Lin, S.C. (1996). Protective and therapeutic effect of Curcuma longa on B-D-Galactoseamin induced liver damage. J. Pharm. Res., 10(2):131-135.
11. Ready, A.C. and Lokesh B.R. (1999). Effect of curcumin on iron-induced hepatotoxicity in rats. J. Toxicol., 107(1):39-45.
12. Jagetia, G.C. and Aggarwal, B.B. (2007). "Spicing Up" of the Immune System by Curcumin. J. Clin. Immunol., 27: 19-35.
13. Nilanjana, D. Purba M. and Ajoy K. G. (2013). Pharmacognostic and Phytochemical Evaluation of the Rhizomes of Curcuma longa Linn. J. Pharma. Sci. Tech. 2(2):81-86.
14. Alsadi, A.A. (2001). Fertility and Artificial Insemination. 2nd ed College of Veterinary Medicine, University of Mosul.
15. Bearden, H.J., Fuguan T.W. and Willard S.T. (2004). Applied animal reproduction. 6th ed Mississippi State University.
16. Bancroft, J.D. and Stevens, A. 1987. Theory and practice of histological techniques. Edinburgh: Churchill Livingstone. Pp: 482-502.
17. Beth, D.; Robert, G. and Trapp. (2004). Basic and clinical biostatistics, 4th ed. Lange Medical Books/ McGraw-Hill Medical Publishing Division. New York. PP: 83-154.



***Study the protective effect of Curcuma longa rhizomes extract  
against the toxicity of lead acetate that induce infertility in male  
albino rats***

18. Ahmed, Y.F. and Karima G.H.M. (2012). Some Studies on the Toxic Effects of Prolonged Lead Exposure in Male Rabbits: Chromosomal and Testicular Alterations. J. Global Veterinaria. 8 (4): 360-366.
19. Leiva, K.P., J. Rubio, F. Peralta and G.F. Gonzales (2011). Effect of Punicagranatum (pomegranate) on sperm production in male rats treated with lead acetate. J. Toxicol Mech Methods, 21: 495-502.
20. Biswas N.M. Ghosh P. (2004). Effect of lead on male gonadal activity in Albino Rats. J. Medical. 2(1): 43-46.
21. Taiwo, A.M., S.O Ige and O.O. Babalola. (2010). Assessments of Possible Gonadotoxic Effect of Lead on Experimental Male Rabbits. J. Global Veterinaria 5 (5): 282-286.
22. El-Wakf, A. M.; EL-Said M. E., Waffa M. and Eman A. (2011). Use of Tumeric and Curcumin to Alleviate Adverse Reproductive Outcomes of Water Nitrate Pollution in Male Rats. J. Nature and Science. 9(7): 229-239.
23. Aly, H.A.A., Mansour, A.M., Abo-Salem, O.M., Abd-Ellah, H.F. and Abdel-Naim, A.B. (2009). Potential testicular toxicity of sodium nitrate in adult rats. J. Food Chem. Toxicol., 48: 572-578.

***Study the protective effect of Curcuma longa rhizomes extract against the toxicity of lead acetate that induce infertility in male albino rats***

دراسة التأثير الوقائي لمستخلص جذيرات نبات الكركم ضد سمية خلاص الرصاص التي تحت على

العقم في ذكور الجرذان البيض

رشا شامل حسين

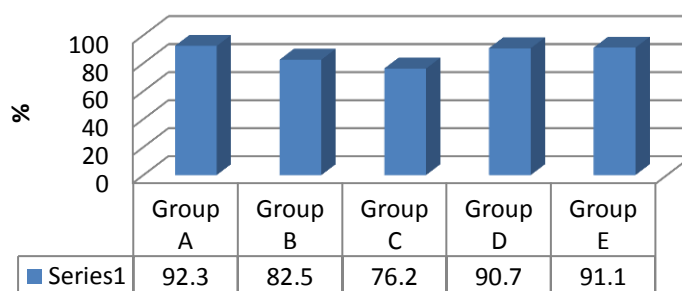
جامعة تكريت ، كلية التربية للعلوم الصرفة ، قسم علوم حياة

**الخلاصة**

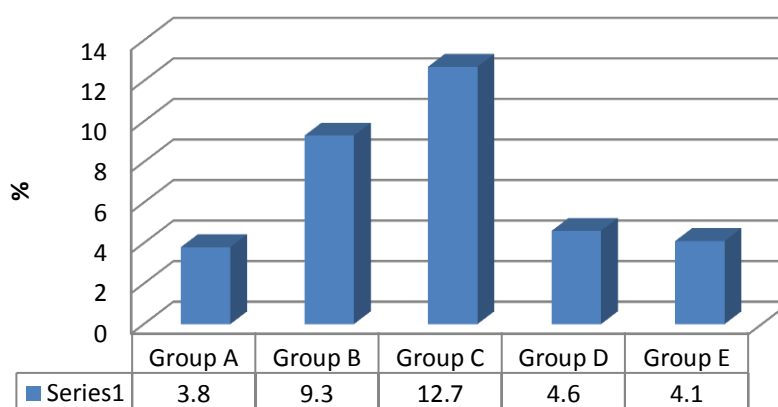
استخدمت الدراسة الحالية 20 من الجرذ الابيض والتقسيم عشوائيا إلى خمس مجاميع (كل مجموعة تتكون 4 جرذان)، المجموعة الأولى هي مجموعة السيطرة والتي جرعت بحمية غذائية وماء فقط، المجموعة الثانية والتي جرعت بخلاص الرصاص لمدة اسبوعين، المجموعة الثالثة والتي جرعت بخلاص الرصاص لمدة 4 اسابيع، المجموعة الرابعة والتي جرعت بخلاص الرصاص لمدة اسبوعين وتم معالجتها بمستخلص الجذيرات بجرعة (1 مل) لمدة 15 يوم، المجموعة الخامسة والتي جرعت بخلاص الرصاص لمدة 4 اسابيع وتم معالجتها بمستخلص الجذيرات بجرعة (1 مل) لمدة 15 يوم. الجرذان التي جرعت بخلاص الرصاص اظهرت انخفاض في اعداد النطف وزيادة اعداد النطف المشوهه مع انخفاض مستويات FSH، LH، testosterone وكانت ذات تغييرات عالية المعنوية ( $P < 0.01$ ) مقارنة مع مجموعة السيطرة ولكن عادت جميع القياسات التي تم اجرائها الى المستويات الطبيعية عندما تمت معالجة المجاميع المعاملة بخلاص الرصاص بمستخلص جذيرات نبات الكركم. يستنتج من هذه الدراسة أن مستخلص جذيرات نبات الكركم لها تأثير جيد بما فيه الكفاية على خصوبة ذكور الجرذان البيض.

***Study the protective effect of Curcuma longa rhizomes extract against the toxicity of lead acetate that induce infertility in male albino rats***

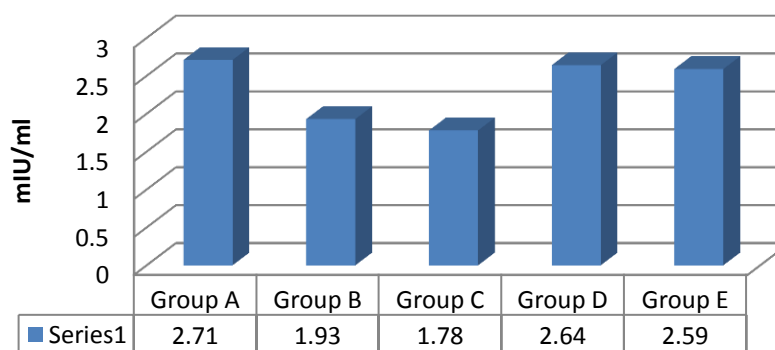
**Chart (1): live sperm**



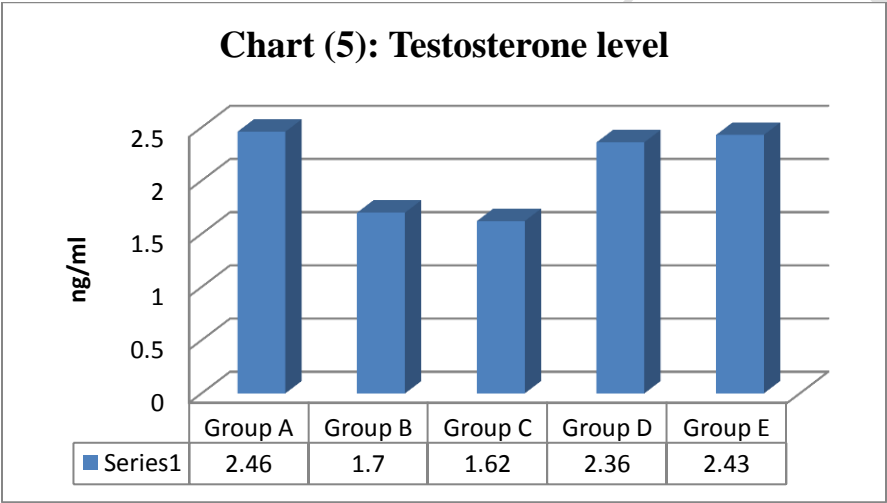
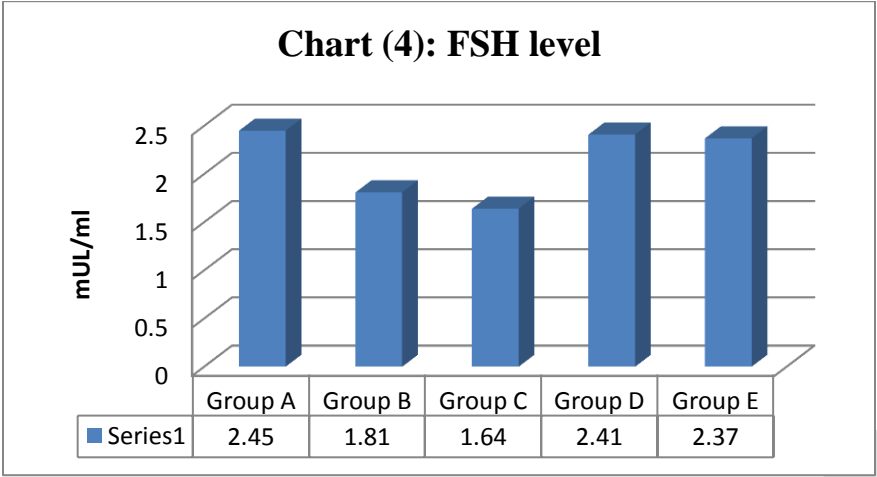
**Chart (2): sperm deformity**



**Chart (3): LH level**



*Study the protective effect of Curcuma longa rhizomes extract against the toxicity of lead acetate that induce infertility in male albino rats*



***Study the protective effect of *Curcuma longa* rhizomes extract against the toxicity of lead acetate that induce infertility in male albino rats***

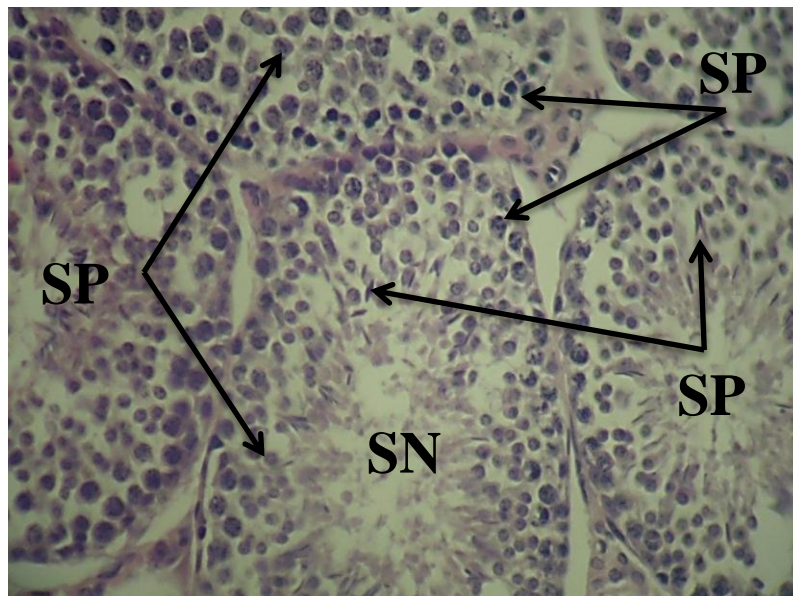


Figure (1): testis of control group showed normal seminiferous tubules (SNF), spermatogonia (SPG), spermatocytes (SPC) and

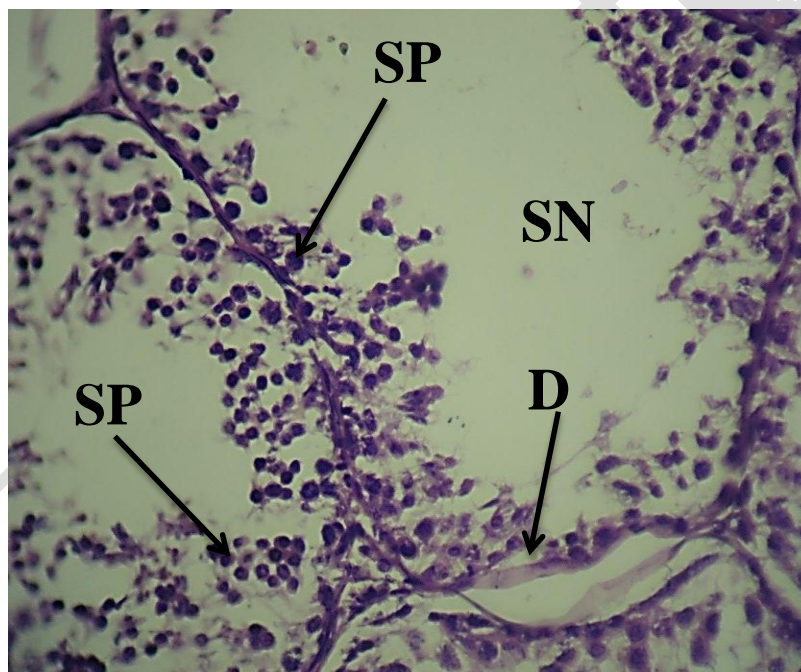

Figure (2): testis of lead acetate for two weeks group showed damage wall (DW) of seminiferous tubules (SNF) with spermatogonia (SPG) and spermatocytes (SPC) 400X H&E.

***Study the protective effect of *Curcuma longa* rhizomes extract against the toxicity of lead acetate that induce infertility in male albino rats***

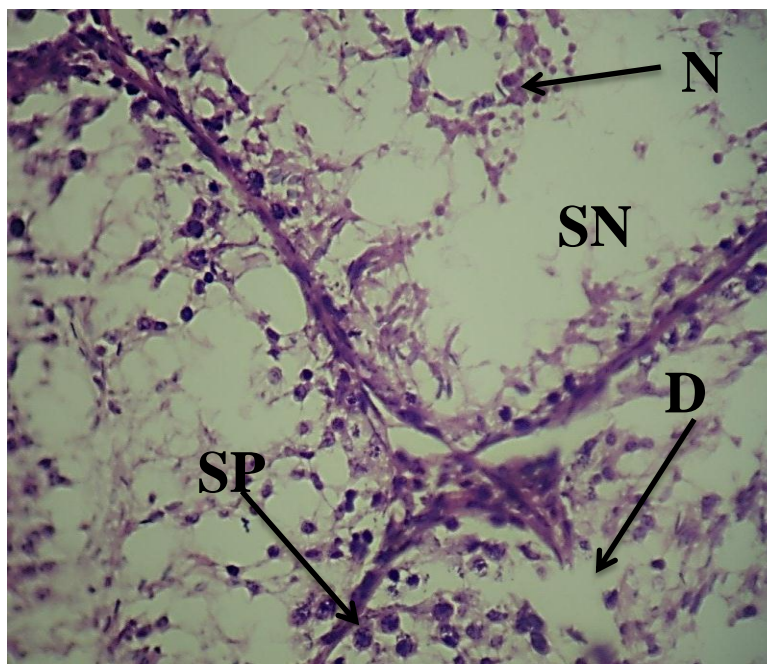


Figure (3): testis of lead acetate for four weeks group showed damage wall (DW) of seminiferous tubules (SNF) with necrotic materials (NM) in the lumen and spermatozoa

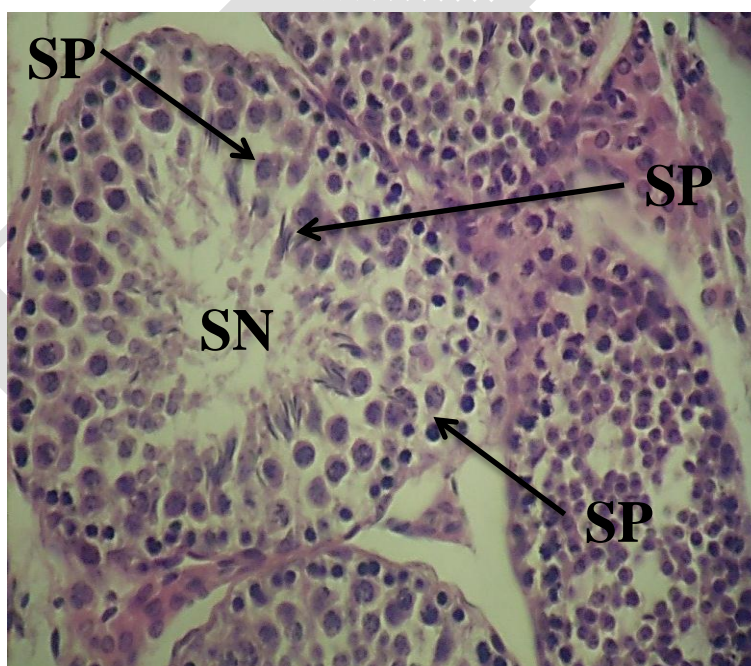


Figure (4): testis of lead acetate for two weeks and treated with rhizomes extract group showed normal seminiferous tubules (SNF). spermatozoa (SPG). spermatozoa (SPC)



***Study the protective effect of *Curcuma longa* rhizomes extract against the toxicity of lead acetate that induce infertility in male albino rats***

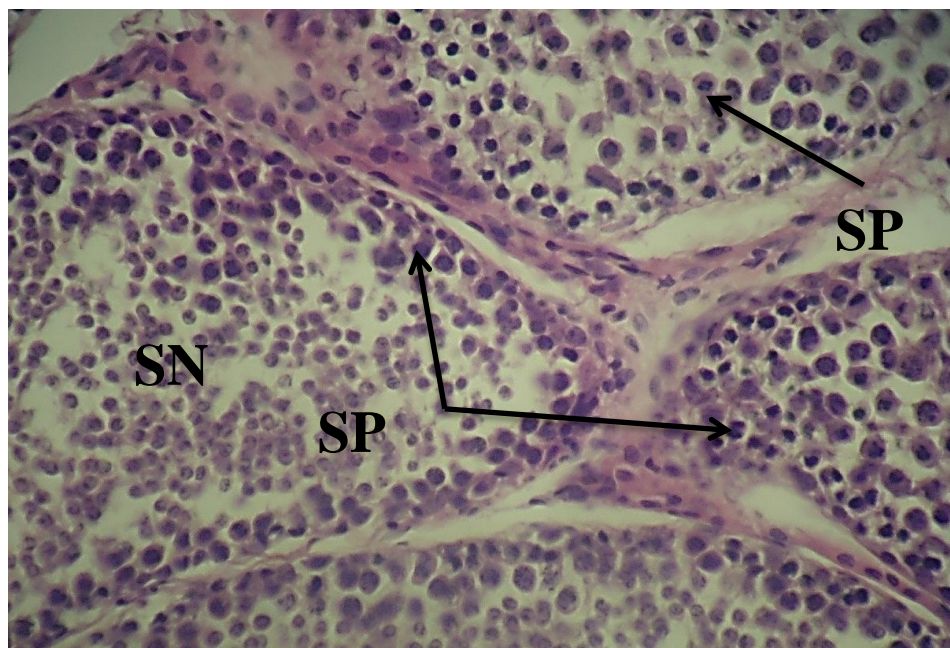


Figure (5): testis of lead acetate for four weeks and treated with rhizomes extract group showed normal seminiferous tubules (SNF), spermatogonia (SPG) and spermatocytes (SPC) 400X H&E.