

# Ophthalmology

Dr Abdulmelik shallal

## The lacrimal apparatus

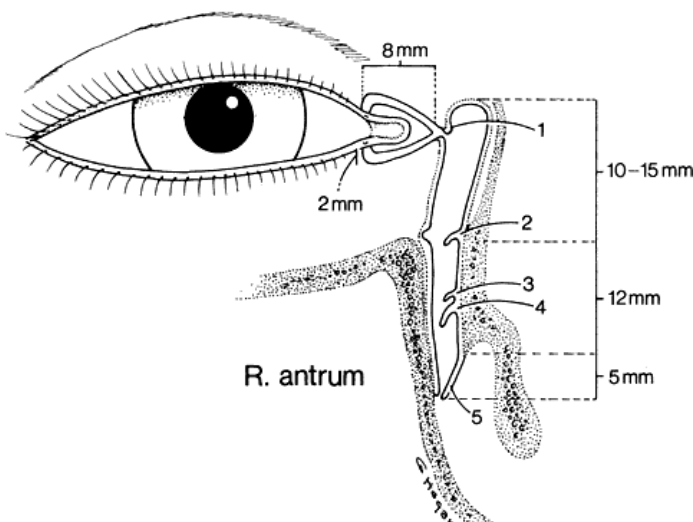
The lacrimal system consists of:

### 1- Secretory portion: Comprises the following:

- a- The lacrimal gland: Which is divided into palpebral (near the temporal aspect of upper eyelid) and orbital (near the eyeball) lobes, and it is situated in the upper temporal angle of the orbit. (Aqueous secretion)
- b- Accessory lacrimal glands: glands of Krause and glands of wolfring.
- c- Meibomian glands.
- d- Glands of Zeis.
- e- Sweat glands of Möll. (For oily secretion)
- f- Goblet cells of conjunctiva.
- g- Glands of Manz.
- h- Glands of Henle. (For mucin secretion)

### 2- Drainage portion: Consists of:

- a- Two puncti on the eyelid margins, one upper and one lower.
- b- Vertical canaliculi (Ampullae): 2 mm in length.
- c- Horizontal canaliculi: 8 mm.
- d- The lacrimal sac: 10 mm long.
- e- The nasolacrimal duct: 12 mm, ends into valve of Hasner in the inferior meatus of the lateral nasal wall.



## The tear film

The pre-corneal tear film has three layers:

- 1- Superficial oily layer:** Its main advantage is to prevent evaporation.
- 2- Middle aqueous layer:** the thickest layer. Its functions mention below.\*
- 3- Inner mucin layer:** Immediately adjacent to cornea: it covered corneal surface and converted it from hydrophobic into hydrophilic so the aqueous layer adherent to it.

### Functions of tear:\*

- 1-** Forms and maintains a smooth refracting surface over the cornea.
- 2-** Maintains a moist environment for the conjunctival and corneal epithelium, as dryness of the cornea and conjunctiva causes sloughing of their epithelium and it may ends with corneal ulcer.
- 3-** Bactericidal properties, as it has lysozymes and Igs (IgA).
- 4-** Lubricates the lids.
- 5-** Transports metabolic products (especially CO<sub>2</sub> & O<sub>2</sub>) for cornea as it is an avascular structure, so the tear film transports these nutrients from the atmosphere to the cornea and vice versa.
- 6-** Provides a pathway for WBCs in case of injury (enhances the migration of WBCs).
- 7-** Dilutes and washes away noxious stimuli.

### Physiology of tear:

- 1-** Tear flow along the upper and lower marginal stripe and enter the upper and lower canaliculi by capillarity (capillary action) and suction. 70% of tear pass through the lower punctum and 30% through the upper punctum because of gravity.
- 2-** With each blink, there is contraction of *palpebral part* of orbicularis oculi that compress the ampullae, shorten the horizontal canaliculi. Contraction of *lacrimalis part* of orbicularis oculi cause expansion of lacrimal sac so that creating negative pressure, which sucks the tear in to sac.
- 3-** When the eyes are open, the muscle relax so the sac collapses and a positive pressure is created which forces the tears down into the nose (plus the gravity effect).

### Causes of a watering eye:

Epiphora is defined as the sign of overflow of tears, and may be caused by the following:

- 1-Hypersecretion** (pseudoepiphora) secondary to ocular inflammation or surface disease. In these cases watering is associated with symptoms of the underlying cause and treatment is usually medical.

2-Defective drainage (true epiphora) due to compromise of the lacrimal drainage system. This tends to be exacerbated by a cold and windy atmosphere, and is least evident in a warm dry room. It may be caused by:

a-Malposition of the lacrimal puncta (e.g. secondary to ectropion).

b-Obstruction along the lacrimal drainage system, from the puncta to the nasolacrimal duct.

c-Lacrimal pump failure, which may occur secondarily to lower lid laxity or weakness of the orbicularis muscle (e.g. facial nerve palsy).

## **Diseases of lacrimal glands**

### **1- Acute dacryoadenitis:**

Is an uncommon inflammation of the lacrimal gland that usually accompanies systemic diseases, e.g. mumps and infectious mononucleosis (IMN).

Purulent infection may be secondary to extension of inflammation from the eyelids or the conjunctiva.

### **Signs and symptoms:**

a- *Pain* and discomfort in the upper outer position of the orbit.

b- Mechanical blepharoptosis due to lid swelling.

c- Eversion of the upper eyelid indicates a *swollen* and *reddened gland*.

### **Treatment:**

Usually self-limited, but we use antibiotics if there is purulent discharge.

### **2- Chronic dacryoadenitis:**

Is a *proliferative* inflammation of the lacrimal gland that occurs in a variety of disorders; sarcoidosis, sjögren's syndrome, leukaemia, lymphoma, amyloidosis, TB, syphilis and foreign body granuloma.

### **Signs and symptoms:**

a- *Painless* enlargement of the lacrimal gland.

b- Eversion of the upper lid shows enlargement of the gland, but there is *no congestion*.

**Treatment:** Directed towards the cause.

## **Diseases of the lacrimal passages**

**Dacryocystitis:** Is an acute or chronic inflammation of the lacrimal sac. The cause is obstruction of the lacrimal sac or nasolacrimal duct followed by microbial infection.

### **1- Acute dacryocystitis:**

Is a suppurative inflammation of the lacrimal sac associated with cellulitis of the overlying tissues (tissues medial to the medial canthus).

#### **Signs and symptoms:**

Acute onset of painful swelling, tenderness overlying the lacrimal sac combined with widespread cellulitis and associated constitutional symptoms.

#### **Treatment:**

- Local hot compresses and systemic antibiotics.
- Incision and drainage if there is abscess formation (incision and drainage may end with fistula formation, so avoiding this procedure is a must unless there is large abscess which is not responded to antibiotics).
- DCR after resolution of infection & inflammation.

### **2- Chronic dacryocystitis:**

Occurs due to obstruction of nasolacrimal duct and it is seen most frequently in middle life.

#### **Signs and symptoms:**

- Epiphora which may be associated with a chronic or recurrent conjunctivitis (due to stagnation of tears in the lacrimal gland).
- Painless swelling at the inner canthus.
- In some cases a swelling is absent although pressure over the sac results in reflux of mucopurulent material through the canaliculi.

**Treatment:** Dacryocystorhinostomy (DCR).

DCR can be done by three surgical ways:

#### **1- External Traditional DCR:**

A 15-30 mm incision is made on the side of the nose and some bone is removed to make a connection between the lacrimal sac and middle meatus of the nose. Tubes are left behind to prevent the fistula from becoming closed and are removed after a few months. success rate of over 90%

#### **2- Endoscopic Endonasal DCR:**

The operation can also be performed endoscopically through the nose where an opening is fashioned in the lacrimal sac from within the nose. The advantages include lesser peri-operative morbidity, and no scar. The success rate is up to 90%.

#### **3-Endoscopic Laser DCR:**

Performed with a Holmium:YAG or KTP laser, this is a relatively rapid procedure which can be carried out under local anaesthesia. It is therefore particularly suitable for elderly patients. The success rate is only about 70% but because normal anatomy is not disrupted it does not prejudice subsequent surgical intervention in the cases that fail.

## **Lacrimal drainage obstruction**

### **1- Punctal stenosis (with epiphora):**

#### **Causes:**

- a- Idiopathic: usually in elderly people (the most common cause).
- b- chronic blepharitis.
- c- Herpes simplex lid infection.
- d- Trachoma.
- e- Cicatricial conjunctivitis.

#### **Treatment:**

**Initial treatment:** Dilatation by special probe.

### **2- Canalicular obstruction:**

#### **Causes:**

- a- Idiopathic fibrosis (most common).
- b- Chronic dacryocystitis.
- c- Herpes simplex lid infection.
- d- Cicatricial conjunctivitis.
- e- Systemic use of 5-fluorouracil.

#### **Treatment:**

**Partial obstruction:** Intubation of the canalicular for six months.

**Complete obstruction:** DCR or CDCR (Conjunctival DCR), insertion of Jones tube from conjunctival sac to the lacrimal sac with DCR.

### **3- Acquired nasolacrimal obstruction:**

#### **Causes:**

- a- idiopathic stenosis (most common cause).
- b- Naso-orbital trauma.
- c- Irradiation.
- d- Wegener's granulomatosis.
- e- Nasopharyngeal tumor.

**Treatment:** DCR.

### **4- Congenital nasolacrimal duct obstruction:**

At birth, the lower end of the nasolacrimal duct (NLD) is frequently non-canalized (near the valve of Hasner), but this is of no clinical significance in most neonates because it canalizes spontaneously soon after birth. Sometime, the occlusion is continued and results in:

#### **Signs:**

- a- Epiphora.
- b- Gentle pressure of the lacrimal sac causes reflex of purulent material from the puncti.
- c- occasionally, acute dacryocystitis might result.

### **Differential diagnosis of watery eye (lacrimation and epiphora) in neonates:**

- a-** congenital drainage system obstruction.
- b-** Ophthalmia neonatorum. (neonatal conjunctivitis)
- c-** Congenital glaucoma. (very important to be remember)

### **Treatment:**

**a- Massage:** of the NLD, so increase the hydrostatic pressure and thereby ruptures the membranous obstruction. This is done as ten strokes applied four times daily.

**b- Probing:** overcomes the obstructive membrane at Hasner's valve. It should not be performed until the age of 12-18 months because spontaneous canalization occurs in about 95% of cases.

Postoperative antibiotic and steroid drops are used four times daily for one week, if after six weeks there is no improvement, the probing should be repeated.

90% are cured by the first trial of probing and further 6% by the second. Failure of surgery is due to congenital alteration of NLD anatomy or congenitally absent.

Cases with persistent symptoms in spite of two satisfactory probing can be treated by DCR at preschool age.

### **Dry eye (Keratoconjunctivitis Sicca "KCS"):**

*Absent* or *reduced* tears cause keratinization of corneal and conjunctival epithelium and possibly marked corneal scarring and opacification, usually both eyes are affected.

#### **Symptoms:**

- Burning sensation.
- Feeling of dryness (the patient himself told you that his eyes are dry).
- Continuous foreign body sensation.
- Mucus discharge (as the aqueous part is affected).
- Transient blurring and vision (as it Forms and maintains a smooth refracting surface over the cornea).
- Itching.
- Photophobia.

#### **Causes of dry eyes:**

**1-** Atrophy and fibrosis of lacrimal gland tissue as a result of a destructive infiltration by mononuclear cells, usually associated with systemic diseases.

**a- Pure KCS:** Involving lacrimal gland alone (dry eye only and nothing else).

**b- Primary sjögren's syndrome:** Sjögren syndrome is characterized by autoimmune inflammation and destruction of lacrimal and salivary

**glands. The condition is classified as primary when it exists in isolation, and secondary when associated with other diseases (see below).**

**c- Secondary sjögren's syndrome:** dry eye and mouth associated with systemic disease, most common one is rheumatoid arthritis, and other diseases are SLE, systemic sclerosis, hashimoto thyroiditis and primary biliary cirrhosis.

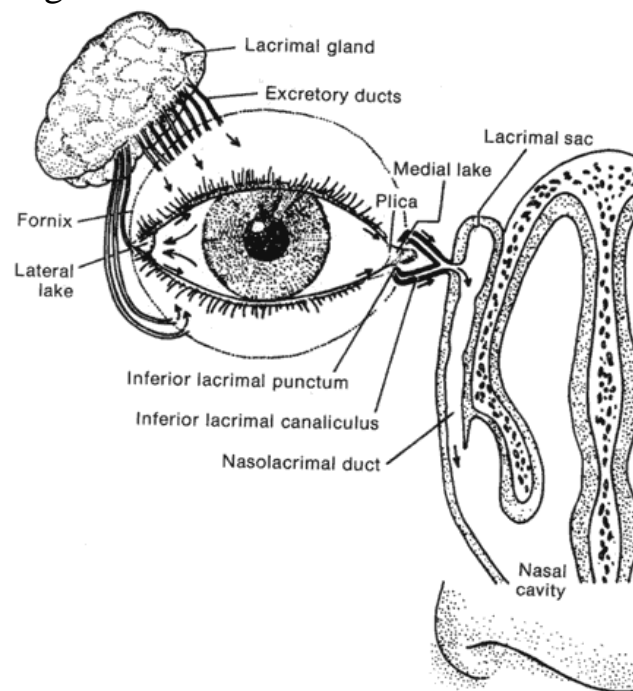
## 2- Miscellaneous causes:

**a-** Destruction of lacrimal tissue by tumors, sarcoidosis.

**b-** Meibomian gland dysfunction.

**c-** Absence of lacrimal gland which is either congenital or due to surgical removal (due to involvement by tumor).

**d-** Blockage of the excretory ductules (due to burns, drugs, diseases ...etc, that cause blockage of these excretory ducts. Excretory ducts are about six ducts open in the supero-lateral part of conjunctival fornix and 2 ducts open at the infero-lateral part of conjunctival fornix). This blockage due to severe conjunctival scarring.



## Treatment of dry eye:

Supplementation of tears with the use of tear substitutes is the mainstay of therapy for dry eyes. A variety of tear substitutes are available. The preservatives found in artificial tears can be toxic to the ocular surface, so the introduction of preservative-free artificial tears has provided a major improvement in treatment. Recently, several formulations have been introduced that have “transiently preserved” agents. These preservatives are inactivated on contact with the tear film.

Because of their duration in the conjunctival sac, ointments or gels as a lubricating agent can be very useful. Sustained-release inserts and gels. And there are other measures that are not used routinely.

## Classification of KCS

### 1 Aqueous layer deficiency (hypo secretory)

- Sjögren syndrome
- Non-Sjögren

### 2 Evaporative

- Meibomian gland disease
- Exposure
- Defective blinking
- Environmental factors

## -- Causes of non-Sjögren KCS

### 1 Primary age-related hyposecretion is the most common

### 2 Lacrimal tissue destruction

- Tumour
- Inflammation (e.g. pseudotumour or sarcoidosis)

### 3 Absence or reduction of lacrimal gland tissue

- Surgical removal
- Rarely congenital

### 4 Conjunctival scarring with obstruction of lacrimal gland ductules

- Chemical burns
- Cicatricial pemphigoid
- Stevens–Johnson syndrome
- Long-standing trachoma

### 5 Neurological lesions with sensory or motor reflex loss

- Parkinson disease
- Reduced sensation may also contribute to dry eye after refractive surgery and contact lens wear

### 6 Vitamin A deficiency

## Primary Sjögren syndrome

Sjögren syndrome is characterized by autoimmune inflammation and destruction of lacrimal and salivary glands. It affects females more commonly than males and is characterized by the following:

### 1 **Presentation** is in adult life with grittiness of the eyes and dryness of the mouth.

### 2 **Signs**

- Enlargement of salivary glands (Fig. 4.2B) and occasionally lacrimal glands, with secondary diminished salivary flow rate and a dry fissured tongue.



- Dry nasal passages, diminished vaginal secretions and resultant dyspareunia.
  - Raynaud phenomenon and cutaneous vasculitis.
  - Arthralgia, myalgia and fatigue may be present.
- 4 Diagnostic tests** include serum autoantibodies, Schirmer test and biopsy of minor salivary glands.
- 5 Treatment options** include a range of symptomatic treatments, salivary stimulants and immunosuppression with systemic steroids and cytotoxic agents.