



INVITED MEDICAL REVIEW

Ultraviolet phototherapy for cutaneous diseases: a concise review

R Vangipuram¹, SR Feldman²

¹University of Cincinnati Medical Center, Cincinnati, OH; ²Department of Dermatology, Wake Forest University School of Medicine, Winston-Salem, NC, USA

Phototherapy is the use of non-ionizing radiation, primarily in the ultraviolet spectrum, to treat disease. In dermatology, ultraviolet (UV) phototherapy remains an established, lower cost, and often preferred option for many common skin conditions, despite the introduction of newer potent biologics. This article introduces a principal therapeutic modality in the treatment of psoriasis, atopic dermatitis (eczema), vitiligo, and morphea among other diseases where oral manifestations may be present, providing basic information about the use of UVA, UVB, and PUVA. Practical considerations and side effects of phototherapy are described. Phototherapy is an effective treatment for many illnesses and carries a relatively benign side-effect profile.

Oral Diseases (2016) 22, 253–259

Keywords: phototherapy; UV therapy; PUVA; psoriasis; atopic dermatitis; vitiligo

Introduction

The management of dermatological disease often involves careful examination and consideration of mucocutaneous involvement. A number of common illnesses encountered in dermatology have either mucocutaneous involvement or telltale signs involving the mucosa. Patients with psoriasis, an inflammatory skin rash, often present with striations of their tongues. Patients with vitiligo, a depigmentation disorder, often have characteristic perioral involvement. Less common disorders, such as morphea, in which there is abnormal loss of elasticity of the skin, can present many challenges to the patient if microstomia is present. It may be beneficial for clinicians to recognize treatment options that dermatologists use in the day-to-day treatments of various cutaneous illnesses.

Phototherapy is often used as a treatment for such common and rare illnesses. Its benefits have long been recognized and used in dermatology. However, clinicians in other specialties may be unfamiliar with this mode of therapy. This review is a basic introduction to phototherapy. This article will describe the electromagnetic spectrum, the types of UV therapy used in the treatment of cutaneous conditions, and the mechanism with which phototherapy exerts its therapeutic effects. It will also cover the phototherapy treatment regimens of common illnesses such as psoriasis, atopic dermatitis, and vitiligo, and rare diseases such as mycosis fungoides (a type of a cutaneous T-cell lymphoma) and sclerotic skin disease. The main side effects of each phototherapeutic modality are described, and practical considerations are addressed. Phototherapy is the use of non-ionizing radiation, primarily in the ultraviolet spectrum, to treat disease. The practice of phototherapy has been in place since 2000 B.C.E. when sunlight (heliotherapy) was used to treat a variety of skin conditions such as vitiligo in Egypt, Greece, and India (Bolognia *et al*, 2012). In more recent history, Niels Finsen was awarded the Nobel Prize in 1903 ‘in recognition of his contribution to the treatment of diseases, especially lupus vulgaris, with concentrated light radiation, whereby he has opened a new avenue for medical science’ (Moller *et al*, 2005). Finsen discovered that UV radiation was beneficial in treating lupus vulgaris, a skin condition caused by *Mycobacterium tuberculosis*. UV radiation was the only effective treatment against tubercle bacilli in the skin before the introduction of antituberculous chemotherapy in the 1950s (*ibid*). In the last century, the use of ultraviolet light to treat inflammatory skin conditions such as psoriasis was a breakthrough in dermatology (van Weelden *et al*, 1998).

In the last century, phototherapy has played a pivotal role in the treatment of dermatologic diseases. In the middle of the 20th century, advancements in UVB light therapy expanded treatment options for patients with psoriasis. In the 1970s, photochemotherapy (i.e. using psoralen as a photosensitizer in combination with UVA radiation [PUVA]) made its debut. PUVA became established in the treatment of skin diseases in the last quarter of the

Correspondence: Ramya Vangipuram, M.D., Department of Internal Medicine, University of Cincinnati Medical Center, 234 Goodman Drive, Cincinnati, Ohio, 45219. Tel: 336-716-7740, Fax: 513-558-3878, E-mail: rvangip@gmail.com
Received 11 August 2015; accepted 13 August 2015

20th century. More recent advances in the last few decades that have revolutionized phototherapy include narrowband UVB therapy, laser and other targeted phototherapy, photodynamic therapy, and UVA₁. In this review, the most frequently encountered UV treatments and their use in specific illnesses are described. These include UVB, UVA, and PUVA.

The electromagnetic spectrum

Ultraviolet light, adjacent to visible light on the electromagnetic spectrum, is of a shorter wavelength than visible light and thus carries more energy (according to the inverse relationship between wavelength and energy). Specific wavelengths of ultraviolet light are used to exert biological actions at the molecular level, which in turn produces observable clinical effects. Ultraviolet light can be further divided into three subcategories: UVC (200–290 nm), UVB (290–320 nm), and UVA (320–400 nm). Most UV radiation that reaches the earth is UVA. Approximately 5% of UVB is present in terrestrial sunlight. UVC is typically filtered by the ozone layer (Baron and Suggs, 2014).

UVA can be further categorized into UVA₂ (320–340 nm) and UVA₁ (340–400 nm), based on the observation that UVA₂ is more similar to UVB in regard to clinical responses it elicits, such as redness, immunomodulatory activity, and photocarcinogenesis, whereby light triggers cascade of biological events that induce cancer (ibid).

How phototherapy works

The depth of light penetration is critical for phototherapy. UVB is generally absorbed in the epidermis and upper dermis, whereas UVA (because of its longer wavelengths) penetrates well into the dermis (Baron and Suggs, 2014). UVB radiation primarily acts on cells at the epidermis and the epidermodermal junction, whereas UVA radiation affects epidermal and dermal components, especially dermal blood vessels (Weichenthal and Schwarz, 2005).

When light penetrates through skin, molecules called chromophores absorb the light resulting in chemical reactions. The principal chromophore targeted by UVB is nuclear DNA (Bulat *et al*, 2011). Immediate effects are the formation of DNA photoproducts and DNA damage leading to apoptosis of skin cells (primarily keratinocytes), along with resident and circulating immune cells, fibroblasts, and endothelial cells (ibid). Delayed effects include induction of anti-inflammatory prostaglandins and cytokines (ibid). Localized and systemic immune suppression, alteration in cytokine expression, and cell-cycle arrest all contribute to the suppression of disease activity.

UVB therapy

Although broadband UVB (BB-UVB) therapy (290–320 nm) was initially the treatment used in the treatment of psoriatic plaques, narrowband UVB (NB-UVB) (311–312 nm) was superior with respect to both clearing and remission times (Bolognia *et al*, 2012). Narrowband UVB

currently represents the most frequently used UVB phototherapy for psoriasis; it is also beneficial for a variety of other dermatoses, especially in recalcitrant atopic dermatitis (ibid).

Excimer, which is short for ‘excited dimer’, is a relatively new technology for creating a very narrow source of 308 nm UVB light. Excimer technology is available in both laser and non-laser lamp sources (Figure 1). With a small spot size, excimer devices facilitate treating exclusively affected areas of skin. Because normal skin is not treated, higher doses can be used from the beginning, fewer treatments are needed and normal skin is not exposed, thereby reducing the long-term side effects of phototherapy. In the United States, the excimer laser is approved for treatment of psoriasis, atopic dermatitis, and vitiligo. The excimer laser is effective for various other chronic localized inflammatory dermatoses (Table 1) (Mehraban and Feily, 2014).

UVA therapy

The UVA spectrum (320–400 nm) is subdivided into two parts: UVA₁ (340–400 nm) and UVA₂ (320–340 nm). The main reason for this subdivision was the observation that UVA₂ resembled UVB in its ability to cause erythema as well as immunomodulation and photocarcinogenesis. Because of its longer wavelength, UVA₁ radiation penetrates more deeply into the skin than UVA₂ and thus affects not only epidermal structures, but also mid- and deep-dermal components, especially blood vessels (Bulat *et al*, 2011). Targets of UV absorption include blood vessel components, dermal dendritic cells, dermal fibroblasts, endothelial cells, and mast cells, in addition to DNA components (ibid). The ability of UVA radiation to cause skin erythema (redness) is significantly lower than that of UVB, and thus, patients can tolerate much higher doses (as measured in Joules). UVA₁ phototherapy works mainly through the induction of apoptosis of skin infiltrating T cells and induction of collagenase-1 expression in dermal fibroblasts, and through depletion of T-cells (ibid).

Psoralen + UVA

Psoralen photochemotherapy (PUVA) combines the use of psoralen (P) and long-wave UV radiation (UVA). This combination results in a potent phototoxic effect, which is not produced by either of the components alone (Shenoi and Prabhu, 2014). Psoralens are naturally occurring furocoumarins that are found in a large number of plants and can also be synthetically derived (ibid). Psoralens enter the cells and intercalate between DNA base pairs. On exposure to UVA, psoralens absorb photons, become chemically activated, and covalently bind to DNA base pairs forming crosslinks. The DNA crosslinks have antiproliferative, anti-angiogenic, apoptotic, and immunosuppressive effects. The immunosuppressive effects include alteration in cytokines and lymphocyte apoptosis. In addition, photochemotherapy also stimulates melanogenesis, although the mechanism behind this is unknown (Bolognia *et al*, 2012).

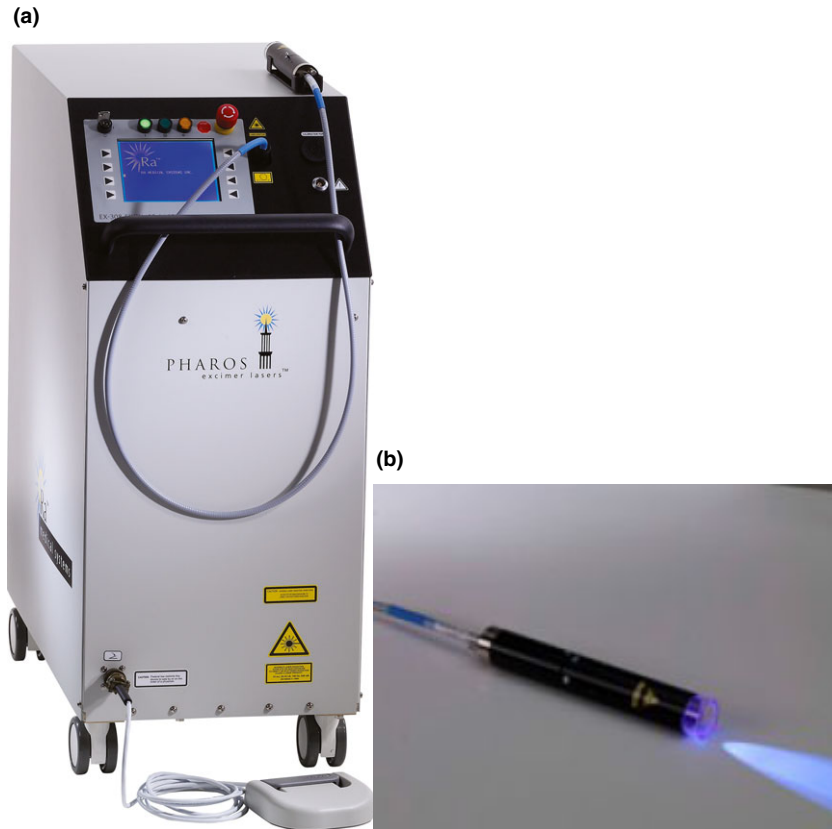


Figure 1 (a and b) Excimer laser (reprinted with permission from Ra Medical Systems)

Table 1 Other indications for excimer laser therapy

Alopecia areata
Folliculitis
Granuloma annulare
Lichen planus

Psoralens can be administered orally or applied topically in the form of solutions, creams or baths, prior to UVA exposure. Topical exposure to extracts, seeds or parts of plants (e.g. *Ammi majus*, *Psoralea corylifolia*) that contain natural psoralens, followed by exposure to sunlight, was used as a remedy for vitiligo for thousands of years in ancient Egypt and India (Juzeniene and Moan, 2012). In the 1970s, modern PUVA therapy using 8-methoxypsoralen as a photosensitizer became established for the treatment of psoriasis (Shenoi and Prabhu, 2014). Subsequently, its benefits for the treatment of multiple skin disorders were recognized (Bologna *et al*, 2012).

Disease-specific therapy

Common conditions for which ultraviolet phototherapy provides a sustainable therapeutic effect include psoriasis, atopic dermatitis, and vitiligo (Table 2).

Psoriasis

Psoriasis is a chronic inflammatory disease of the skin, which results in distinctive red plaques on the extensor surfaces, scalp, and other areas. The prevalence in the

Table 2 Summary of conditions for which phototherapy is used

NB-UVB	UVA ₁	PUVA
Psoriasis	Morphea	Psoriasis
Atopic dermatitis	Atopic dermatitis	Atopic dermatitis
Vitiligo		Vitiligo
Mycosis fungoides		Mycosis fungoides

general population is estimated to be about 2% (Rajpara *et al*, 2010). The presence of psoriatic lesions in the oral cavity is uncommon and controversial (Picciani *et al*, 2015). However, there is a higher prevalence of geographic tongue and fissured tongue in patients with psoriasis when compared to the general population (ibid). In one study, geographic tongue was more common in patients with early onset psoriasis and fissured tongue occurred with more frequency in patients with late onset psoriasis, defined as the disease onset after the age of 30) (ibid). The authors suggest that geographic tongue may be a marker of psoriasis severity (ibid).

The use of BB-UVB was a breakthrough therapeutic modality when it was introduced for the treatment of psoriasis (Totonchy and Chiu, 2014). However, later studies found that NB-UVB clears psoriatic plaques faster and produces longer remissions than BB-UVB does, thus establishing it as the phototherapeutic modality of choice for psoriasis (Lapolla *et al*, 2011). The addition of UVA does not enhance the therapeutic efficacy of UVB in psoriasis, unlike in atopic dermatitis. PUVA is a potent treat-

ment option. Several multicenter studies in the 1970s established the efficacy of PUVA and brought about a new therapeutic modality in the approach to psoriasis (Shenoi and Prabhu, 2014). Via different mechanisms, PUVA and UVB phototherapy cause apoptosis of lymphocytes (Lapolla *et al*, 2011). Head-to-head trials of NB-UVB vs PUVA yield equivalent results in the efficacy of treating psoriatic skin; however, NB-UVB treatment carries a safer side-effect profile (Lapolla *et al*, 2011). PUVA predisposes patients to development of skin cancer, and use of PUVA has diminished considerably now that biologics are available. Psoralens should not be used in combination with tanning beds because life-threatening burns can result.

Atopic dermatitis

Atopic dermatitis (AD), commonly referred to as eczema, is a chronic, relapsing, and often intensely pruritic inflammatory disorder of the skin. The prevalence is up to 20% in children and 2–3% in adults (Eichenfield *et al*, 2014a, b). Intractable itching is a hallmark of AD; it is often referred to as the ‘itch that rashes’. The pathogenesis of AD is complex and multifactorial (*ibid*). Skin barrier dysfunction, environmental factors, genetic predisposition, and immune dysfunction all play a role in its development and are closely intertwined (*ibid*). The primary pharmacologic treatment is topical corticosteroids.

Narrowband UVB is generally the most commonly recommended light treatment, with its low-risk profile, relative efficacy, availability, and provider comfort level (*ibid*). Phototherapy for atopic dermatitis developed after reports detailing patients’ improvements during the summer (Patrizi *et al*, 2009). Although a wide spectrum of UV have been reported to be beneficial, modern treatments primarily use NB-UVB and UVA₁. Clinical evidence suggests that NB-UVB is the preferred option for the treatment of AD due to its safety and efficacy profile (Dogra and Mahajan, 2015). UVA₁ or PUVA can be considered second line or for control of acute exacerbations (*ibid*). In addition, phototherapy can be used as maintenance therapy in patients with chronic disease (Eichenfield *et al*, 2014a,b).

Vitiligo

Vitiligo is a depigmentation disorder that results from loss of melanocytes and the pigment they produce (Shenoi and Prabhu, 2014). The pathogenesis is believed to be the result of immune attack on melanocytes, although other mechanisms may be involved (*ibid*). Vitiligo affects 0.1–2% of the general population (Speeckaert and van Geel, 2014). The mean age of onset of vitiligo is 25 years (*ibid*). The most common sites of involvement are the face, hands and trunk (*ibid*). Involvement of the perioral region is linked to an older age of onset, whereas involvement of the periocular area is predominantly seen in younger patients; the reasoning for this pattern is unclear (*ibid*). The first-line therapy for vitiligo is topical corticosteroids, if the affected area is limited. However, phototherapy is the treatment of choice when more than 20% of the body surface area is involved or if first-line treatment fails (Guan *et al*, 2015).

Phototherapy for vitiligo came into consideration after the observation in many patients that sun-exposed lesions demonstrated repigmentation around hair follicles during the summer months (Juzeniene and Moan, 2012). Facial lesions are more responsive to phototherapy, whereas acral sites such as the hands and feet are the least responsive (Speeckaert and van Geel, 2014). Repigmentation after phototherapy is postulated to be the result of activation, proliferation, and migration of melanocytes to the epidermis, where they form perifollicular pigmentation islands (Shenoi and Prabhu, 2014).

PUVA is also used in the treatment of widespread vitiligo with satisfactory results, although UVB is the preferred phototherapy option because of near equivalent efficacy and fewer side effects (Guan *et al*, 2015). PUVA induces repigmentation by varying mechanisms such as stimulation of melanogenesis, immunomodulation, and activation of growth factors, although the exact mechanism is still speculative. (Shenoi and Prabhu, 2014). The goal of PUVA therapy for vitiligo is to induce a phototoxic reaction, which is then followed by pigmentation of skin. PUVA-induced erythema usually appears hours to after exposure to UVA radiation; however, PUVA-induced pigmentation can occur even in the absence of erythema (*ibid*).

Mycosis fungoides

Mycosis fungoides (MF) is the most common form of cutaneous T-cell lymphoma, which comprises a heterogeneous group of non-Hodgkin lymphomas that are the result of a clonal proliferation of aberrant T cells (Bolognia *et al*, 2012). The clinical presentation includes red, scaly, and sometimes poikilodermatous (mottled pigmentation) patches and plaques that often itch. MF has a chronic and indolent course defined by treatment-responsive remissions and subsequent relapses (Trautinger, 2011). In many patients, the disease remains confined in the patches and plaques of skin for years to decades, and thus makes it an appropriate target for topical therapies. Conventional treatment strategies include topical corticosteroids, topical cytotoxic agents such as nitrogen mustard (mechlorethamine), and UV radiation. However, extracutaneous involvement occurs in up to 30% of patients and portends a poor prognosis (*ibid*). More advanced stages of MF require more aggressive treatment such as systemic chemotherapy, systemic retinoids, biological therapies, as well radiation therapies (Bolognia *et al*, 2012).

Lesions of MF frequently occur in non-sun-exposed areas of the body, and patients with early stage MF often benefit from exposure to natural sunlight. Thus, phototherapy and PUVA came to be recognized as effective therapeutic modalities in the management of mycosis fungoides. The proposed mechanisms for UVB phototherapy of MF include impairment of epidermal Langerhans cell function and alterations in cytokine production (Trautinger, 2011). Moreover, NB-UVB induces apoptosis of T lymphocytes (*ibid*). Infiltrating lymphocytes are strongly suppressed by PUVA, with variable effects on different T-cell subsets (*ibid*). PUVA is far more potent in inducing apoptosis in lymphocytes than in keratinocytes, which

may explain its efficacy in CTCL as well as in inflammatory skin diseases (Bolognia *et al*, 2012). In addition, both UVB and PUVA therapies inhibit DNA replication and cause cell-cycle arrest. Response to phototherapy is related to the clinical appearance of the skin type (patch [flat lesion] stage MF responds better than the plaque [raised lesion] type) but not the extent of skin involvement (Boztepe *et al*, 2005).

Sclerotic skin diseases

Scleroderma and systemic sclerosis are complex diseases in which extensive fibrosis secondary to collagen metabolism disturbance, vascular dysregulation, and autoantibodies against various cellular antigens are among the principal features (Bolognia *et al*, 2012). Patients develop taut, shiny skin, along with variable expression of other cutaneous changes such as fragile nails and visibly dilated blood vessels. The tight skin can affect most the body, including the face, resulting in loss of expression and difficulty opening the mouth properly. Limited areas of cutaneous involvement are called morphea, whereas more extensive skin and visceral changes are known as systemic sclerosis (*ibid*). Phototherapy is an effective therapeutic option in scleroderma and should be considered among the first approaches in the management of localized scleroderma or morphea. UVA₁ photons are the most deeply penetrating form of UV therapy and appear to exhibit their effects by induction of collagenase messenger RNA expression, depletion of skin T cells and cytokines (IL-1, IL-6), and neovascularization (Gabrielli, 2009). The primary goal of UVA₁ therapy is the induction of collagenase, which leads to a reduction in sclerotic plaque thickness, thereby increasing skin elasticity (Walker and Jacobe, 2011). UVA₁ has also been reported effective for softening sclerotic perioral skin and improving symptoms related to microstomia (Gabrielli, 2009).

Side effects and limitations

The most common acute side effect from UVB therapy is 'sunburn' – a red phototoxic reaction that occurs about 24 h after treatment. UV therapy can also provoke a polymorphous light eruption (a type of allergic reaction limited to the skin) or drug-induced photosensitivity.

Chronic side effects of UV phototherapy include lentigines (freckling), photoaging, precancerous lesions known as actinic keratoses, and skin cancer. However, there has yet to be confirmation that UVB phototherapy increases the risk of basal or squamous cell carcinomas (Walker and Jacobe, 2011).

Side effects of UVA₁ are usually fewer than with other types of phototherapy, and most studies have reported no serious adverse effects (Zandi *et al*, 2012). The most common acute side effects are hyperpigmentation, redness, dryness, and pruritus. Other side effects include herpes simplex virus reactivation and polymorphic light eruption.

The major long-term risk of UV phototherapy is photoaging and skin cancer. The induction of collagenase released by dermal fibroblasts as a response to UVA₁ therapy is beneficial for the treatment of sclerotic skin disease

but is also responsible for photoaging. Exposure to high-density UVA₁ can induce squamous cell carcinomas (Zandi *et al*, 2012). Currently, UVA₁ is regarded as being less carcinogenic than PUVA. More studies are warranted to investigate the potential long-term risk of this long-wave phototherapy.

Short-term side effects with oral administration of psoralens include nausea and vomiting. Bath or emollient psoralens may produce redness, pruritus, or dry skin. Less common side effects include neuropathic pain, which occurs due to phototoxic damage of dermal nerve endings. Excessive pigmentation can occur with repeated treatments, especially in darker-skinned individuals. Photoonycholysis (lifting of the nail plate) and melanonychia (darkening of the nail plate) are also possible. Central nervous system side effects such as headache, dizziness, depression, insomnia, and/or hyperactivity have also been reported. Reports of reactivation of herpes simplex have also been described (Shenoi and Prabhu, 2014). Psoralens should not be used in conjunction with tanning beds; severe burns and death can occur with this combination.

Long-term side effects include photoaging in most patients. This is partially reversible upon discontinuation of PUVA therapy. As would be expected, the photoaging changes are similar to those produced by natural exposure to sunlight and produce hyper- or hypopigmentation, dilated capillary blood vessels, wrinkles, lentigines, and actinic keratosis. Hypertrichosis has also been reported to occur in both men and women treated with long-term PUVA.

There is a dose-related increased risk for cutaneous malignancy, particularly squamous cell carcinoma, after cumulative high-dose systemic PUVA therapy. Male genitalia, in particular, have greater risk for squamous cell carcinoma after PUVA exposure. This risk can be minimized with the use of lower-dose UVA. There is controversy regarding the role of PUVA in melanoma (Shenoi and Prabhu, 2014). PUVA exposure does not significantly increase the risk of cataracts in patients who use eye protection.

Practical uses associated with phototherapy

Phototherapy is typically administered in a physician's office or treatment center. For some types of phototherapy, the patient stands in a booth lined with UV bulbs (Figure 2). More focused light sources, such as those used in targeted phototherapy, may also be used for treatment (Figure 3). The minimal erythema dose, defined as the amount of light needed to elicit skin redness after exposure, is used as a dosing guide to deliver phototherapy. The greatest barrier to more widespread use of phototherapy is frequent travel to a provider of this therapeutic modality.

In addition, out of pocket cost is also a significant barrier to home phototherapy, even to patients who are well insured (Dothard *et al*, 2014). Economic disincentives discourage its use, including both direct and indirect costs to the patient. Some limiting causes include distance from phototherapy site, cost of travel and lost wages, or time conflicts (Anderson, 2015).



Figure 2 Phototherapy booth (reprinted with permission from National Biological Corp.)

Inconvenience and cost can be curtailed with the use of a home light unit (ibid). Home NB-UVB phototherapy can be as effective as office-based phototherapy, while increasing patient satisfaction with treatment (ibid). Potential side effects and their incidences do not differ significantly between home UVB phototherapy and outpatient pho-

totherapy, provided that the patient has a good understanding of the procedure.

Less conventional methods of sun exposure, such as tanning bed use, have often been recommended for patients for whom office and/or home phototherapy is not feasible (Radack *et al*, 2015). Many tanning facilities are easily accessible and relatively affordable. Tanning beds emit UVA radiation primarily, although the relative amounts of UVA and UVB light are variable for different types of tanning bed bulbs (ibid). Nevertheless, there is sufficient evidence to indicate that this alternative therapeutic option is efficacious (ibid).

Finally, the role of natural sun exposure should not be unappreciated. While the levels of UV exposure from the sun vary with latitude, altitude, weather, time of day, and season, the benefits of natural UV exposure has been historically recognized and sunlight remains a feasible therapeutic option for patients that cannot complete traditional phototherapy.

Conclusions

The practice of phototherapy dates back to ancient history. In the past century, there have been great advances in delivering targeted therapy in specific wavelengths that have dramatically changed the management of many cutaneous inflammatory dermatoses. Despite the introduction of potent biological agents for the treatment of difficult-to-manage diseases, the cost-effectiveness, ease, and the relatively safe side-effect profile of phototherapy makes it a



Figure 3 Hand-held phototherapy device (reprinted with permission from Solarc Systems)

preferred treatment modality for many diseases. Phototherapy will likely remain an important component of dermatology for years to come.

Author contributions

Dr. Vangipuram drafted the outline, conducted a literature review, and authored the paper. Dr. Feldman provided critical revisions to the outline and manuscript.

References

- Anderson KL (2015). A guide to prescribing home phototherapy for patients with psoriasis: the appropriate patient, the type of unit, the treatment regimen, and the potential obstacles. *J Am Acad Dermatol* **72**: 868–878.
- Baron ED, Suggs AK (2014). Introduction to photobiology. *Dermatol Clin* **32**: 255–266, vii.
- Bolognia J, Jorizzo J, Schaffer J (2012). *Ultraviolet therapy*, 3rd edn, Vol 2. Elsevier: New York, NY.
- Boztepe G, Sahin S, Ayhan M, Erkin G, Kilemen F (2005). Narrowband ultraviolet B phototherapy to clear and maintain clearance in patients with mycosis fungoides. *J Am Acad Dermatol* **53**: 242–246.
- Bulat V, Situm M, Dediol I *et al* (2011). The mechanisms of action of phototherapy in the treatment of the most common dermatoses. *Coll Antropol* **35**: 147–151.
- Dogra S, Mahajan R (2015). Phototherapy for atopic dermatitis. *Indian J Dermatol Venereol Leprol* **81**: 10–15.
- Dothard EH, Sandoval LF, Yentzer BA, Feldman SR (2014). Home ultraviolet light therapy for psoriasis: why patients choose other options. *Dermatol Online J* **21**: 13.
- Eichenfield L, Tom W, Chamlin S *et al* (2014a). Guidelines of care for the management of atopic dermatitis: section 1. Diagnosis and assessment of atopic dermatitis. *J Am Acad Dermatol* **70**: 338–351.
- Eichenfield LF, Tom WL, Berger TG *et al* (2014b). Guidelines of care for the management of atopic dermatitis: section 2. Management and treatment of atopic dermatitis with topical therapies. *J Am Acad Dermatol* **71**: 116–132.
- Gabrielli A (2009). Scleroderma. *N Engl J Med* **360**: 1989–2003.
- Guan ST, Theng C, Chang A (2015). Randomized, parallel group trial comparing home-based phototherapy with institution-based 308 excimer lamp for the treatment of focal vitiligo vulgaris. *J Am Acad Dermatol* **72**: 733–735.
- Juzeniene A, Moan J (2012). Beneficial effects of UV radiation other than via Vitamin D production. *Dermatoendocrinol* **4**: 109–117.
- Lapolla W, Yentzer BA, Bagel J, Halvorson CR, Feldman SR (2011). A review of phototherapy protocols for psoriasis treatment. *J Am Acad Dermatol* **64**: 936–949.
- Mehraban S, Feily A (2014). 308 nm excimer laser in dermatology. *J Lasers Med Sci* **5**: 8–12.
- Moller KI, Kongshoj B, Philipsen PA, Thomsen VO, Wulf HC (2005). How Finsen's light cured lupus vulgaris. *Photodermatol Photoimmunol Photomed* **21**: 118–124.
- Patrizi A, Savoia F, Giacomini F, Tabanelli M, Gurioli C (2009). The effect of summer holidays and sun exposure on atopic dermatitis. *G Ital Dermatol Venereol* **144**: 463–466.
- Picciani BL, Souza TT, Santos VT *et al* (2015). Geographic tongue and fissured tongue in 348 patients with psoriasis: correlation with disease severity. *Cutis* **49**: 1–7.
- Radack KP, Farhangian ME, Anderson KL, Feldman SR (2015). A review of the use of tanning beds as a dermatological treatment. *Dermatol Ther* **5**: 37–51.
- Rajpara AN, O'Neill JL, Nolan BV, Yentzer BA, Feldman SR (2010). Review of home phototherapy. *Dermatol Online J* **16**: 2.
- Shenoi S, Prabhu S (2014). Photochemotherapy (PUVA) in psoriasis and vitiligo. *Indian J Dermatol Venereol Leprol* **80**: 497–504.
- Speeckaert R, van Geel N (2014). Distribution patterns in generalized vitiligo. *J Eur Acad Dermatol Venereol* **28**: 755–762.
- Totonchy M, Chiu M (2014). UV based therapy. *Dermatol Clin* **32**: 399–413.
- Trautinger F (2011). Phototherapy of mycosis fungoides. *Photodermatol Photoimmunol Photomed* **27**: 68–74.
- Walker D, Jacobe H (2011). Phototherapy in the age of biologics. *Semin Cutan Med Surg* **30**: 190–198.
- van Weelden H, De La Faille HB, Young E, van der Leun JC (1998). A new development in UVB phototherapy of psoriasis. *Br J Dermatol* **119**: 11–19.
- Weichenthal M, Schwarz T (2005). Phototherapy: how does UV work? *Photodermatol Photoimmunol Photomed* **25**: 260–266.
- Zandi S, Kalia S, Lui H (2012). UVA1 phototherapy: a concise and practical review. *Skin Therapy Lett* **17**: 1–4.