

Cryptorchidism: diagnostic performance of Magnetic Resonance Imaging in comparison with Ultrasound

⁽¹⁾Muna A.G , ⁽²⁾Najlaa Hanon , ⁽³⁾Riadh H

⁽¹⁾⁽²⁾ Radiologist in Al-Yarmouk Teaching Hospital⁽³⁾ Radiologist in Central Pediatric Hospital

⁽¹⁾⁽²⁾ AL- Mustansiriyah University

Abstract

Background: Undescended testis is a well recognized clinical problem in infants and young male , as well as being a frequent finding in adult individuals .

Aim of work : To compare the results of MRI and ultrasound in the localization of undescended testis , in order to choose the line of treatment .

Method : The study was conducted in two general hospitals in Baghdad between Oct. 2012 --- April 2013. Forty male patients with undescended testis (6 months ---20 years) underwent abdominal and pelvic MRI as well as inguinal and pelvic U/ S to identify testicular location , findings were reviewed by three observers independently and compared with surgical and / or clinical follow up study.

Results : Ultrasound succeeded in localizing 21 cases of undescended testis with sensitivity 83.3 % specificity 100% and accuracy 90 % . On the other hand MRI was able to demonstrate 24 cases with sensitivity 96%, specificity 100% and accuracy 97.5 % .

Conclusion: Magnetic Resonance Imaging is a useful imaging tool in the localization and tissue characterization of a undescended testis , especially with the use of i.v contrast injection which is helpful in suspected cases of testicular atrophy and cases of abdominal and pelvic testis , however, ultrasound must be the first line of imaging investigation as it is readily available and fast, but highly operator dependent .

Key words: Undescended testis, ultrasound, MRI.

Introduction

Undescended testis is one of the most common congenital genitourinary disorder in boys with a prevalence of 1% to 3% in term, 20 % of which are non-palpable. It is a major clinical problem in infants and young male individuals^(1,2). As long term retention of undescended testis is associated with dramatically increase risk of testicular neoplasm, especially seminoma, in addition to alteration of male fertility. It has an incidence of 2.7 –6 % at full term and 0.8 % at one year of age⁽³⁾. An undescended testicle may be intra-canalicular, intra -abdominal, ectopic or congenitally absent, it possesses a high risk of malignancy and impaired spermatogenic function, therefore an adequate pre- operative assessment and localization of the non- descended testis is imperative for further surgical and clinical management of patients^(4,5,6,7).

Method

The study was conducted in two General hospitals in Baghdad,, in the radiology department, between Feb. 2012 through April 2013. Forty patients (selected as 20 unilateral and 20 bilateral undescended testis) underwent U/ S and MRI examination. There ages range between 6 months and 20 yrs .They were followed up by laparoscopy, open surgical procedure or clinical follow up. The decision for imaging study (U/S and/or MRI) was based on the clinical judgment of the referring primary care physician, pediatrician or urologist.. referring cases of" undescended" or " non-

palpable" testis, some boys had an U/S study, arranged recently, but none had an MRI study.

Imaging studies were held as follows:

- Scrotal U/S : using the linear probe 7.5 MHZ probe LOGIQ P5 machine. patient being in the supine position including the scrotum, inguinal canal and adjacent lower pelvic cavity.
- Abdominal U/S :attempts to search for possible abdominally located testis, using the 5 or 3.5 MHZ sector probe.
- The MRI scan studies were performed on 1.5 Tesla superconducting magnet, MAGNETOM (Siemens, Germany), using a body coil, with the examination applied pelvi-abdominally, involving the scrotum. Scans obtained were:
 - a. Pre- contrast axial... T1 and T2.
 - b. Pre- contrast Coronal ...T2 ,fat suppression T2 turbo -spine echo and fat suppression T1.
 - c. Post- contrast coronal.. T1 after i.v contrast gadolinium injection.
 - d. Sedation with oral chloral hydrate or i.v ketamin hamelen 50mg/ml in a dose of 1-2 mg/kg were used for children below 5 years to achieve adequate immobilization.

We included 18 patient with I.V gadolinium injection to improve

Cryptorchidism: diagnostic performance of Magnetic Resonance Imaging in comparison with Ultrasound

visualization of ectopic testis ,especially in the association of testicular atrophy.

Statistical analysis included the sensitivity , specificity and accuracy .

A comparison study was done with similar English-language articles , identified by searching pub med, Medline and Embase.

Results

Forty patients included in the study of undescended testis , with age ranging between 6 months and 20 years .. there is an insignificant relationship between the age and un descended testis , however, we reported only two patients above 18 years .

Ultrasound succeeded in localizing 21 testes, 10 bilateral and 11 unilateral testes (6 Lt. and 5 Rt. Sided) , the ectopic testes were seen in the inguinal canal , With sensitivity 83.3 % specificity 100 % and accuracy 90%. Magnetic resonance imaging revealed 24 ectopic testes , 12 bilateral and 12 unilateral (7 Lt. and 5 Rt.) . On MRI ,the ectopic testes were seen in the inguinal (No.= 20) and intra abdominal (No.= 4) locations. Six small testes were detected on MRI

confirmed on surgery , of these 4 retaining their characteristic signal intensity pattern (hyper- intense to fat on T1 and hypo- intense or iso- intense to fat on T2 weighted sequences) , the remaining 2 showing elements of fibrosis (mild hypo- intensity to fat on T2 images) , these were identified on inguinal exploration, secondary to spermatic cord torsion. In the coronal MRI images , all inguinal testes were located along the course of the spermatic canal which exhibit a low intensity signal line extending from the inguinal canal to the base of the scrotum . Eight cases of bilateral non-descended testis ,were congenitally absent, of these , three presenting with ambiguous genitalia and inter-sex presentation , two patients with congenital adrenal hyperplasia , in the remaining three patients, MRI showed no testis . False positive MRI study seen in 1 case of intra-canalicular atrophic lymph node confirmed on exploration , on retrospective evaluation of MRI study, hypo intensity to fat on T2 study depicting underlying fibrotic changes ,there was no false negative findings.. in addition, none of our patients exhibit imaging features of malignant degeneration of the criptorctized testis . in our study, Imaging with MRI was 96% sensitive , 100% specific and 97.5 % accurate .

Cryptorchidism: diagnostic performance of Magnetic Resonance Imaging in comparison with Ultrasound

Table 1. Distribution of study sample according to clinical findings.

Clinical finding	U/S +ve	U/S -ve	MRI +ve	MRI -ve	Surgery +ve	Surgery -ve
20 bilateral	10	10	12	8	12	8
12 Left	6	6	7	5	7	5
8 Right	5	3	5	3	6	2
Total	21	19	24	16	25	15

Table- 2- Distribution of U/S and M.R.I. in bilateral undescended testis

Bilateral	Gold standard		Sensitivity	Specificity	PPV	NPV	Accuracy
	Positive	Negative					
US Positive	10	0	83.3	100	100	80	90
US Negative	2	8					
MRI Positive	12	0	100	100	100	100	100
MRI Negative	0	8					

Cryptorchidism: diagnostic performance of Magnetic Resonance Imaging in comparison with Ultrasound

Table 3 ..Distribution list of LT un descended testis on U/S and MRI

Left	Gold standard Diagnosis		Sensiti -vity	Specifi -city	PPV	NPV	Accuracy
	Positive	Negative					
US Positive	6	0	85.7	100	100	83.3	91.7
US Negative	1	5					
MRI Positive	7	0	100	100	100	100	100
MRI Negative	0	5					

Table -4 - Showing distribution list of Rt. sided un descended testis.

Right	Gold standard Diagnosis		Sensit -vity	Specif -icity	PPV	NPV	Accuracy
	Positive	Negative					
US Positive	5	0	83.3	100	100	66.7	87.5
US Negative	1	2					
MRI Positive	5	0	83.3	100	100	66.7	87.5
MRI Negative	1	2					

Cryptorchidism: diagnostic performance of Magnetic Resonance Imaging in comparison with Ultrasound

Table .5 distribution list of accuracy

Total patients	Gold standard		Sensitivity	Specificity	PPV	NPV	Accuracy
	Positive	Negative					
US Positive	21	0	83.3	100	100	78.9	90
US Negative	4	15					
MRI Positive	24	0	96	100	100	37.5	97.5
MRI Negative	1	15					

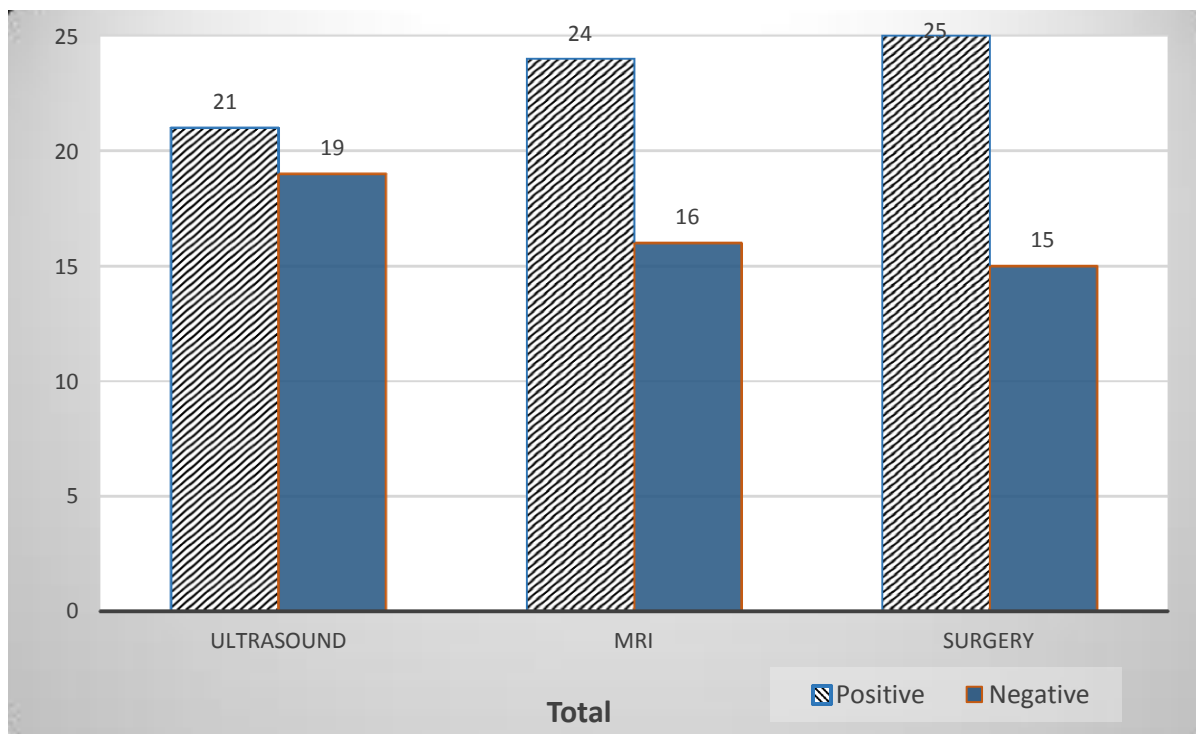


Fig-1- Total sample study correlated with surgery.

Cryptorchidism: diagnostic performance of Magnetic Resonance Imaging in comparison with Ultrasound

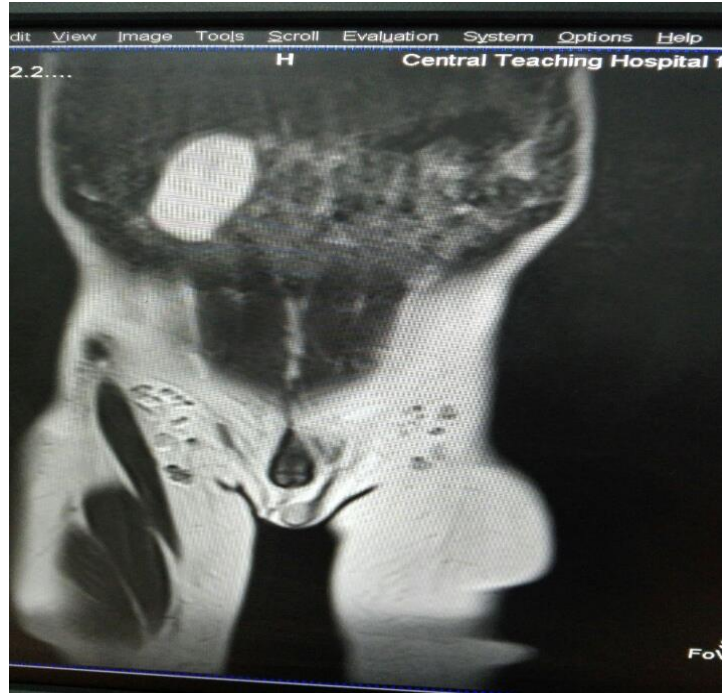

Fig - 2. Sagittal T 2 W image, Rt. sided un descended testis.

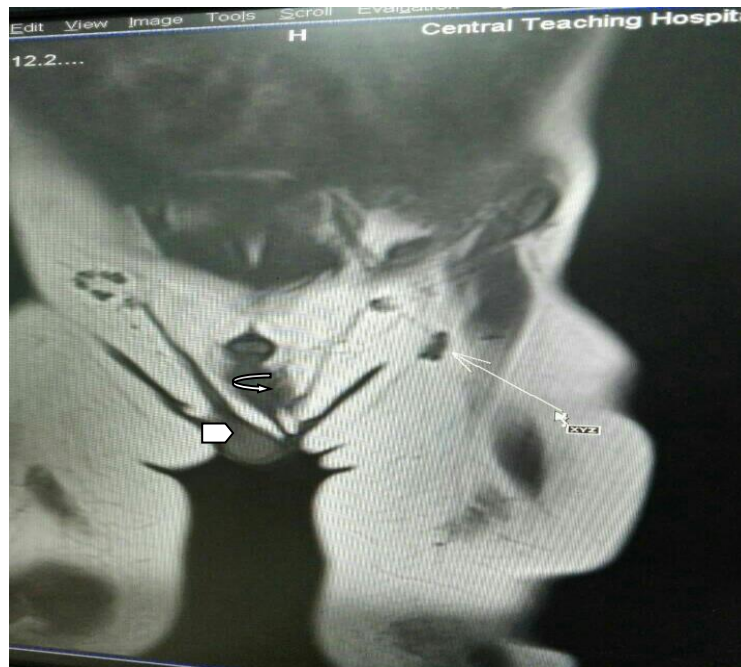


Figure -3. left sided undescended testis with upper thigh necrotic lymph node (long arrow) , Lt inguinal necrotic lymph node (curved arrow) confirmed by surgery and hypo plastic Lt inguinal canal

Discussion

The goal of management in a boy with undescended testis is to place the testis in the scrotum when possible. This gives it the best chance to function in an endocrine capacity, contribute towards fertility and help early detection in case of malignancy⁽⁶⁾.

The undescended testis is more prone to malignant changes and they lose reproductive function in adult. Intra-abdominal testes have greater predilection for malignant changes as compared to inguinal ones⁽⁴⁾. Early orchiopexy between one and two of age, has been advocated for preservation of fertility^(7,8).

In the radiological evaluation of undescended testis, U/S is reliable in being non-invasive, painless, it poses no significant biological effect and readily available screening method⁽⁹⁾. For these reasons, sonography is considered the best tool for initial testing.. in which we agree with the study stated by Gupta et al⁽¹⁰⁾. scrotal U/S correctly identified 84% of cases, in other work study, the sensitivity for scrotal U/S detection was 95 % and 91 % respectively^(11,12).

Magnetic resonance imaging is more sensitive than U/S, as the latter is not reliable in localizing non palpable testis or rule out an intra-abdominal location. While MRI is capable of producing multi-planner images and has the potential for tissue characterization. It is also useful in limiting the area of surgical exploration. Like scrotal testes, undescended testis are hypo-intense to fat on T1

weighted images and hyper-intense or iso-intense to fat on T2 weighted images. Magnetic resonance imaging is more sensitive in the localization of high testes, especially the intra-abdominal testis located near or at the inguinal ring, which is suggested with an absent or empty spermatic cord... were testicular tissue is not revealed anywhere along the path of descent⁽⁴⁾. The most common location of crypt orchid testis is in the inguinal canal 72%^(12,15). In our study, we have comparable findings.. with the inguinal canal showing about 82 % location of ectopic testis, in another work study, the ectopic testes were located in the inguinal canal in 65 %⁽¹³⁾. In K.Kanemoto et al, which show two testes in the abdominal cavity out of 47 testes and 19 testes were not seen at all 40 %.. as well as 19 patients 40 % seen in the inguinal canal⁽¹⁴⁾. In the evaluation by MRI of ectopic testis, R.P.Tripathi et al⁽⁴⁾ showed 6 abdominal testis, out of thirty two patients, in our series these were 4 intra-abdominal testis out of 12 patients.. About 33 %.. With 8 cases of bilateral non descended testis seen neither in the abdominal nor pelvic cavity, in these cases, endocrine tests may be helpful. The differences in data.. possibly related to the different disease prevalence in societies, with different volume of sample study being included. Other causes related to the referring physician, many primary care centers order a sonogram before referring the child for surgical exploration and not infrequently a testis that is not palpable by the referring physician can be palpated by a pediatric urologist.

Cryptorchidism: diagnostic performance of Magnetic Resonance Imaging in comparison with Ultrasound

In the current work , MRI failed to detect an inguinal, atrophic lymph node ,confirmed after surgical exploration (false positive) ,sensitivity 97 % but in other work studies ,MRI was 100% sensitive ^(1, 4) may be related to the different imaging protocols used .

Conclusion

We recommend U/S as an initial step to start with, for localization of undescended testis because of its readily available , quick and non- hazardous, MRI is a complimentary study , and more accurate non- invasive tool for tissue characterization, especially in cases of high, intra-abdominal or atrophic testis .

References

1. Adel A Shehata , Osama A Zakeria . MRI versus ultra sound in the localization of undescended testicles. Suez Canal Univ. Med J vol.6, No.1, October,2003.
2. Mona NA, Ahmed BF. Ultrasound versus MRI in localization of undescended Testes. Radiology 1999.
3. Mattrey R. Trambert M. MRI imaging of the scrotum and Testis. In; clinical Resonance Imaging. Eds. Edelman RR, Hesselink TR. Philadelphia, WB Saunders Co,1991, pp972—978.
4. R.P. Tripathi , A.N. Jena, P. Gulati *et al* . Undescended testis: Evaluation by Magnetic Resonance Imaging. Indian pediatrics.net/april 1992/433—438.
5. Encyclopedia of medical imaging (net), (2003)vol. 2.4 Fritzsche P.J.,Haricak H., Kogan B.A.,Winkler M.L., & Tanagho E.A.; undescended testis: Value of MRI imaging,(1987),radiology,vol.164, 169-173.
6. S.Elder, MD Jack, *et al* . Ultrasound is unnecessary in evaluating Boys with Nonpalpable testis. Ped. J of American Academy ; Pediatrics 2002;110;748.
7. Gregory E. Tasian and Hillary L. Copp.Diagnostic performance of Ultrasound in Nonpalpable Cryptorchidism: A Systemic Review and Meta-analysis.Ped. I of American Academy; Pediatrics 2011; Jan. 127 (1): 119-128.
8. Amar S . and Anirudh S.,Impalpable testis is imaging really helpful? Indian pediatrics.net/ Aug. 2006 , 43:720---723.
9. Kazuhiro K.,Yutaro H., Yoshiyuki K, *et al* . Accuracy of ultrasonography and magnetic resonance imaging in the diagnosis of non-palpable testis. International J.of radiology. 2005.vol. 12 ,issue7 p.668—672.
10. Teerasak P., Atchara M., Panruethai T. Accuracy of Ultrasound in pediatric undescended testes. Asian Biomedicine. Vol. 4 no. 6 Dec. 2010; 983—986.
11. Cain MP, Garra B, Gibbons MD. Scrotal –inguinal ultrasonography: a technique for Identifying the Nonpalpable inguinal testis without laparoscopy. JUrol . 1996 Aug.: 156 (2pt 2):791-4.
12. Mohammad H., Amir H., Hojjat P., Assessment of Diagnostic value sonography for cryptorchidism Journal of diagnostic medical sonography: Daghigh.HB Business.2006.

Cryptorchidism: diagnostic performance of Magnetic Resonance Imaging in comparison with Ultrasound

13. Tariq O. , Noora A., Ahmed H., *et al* . Pre-operative Assessment of Impalpable Testes: A single Experience. ISRN Urol. Vol. (2) 2012 ID 560216 3 pages.
14. K. Kenimoto , Y. kojima , Y. Hayashi *et al* : The Management of Nonpalpable testis with combined groin exploration and subsequent trans inguinal laparoscopy . J Urol. 2002; 167 (2 pt 1) : 674-6.
15. Kamiqaito T, nishizawa S., Nakayama T. *et al* : Pre-operative Magnetic Resonance Imaging in the Management of the non-palpable testis. PubMed. gov. US national library of Medicine 2008; 54 (2) :107—9.