

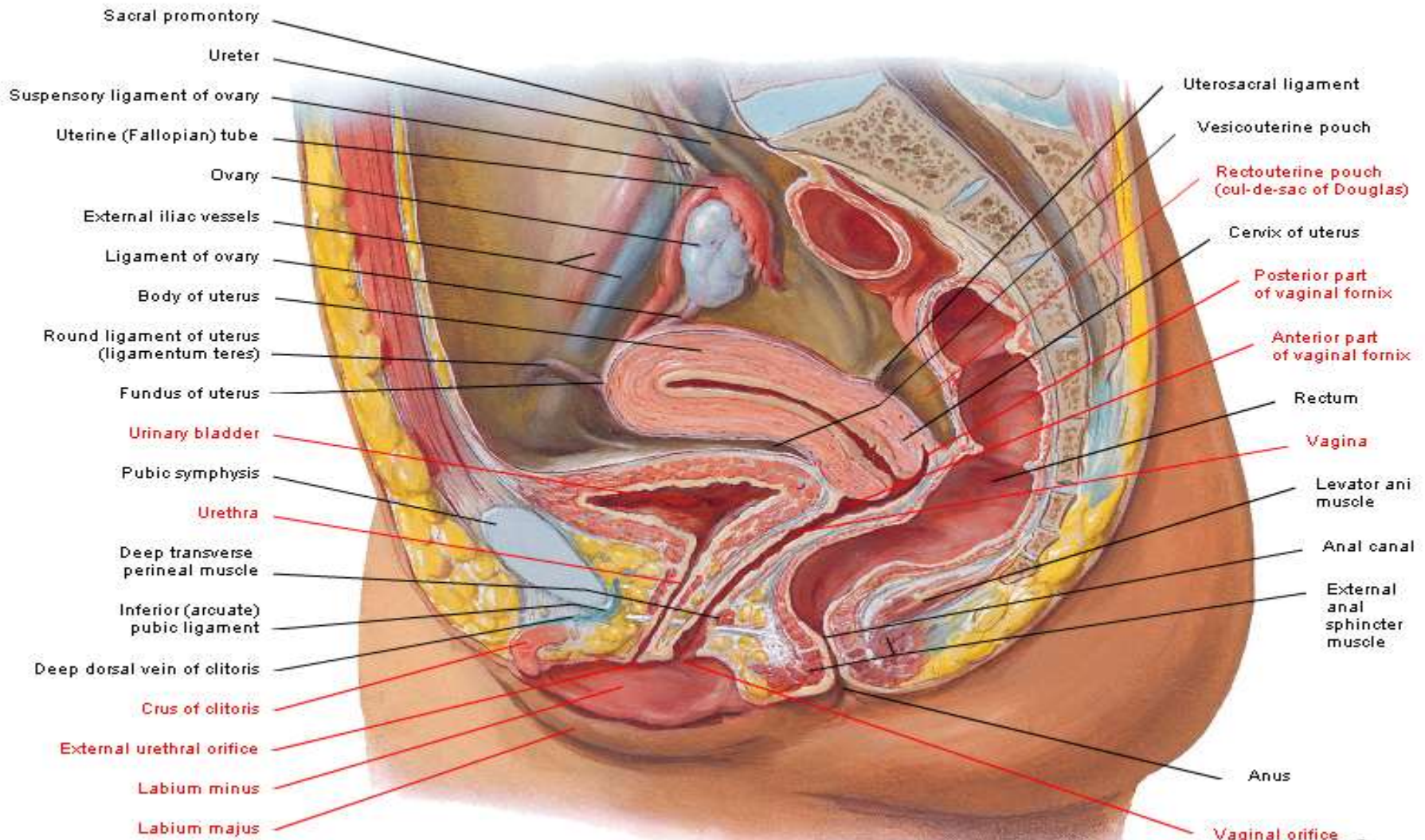
ANATOMY LAB

FEMALE REPRODUCTIVE SYSTEM

PRE-LAB 2

Pelvic Viscera and Perineum of Female

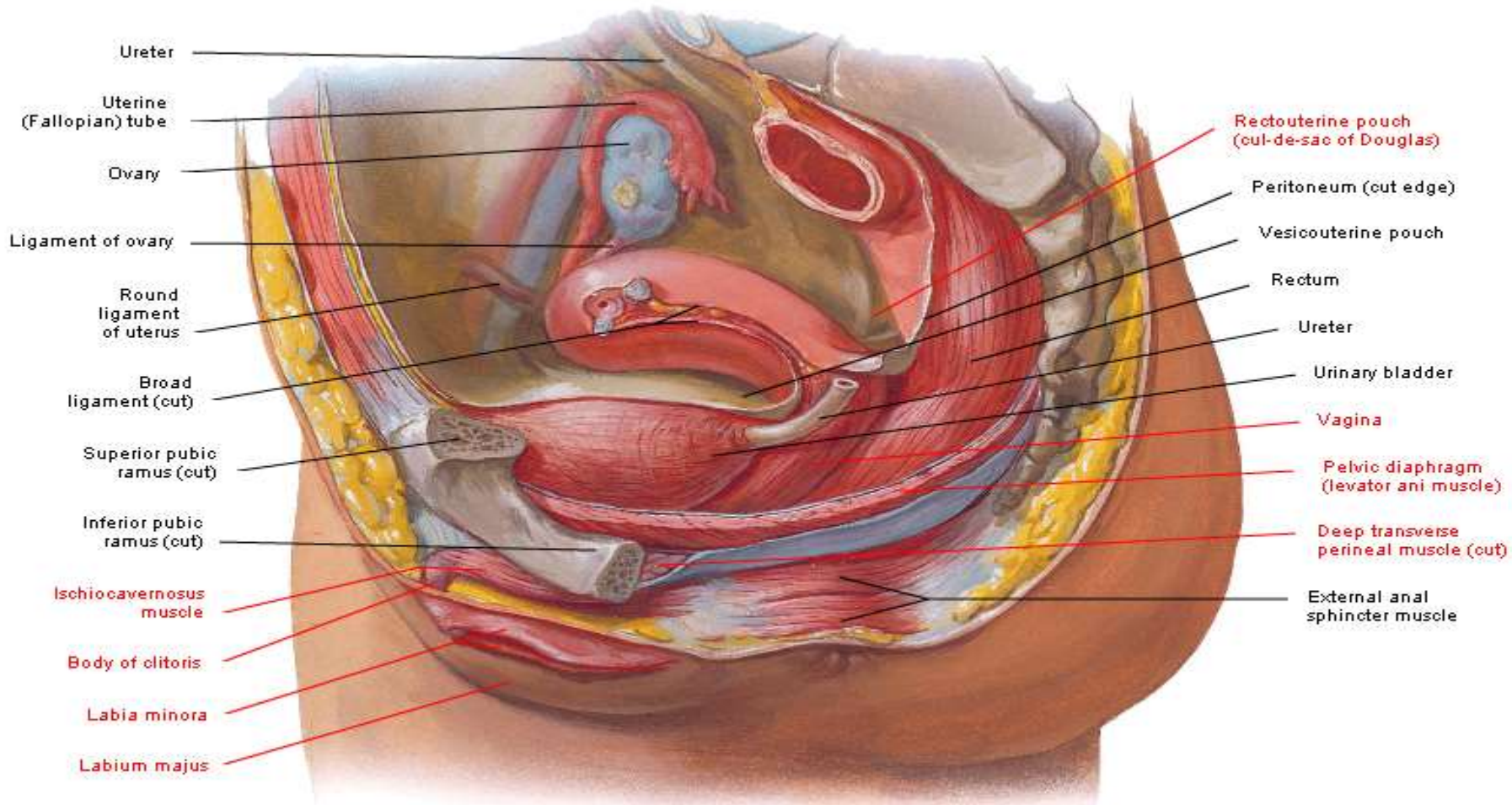
Median (Sagittal) Section



F. Netter M.D.
C. Machado M.D.

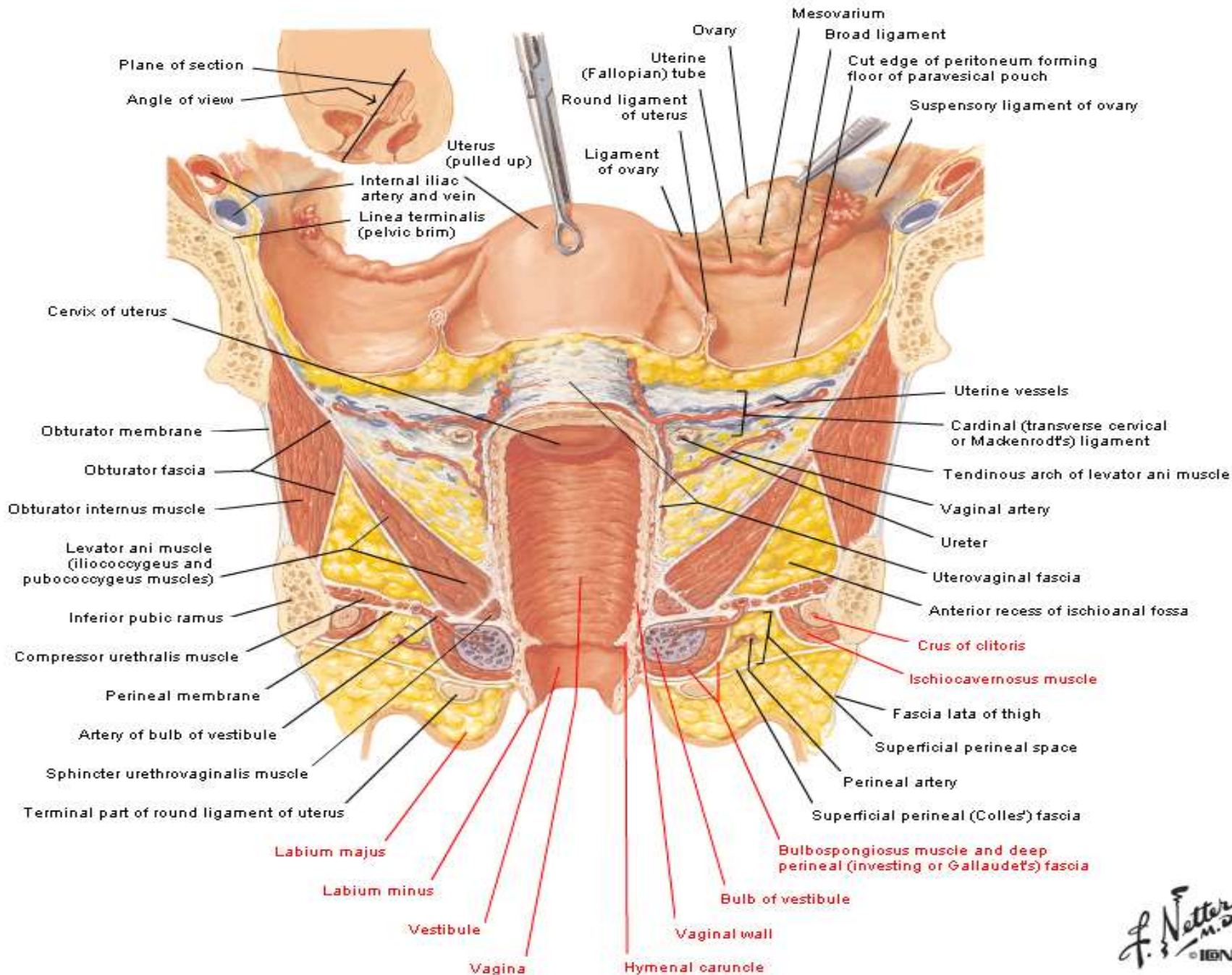
Pelvic Viscera and Perineum of Female

Paramedian Sagittal Dissection



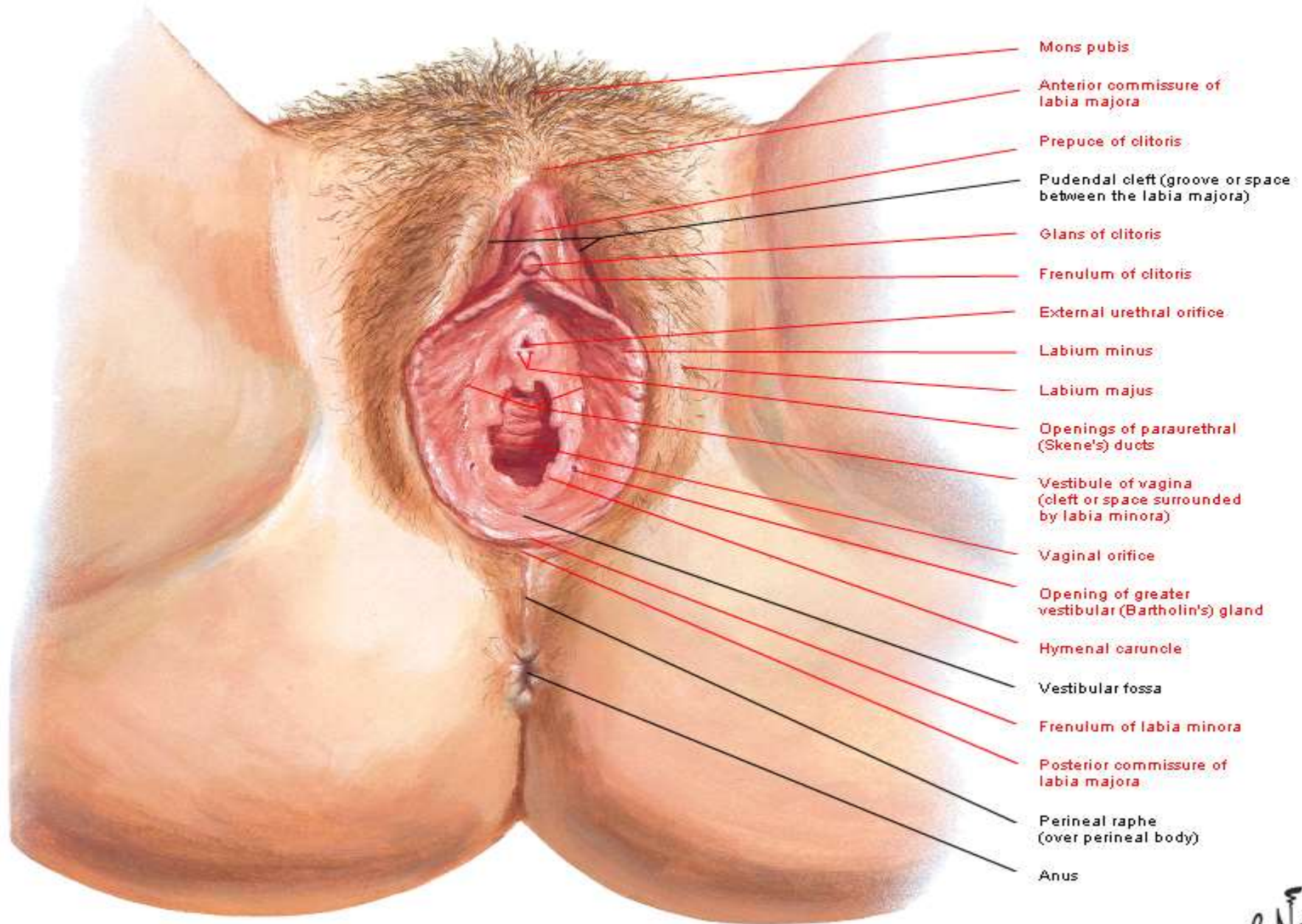
F. Netter
M.D.
C. Machado
M.D.

Uterus, Vagina and Supporting Structures



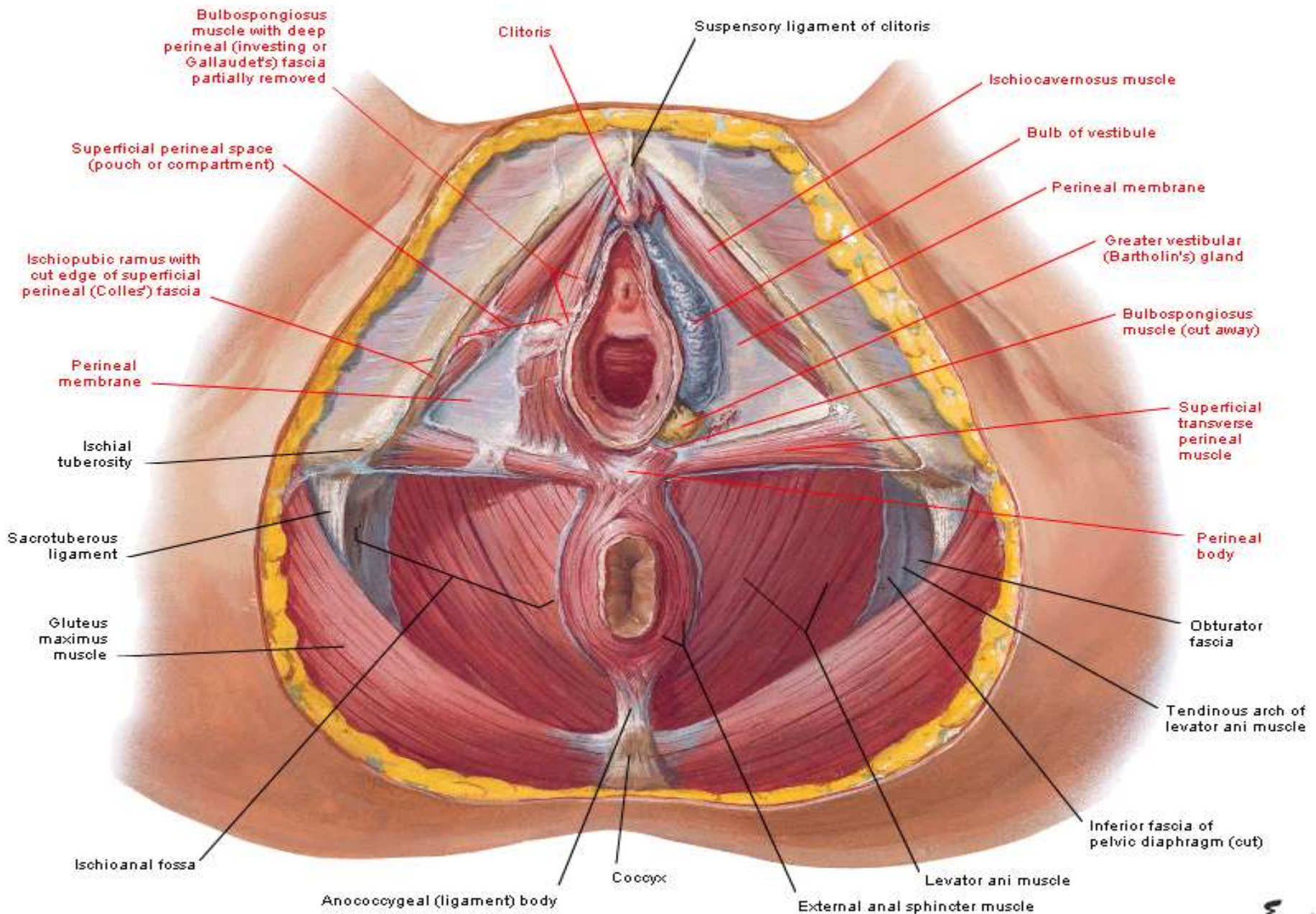
Perineum and External Genitalia of Female

Vulva or Pudendum



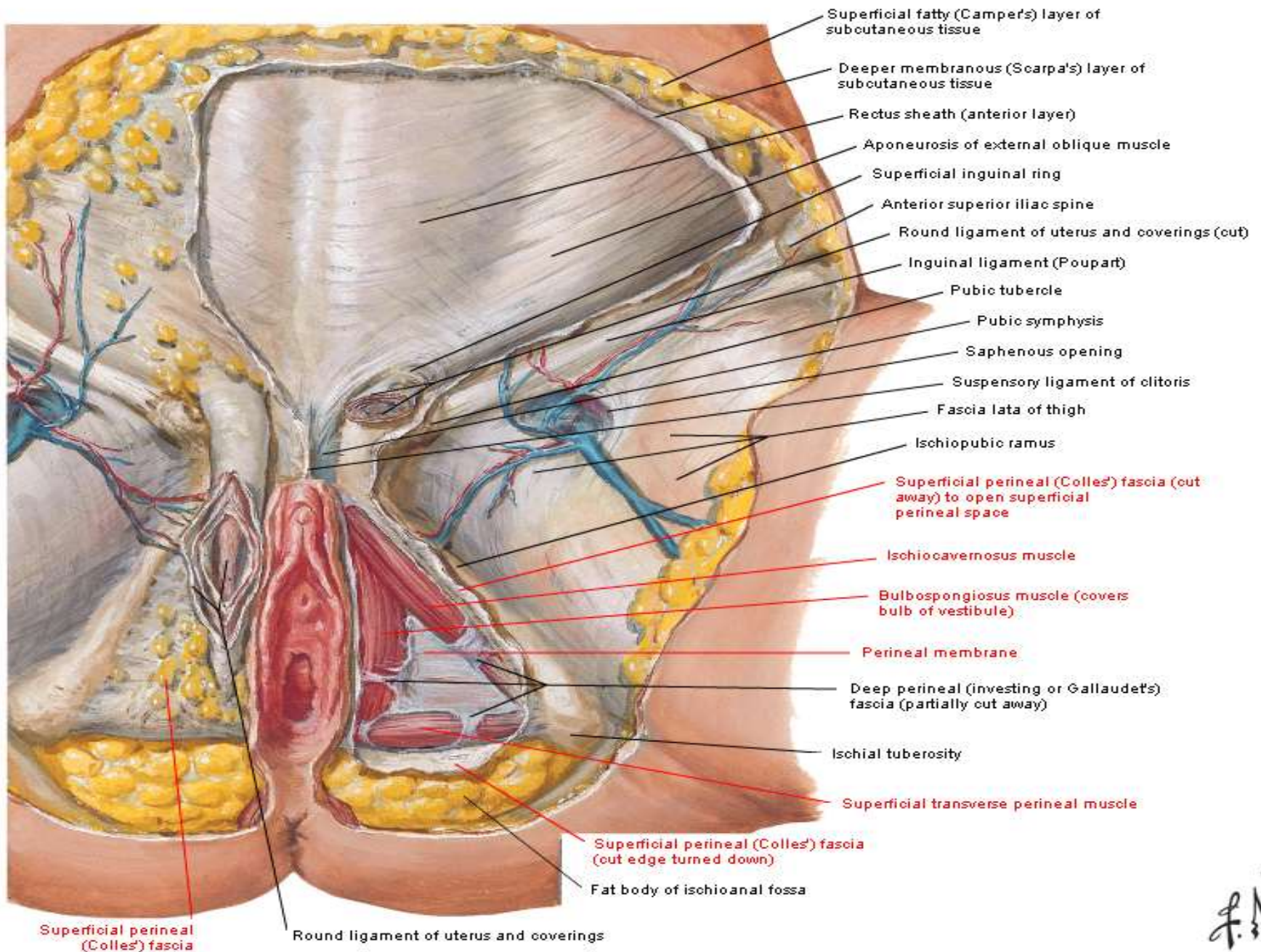
- Mons pubis
- Anterior commissure of labia majora
- Prepuce of clitoris
- Pudendal cleft (groove or space between the labia majora)
- Glans of clitoris
- Frenulum of clitoris
- External urethral orifice
- Labium minus
- Labium majus
- Openings of paraurethral (Skene's) ducts
- Vestibule of vagina (cleft or space surrounded by labia minora)
- Vaginal orifice
- Opening of greater vestibular (Bartholin's) gland
- Hymenal caruncle
- Vestibular fossa
- Frenulum of labia minora
- Posterior commissure of labia majora
- Perineal raphe (over perineal body)
- Anus

Superficial Perineum of Female



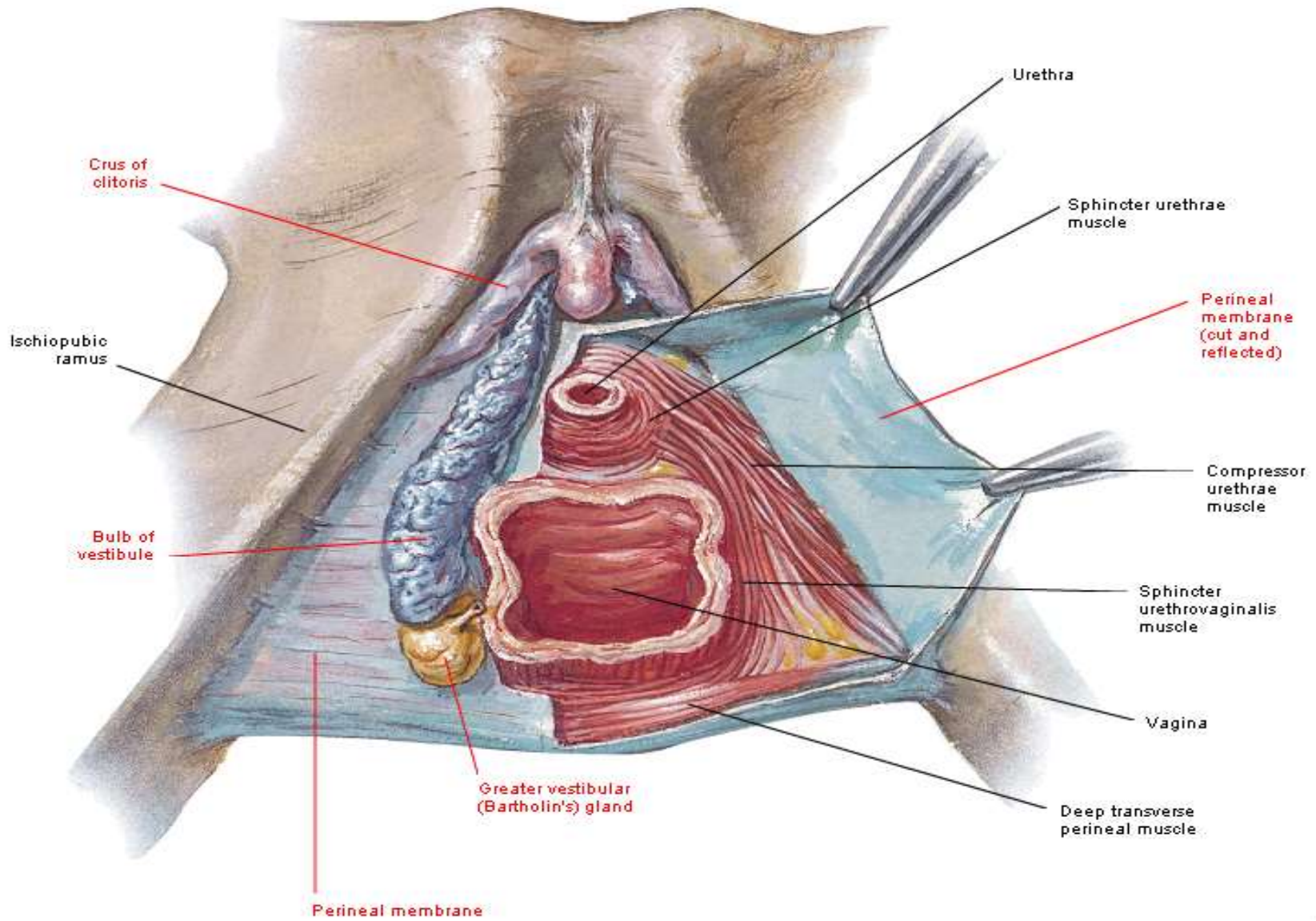
Perineum of Female

Superficial Dissection



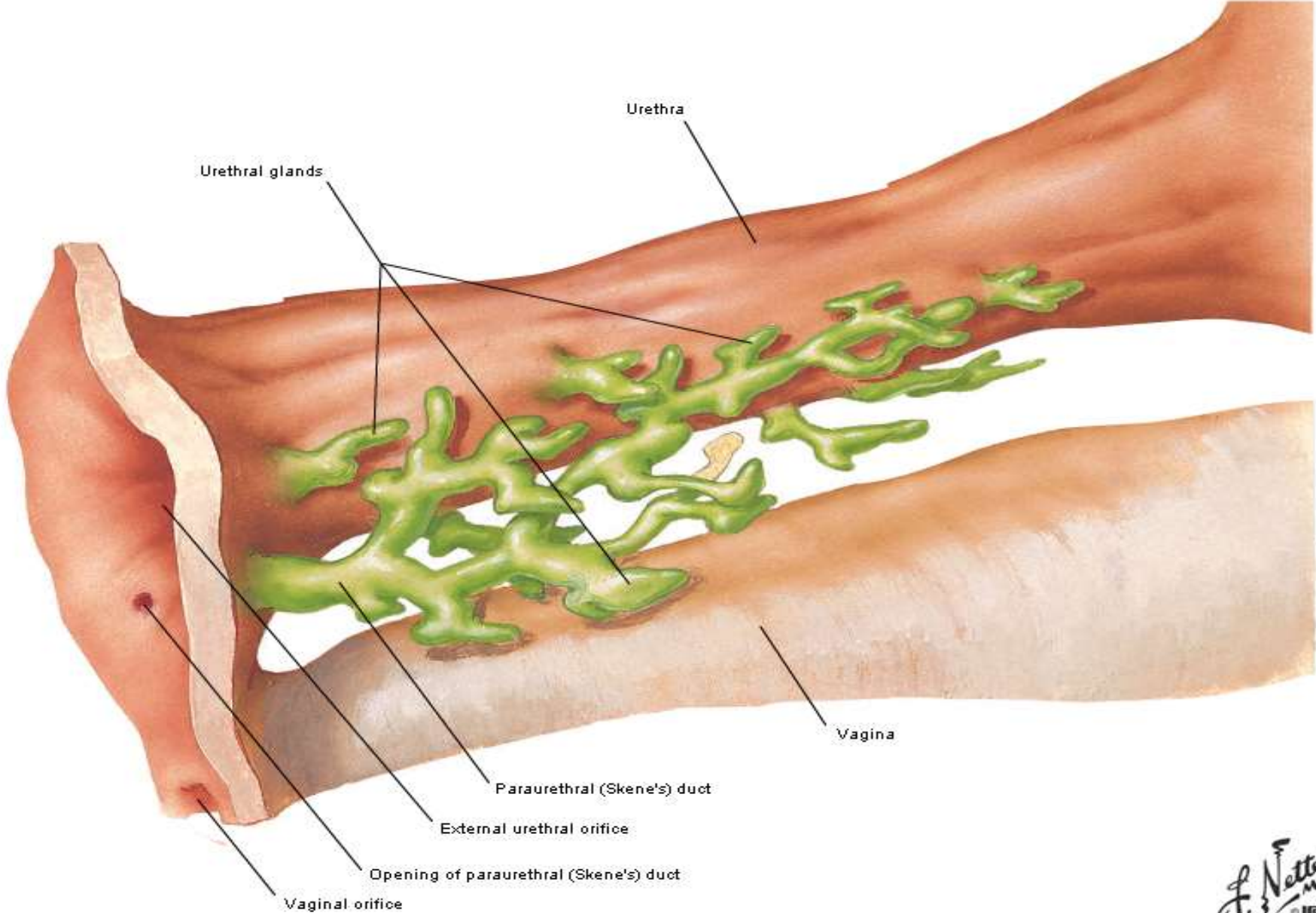
Perineum of Female

Deep Dissection



Urethra of Female

Schematic Reconstruction



Lymph Vessels and Nodes of Perineum Female

